

# Sarcoid-Like Reaction to Disseminated Pulmonary Cryptococcosis in an Immunocompromised Vaper

✉ Susanna E. Sogge OMS-4<sup>1</sup>, Marcus J. Kwon OMS-4<sup>1</sup>, Jennifer H. Ra OMS-4<sup>1</sup>, Heong Jin C. Ahn OMS-4<sup>1</sup>, Kunal Patel D.O.<sup>2</sup>, Adrian DiVittorio M.D.<sup>3</sup>

<sup>1</sup>Alabama College of Osteopathic Medicine, Dothan, AL, USA

<sup>2</sup>Orange Park Medical Center, Orange Park, FL, USA

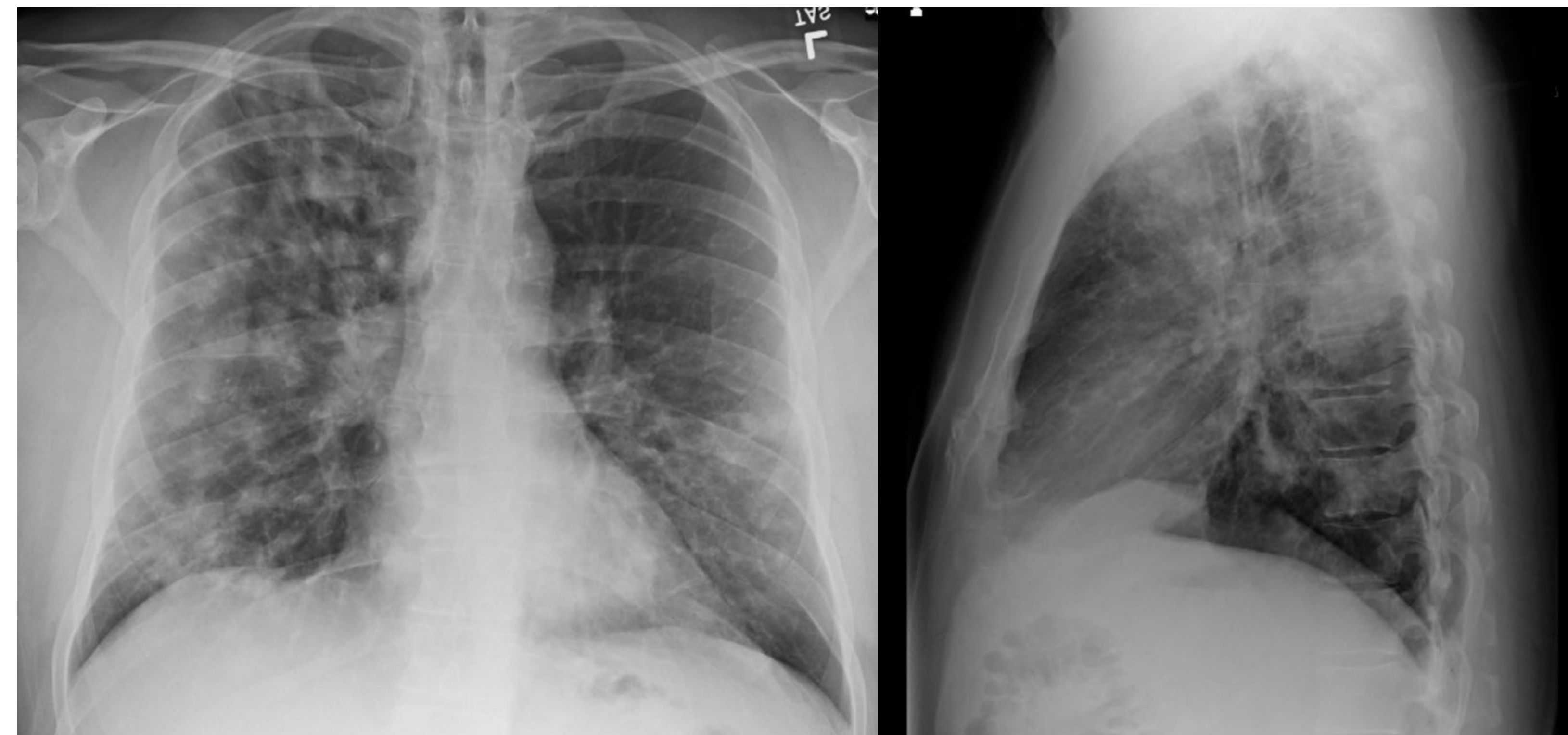<sup>3</sup>Mobile Infirmary, Diagnostic & Medical Clinic, Infirmary Cancer Care Mobile, AL, USA

## BACKGROUND

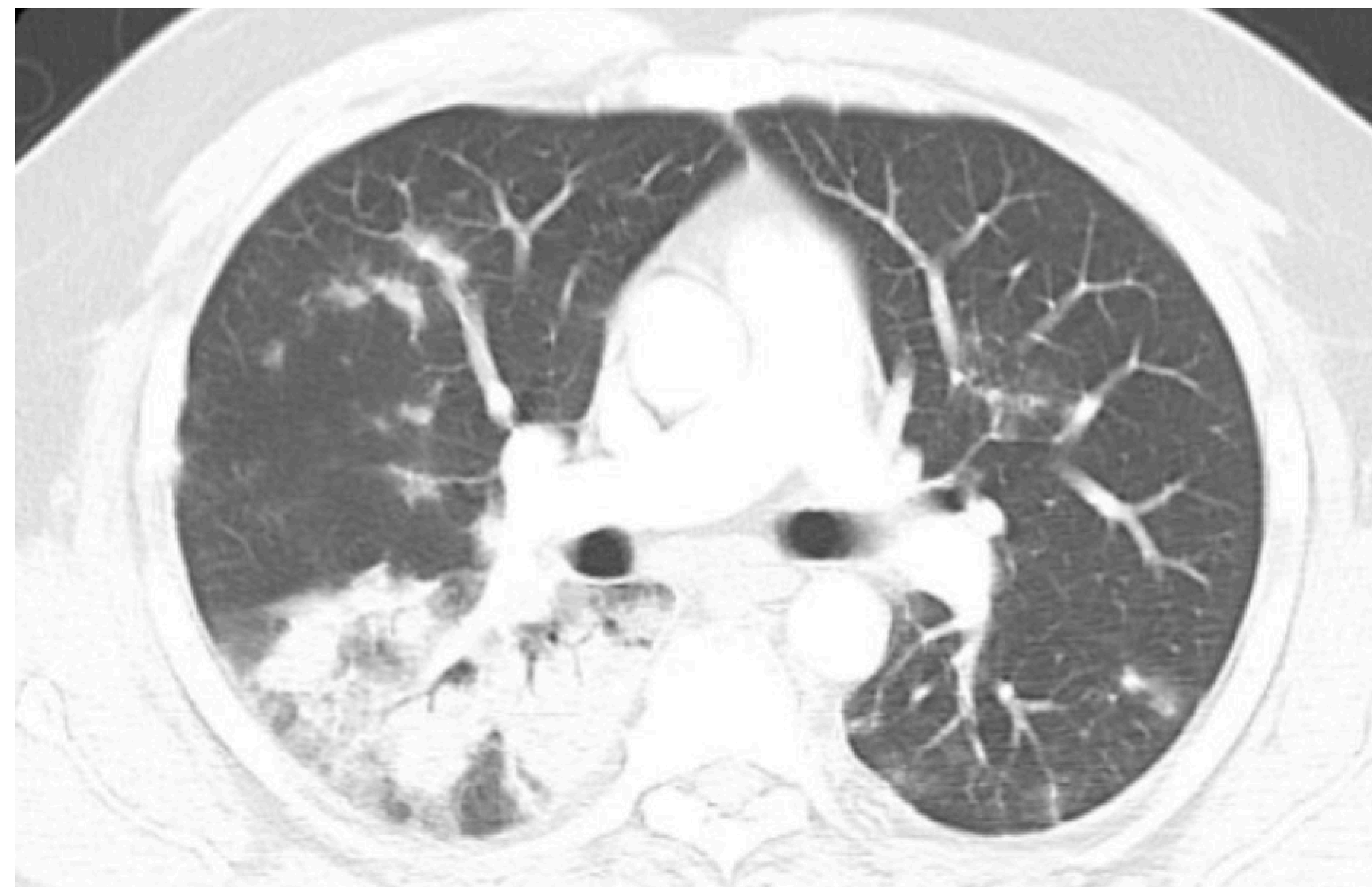
- *Cryptococcus neoformans* is an opportunistic yeast that most commonly presents as a pulmonary infection with rare dissemination in immunocompromised hosts [1, 2, 5].
- Sarcoid-like reactions (SLRs) are typically reported in patients with malignancy, likely secondary to immune response to tumor cells [3].
- E-cigarette or vaping product use-associated lung injury (EVALI) is an ongoing epidemic in the United States causing acute or subacute respiratory illness with unclear etiology [6].
- **To our knowledge, this is only the second reported case of pulmonary cryptococcus causing a SLR.**

## CASE PRESENTATION

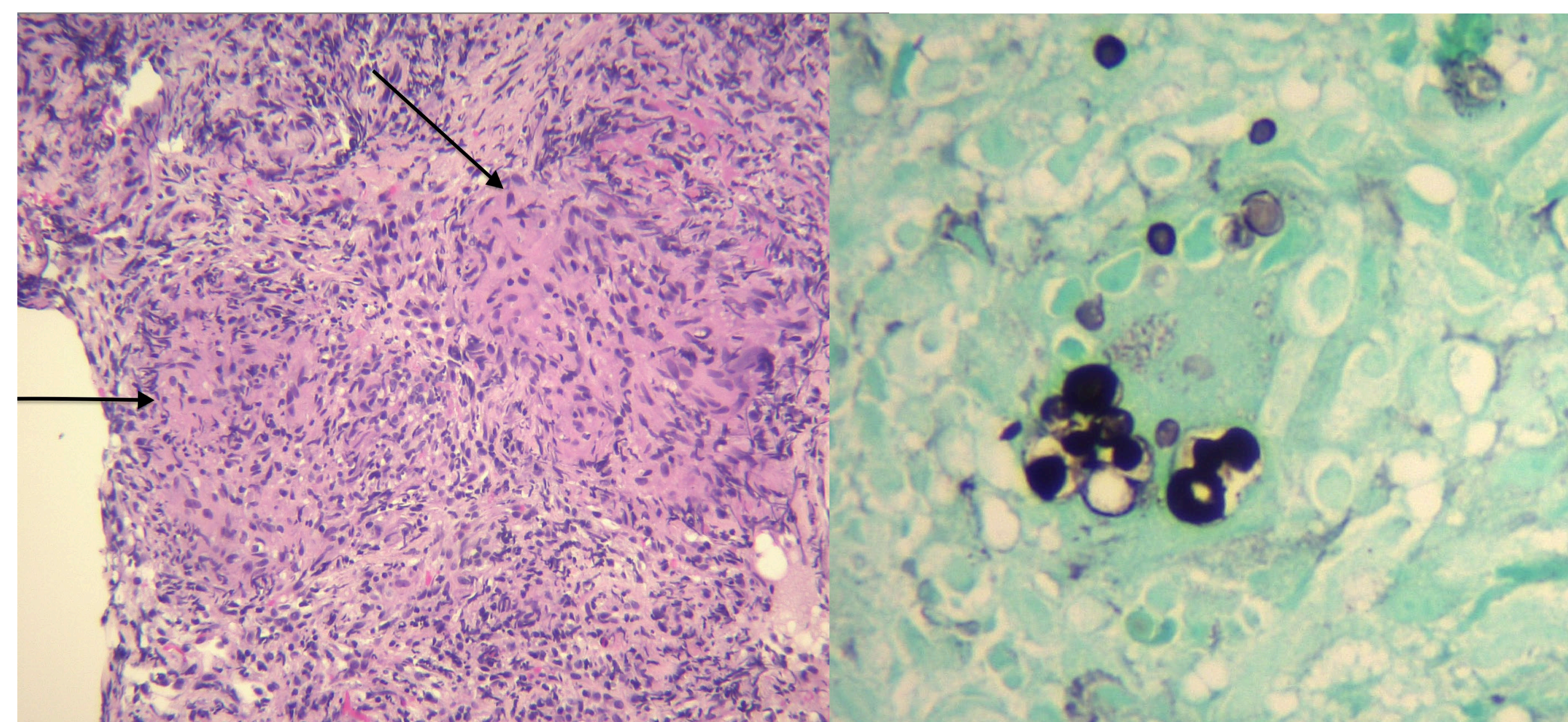
- A 38-year-old male vaper with ulcerative colitis presented to the ED with pleuritic chest pain, dyspnea, and productive cough. Chest imaging (Figure 1, 2) revealed right upper lobe nodular, ground glass infiltrates and right hilar adenopathy.
- He was admitted for community-acquired pneumonia treatment. He developed respiratory distress, prompting bronchoscopy, which visualized tracheobronchial erythema. Wash cytology revealed fungal spores and filamentous bacteria concerning for *Nocardia*, and endobronchial biopsy revealed nonspecific fibrosis. He was transitioned to trimethoprim-sulfamethoxazole and fluconazole, which was discontinued due to uncertain significance of the fungal spores.
- Unfortunately, his dyspnea worsened with declining oxygen saturations. Wash culture grew *C. neoformans*, with serology positive for cryptococcal blood antigen. High-dose fluconazole was started, and he began to improve. Repeat bronchial wash cultures remained positive for cryptococcus, and biopsy revealed noncaseating granulomas with fungal elements (Figure 3, 4).
- Sarcoidosis was ruled out as he did not exhibit hypercalcemia, elevated alkaline phosphatase, hypergammaglobulinemia, or systemic symptoms. Other diagnoses including vasculitis, mycobacterial infection, and primary immunodeficiencies were ruled out.
- He continued to improve, and after a 19-day hospitalization, was discharged with fluconazole and pulmonary follow up.



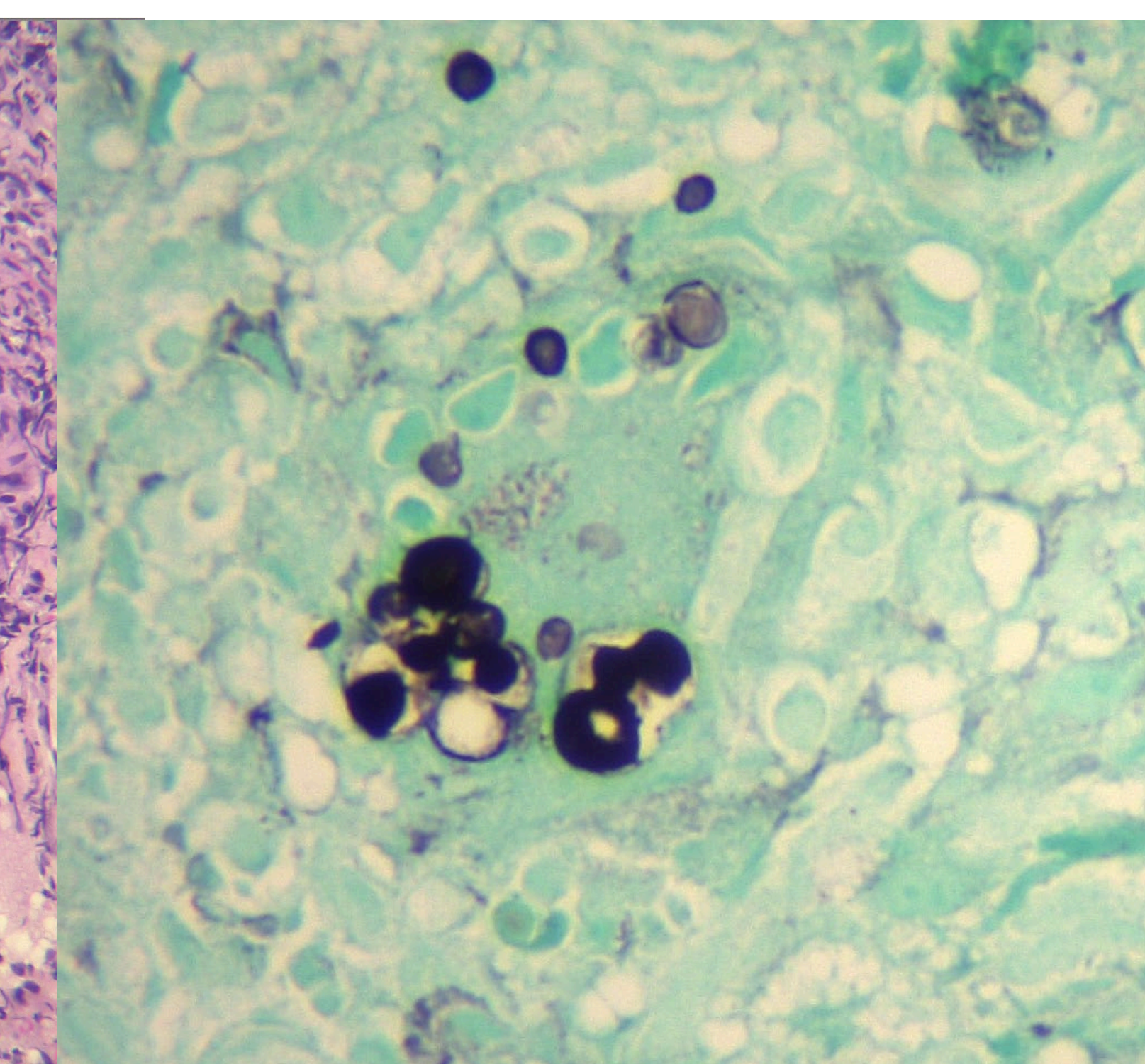
**Figure 1:** Chest XR on admission showing extensive right greater than left infiltrates with a nodular appearance, central vascular prominence, and possible right hilar adenopathy.



**Figure 2:** Chest CT with contrast showing extensive nodular, ground glass, and reticular infiltrates in the right greater than left lung predominantly involving the right upper lobe.



**Figure 3:** H&E staining revealing morphological characteristics of granulomatous inflammation (arrows) and circular structures resembling *Cryptococcus* spores.



**Figure 4:** GMS(+) staining reveals *Cryptococcus* spores that are clear, black, round structures, and clear characteristics such as capsule and narrow-based budding.

## DISCUSSION

- This is a rare case of a vaper with disseminated pulmonary cryptococcosis causing a pulmonary SLR.
- SLR is commonly thought to be secondary to an immune response to tumor cells in the setting of invasive metastatic cancer. Granulomas are typically adjacent to tumor or lymphatic vessels [3,4].
- Differentiating sarcoidosis from SLR based on cryptococci is difficult since sarcoidosis may precede cryptococcal infection, whereas SLR may be caused by a cryptococcal infection [4].
- Treatment of sarcoidosis vs SLR is different; steroids are mainstay therapy for sarcoidosis, whereas SLR is treated by addressing the root cause (antifungals for cryptococcus in this case) [4].
- Further investigation is also needed into the association of EVALI with pulmonary cryptococcosis as it is currently lacking in published literature [6,7].
- **Cryptococcal infection should be considered as a cause of SLR and differentiated from sarcoidosis early for appropriate antifungal treatment.**



For more information on syndromic surveillance for EVALI, scan the QR code

## REFERENCES

- [1] Maziarz EK, Perfect JR. Cryptococcosis. *Infect Dis Clin North Am.* 2016;30(1):179-206. doi:10.1016/j.idc.2015.10.006
- [2] van der Stoep JH, Sigstad E, Bredberg A. Sarcoidosis with cryptococcal infection apparently engaging only immune-privileged body compartments: a case report. *BMC Infect Dis.* 2020;20(1):440. Published 2020 Jun 22. doi:10.1186/s12879-020-05174-5
- [3] Cohen PR, Kurzrock R. Sarcoidosis and malignancy. *Clin Dermatol.* 2007;25(3):326-333. doi:10.1016/j.clindermatol.2007.03.010
- [4] Yano S, Kobayashi K, Ikeda T, et al. Sarcoid-like reaction in *Cryptococcus neoformans* infection. *BMJ Case Rep.* 2012;2012:bcr0720114528. Published 2012 Jul 27. doi:10.1136/bcr-07-2011-4528
- [5] Yu FC, Perng WC, Wu CP, Shen CY, Lee HS. Adult respiratory distress syndrome caused by pulmonary cryptococcosis in an immunocompetent host: a case report. *Zhonghua Yi Xue Za Zhi (Taipei).* 1993;52(2):120-124.
- [6] Zulfiqar H, Sankari A, Rahman O. Vaping-Associated Pulmonary Injury. [Updated 2023 Jun 25]. In: StatPearls [Internet]. Treasure Island (FL): StatPearls Publishing; 2023 Jan. Available from: <https://www.ncbi.nlm.nih.gov/books/NBK560656/>
- [7] Smith ML, Gotway MB, Crotty Alexander LE, Hariri LP. Vaping-related lung injury. *Virchows Arch.* 2021;478(1):81-88. doi:10.1007/s00428-020-02943-0

## DISCLOSURES

The authors received no financial support for the research, authorship, and/or publication of this poster.