

SYNOVIAL FLUID

A.C.O.I. Board Review 2017

Howard L. Feinberg, D.O., F.A.C.O.I., F.A.C.R.

SYNOVIAL FLUID

- Group I Noninflammatory
- Group II Inflammatory
- Group III Septic
- Group IV Hemorrhagic

SYNOVIAL FLUID

■ Group I

- Osteoarthritis
- Thyroid
- Amyloid
- Osteonecrosis

■ Group II

- Rheumatoid
- Psoriatic
- Crystal disease
- Reiters/Reactive Arthritis
- Enteropathic
- Bechets

■ Group III

- Infection

■ Group IV


- Trauma
- Bleeding disorders
- Villonodular Synovitis

SYNOVIAL FLUID

	Normal	Group I	Group II	Group III
Volume	Low	Low	High	High
Viscosity	High	High	Low	Variable
Color	Clear	Clear/Y	Yellow	Variable
Clarity	Trans.	Trans.	Cloudy	Opaque
Mucin Clot	Firm	Firm	Friable	Friable
WBC	200	200	2-100,000	50-100,000
Culture	Neg	Neg.	Neg.	Variable

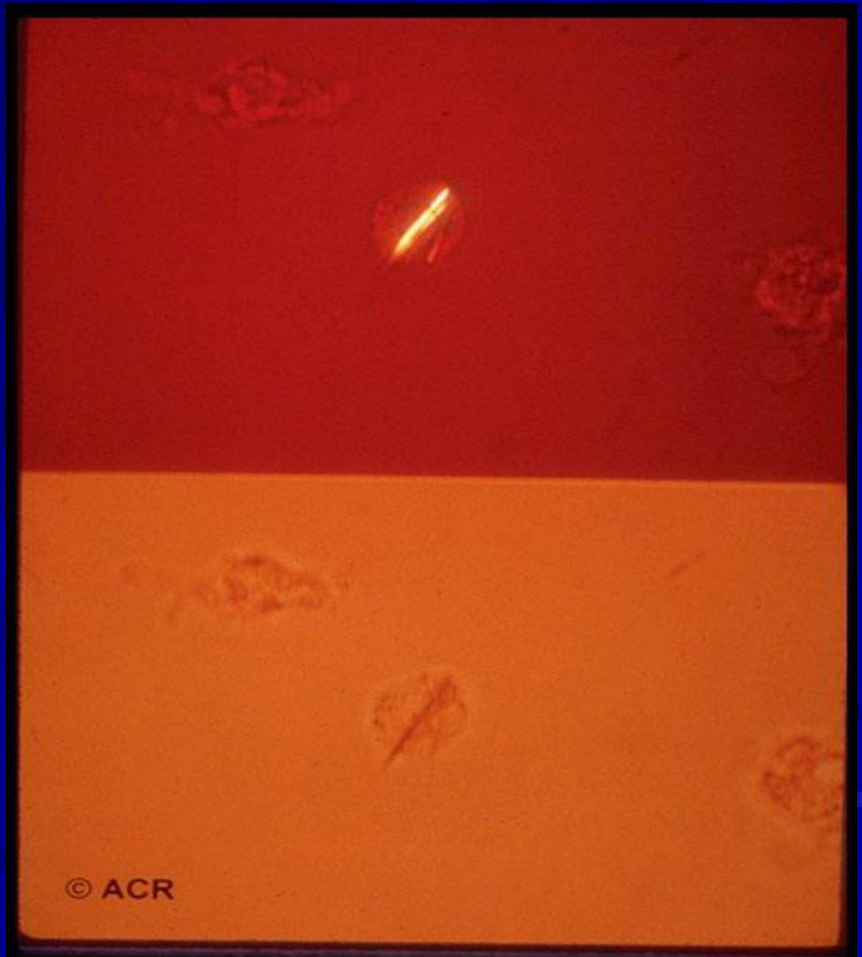
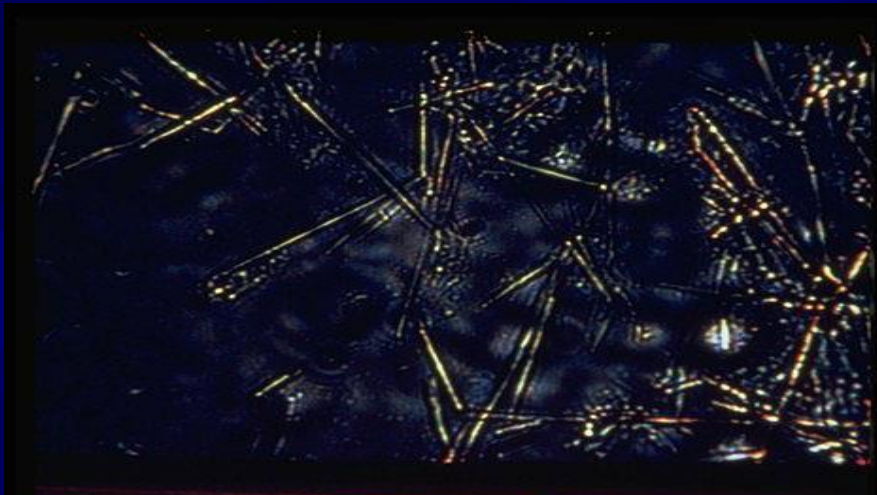
SYNOVIAL FLUID

Plate 1.

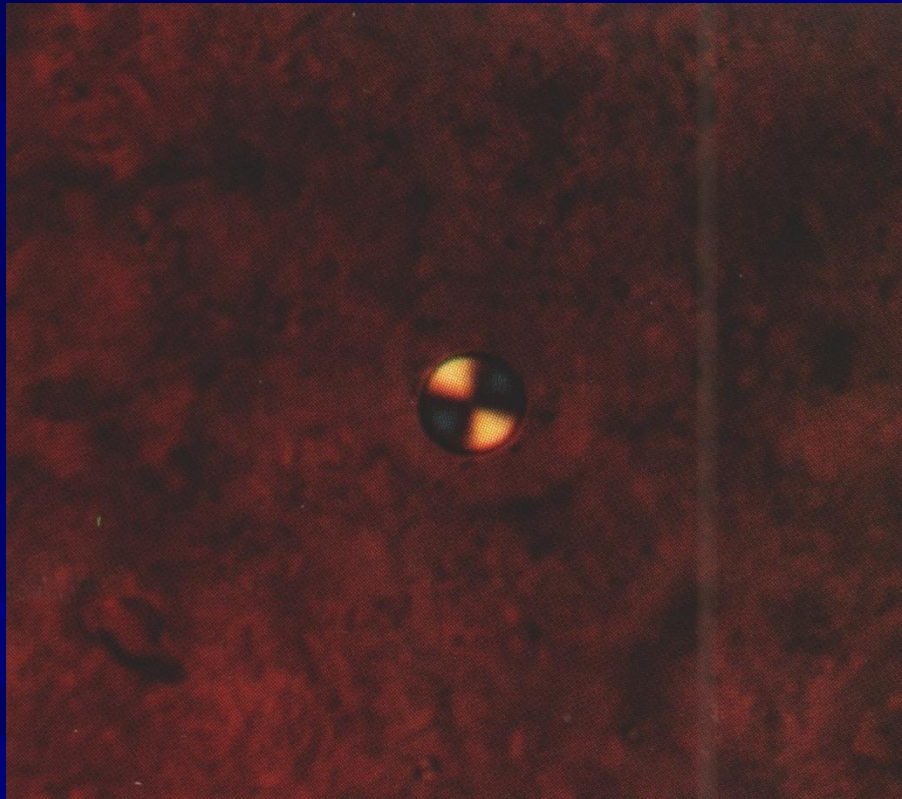


Color: A, Normal; B, Group I (noninflammatory) and Group II (inflammatory); C, Group III (septic); D, Group IV (hemorrhagic).

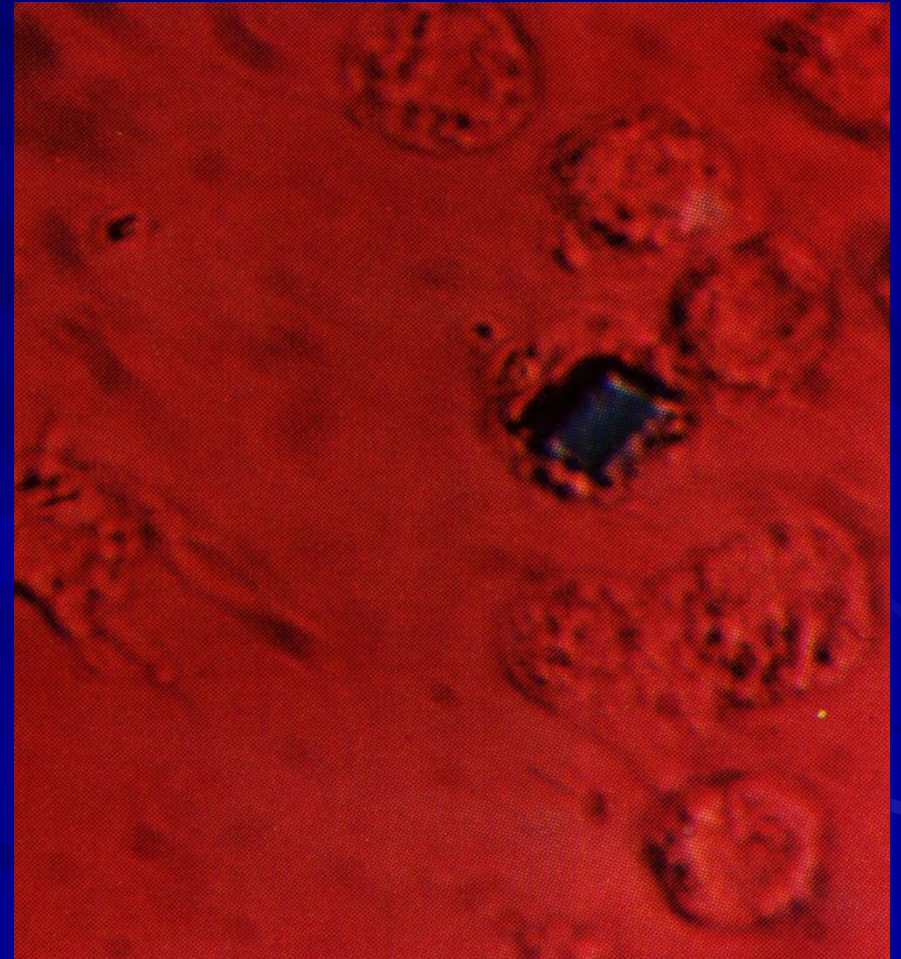
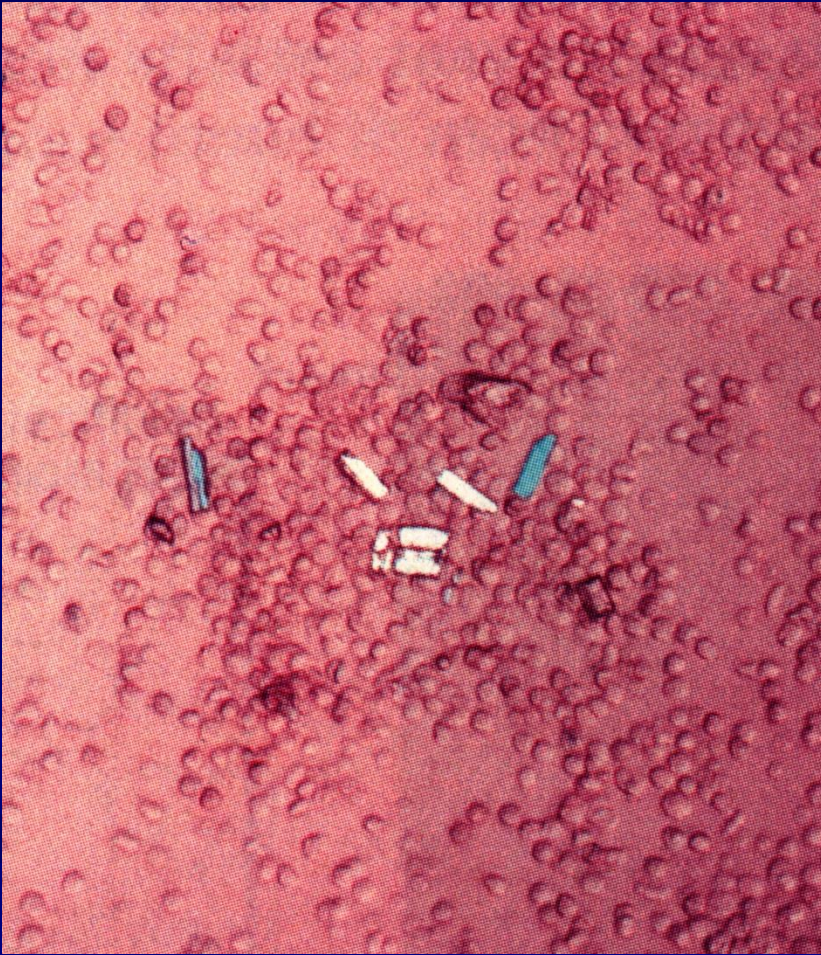SYNOVIAL FLUID



SYNOVIAL FLUID



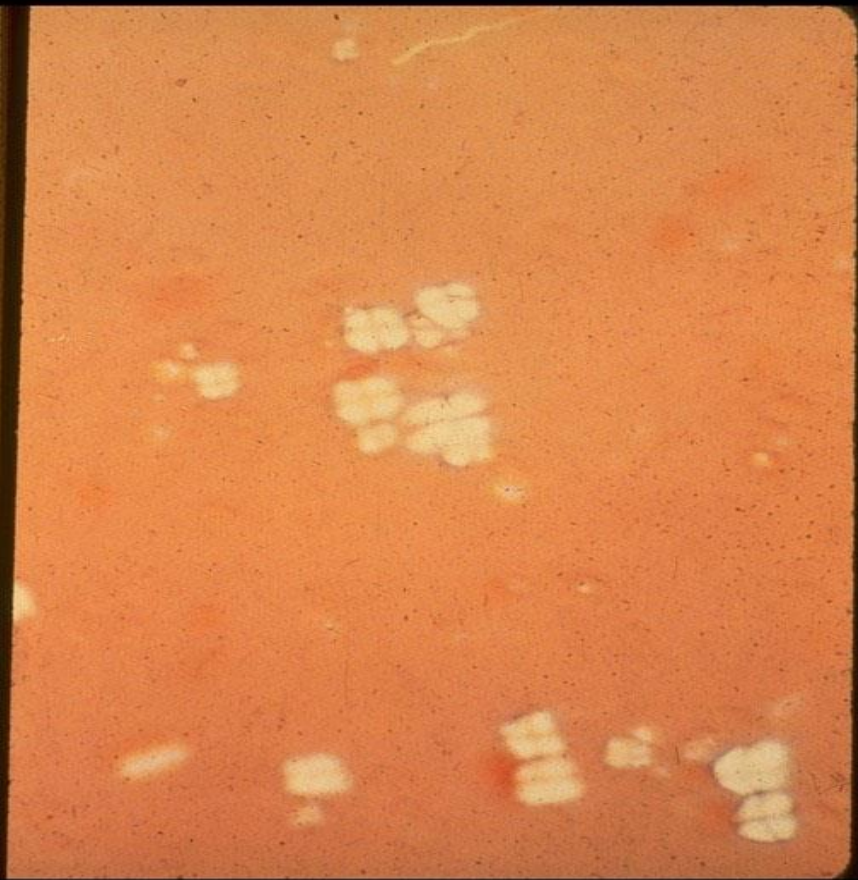
SYNOVIAL FLUID



SYNOVIAL FLUID

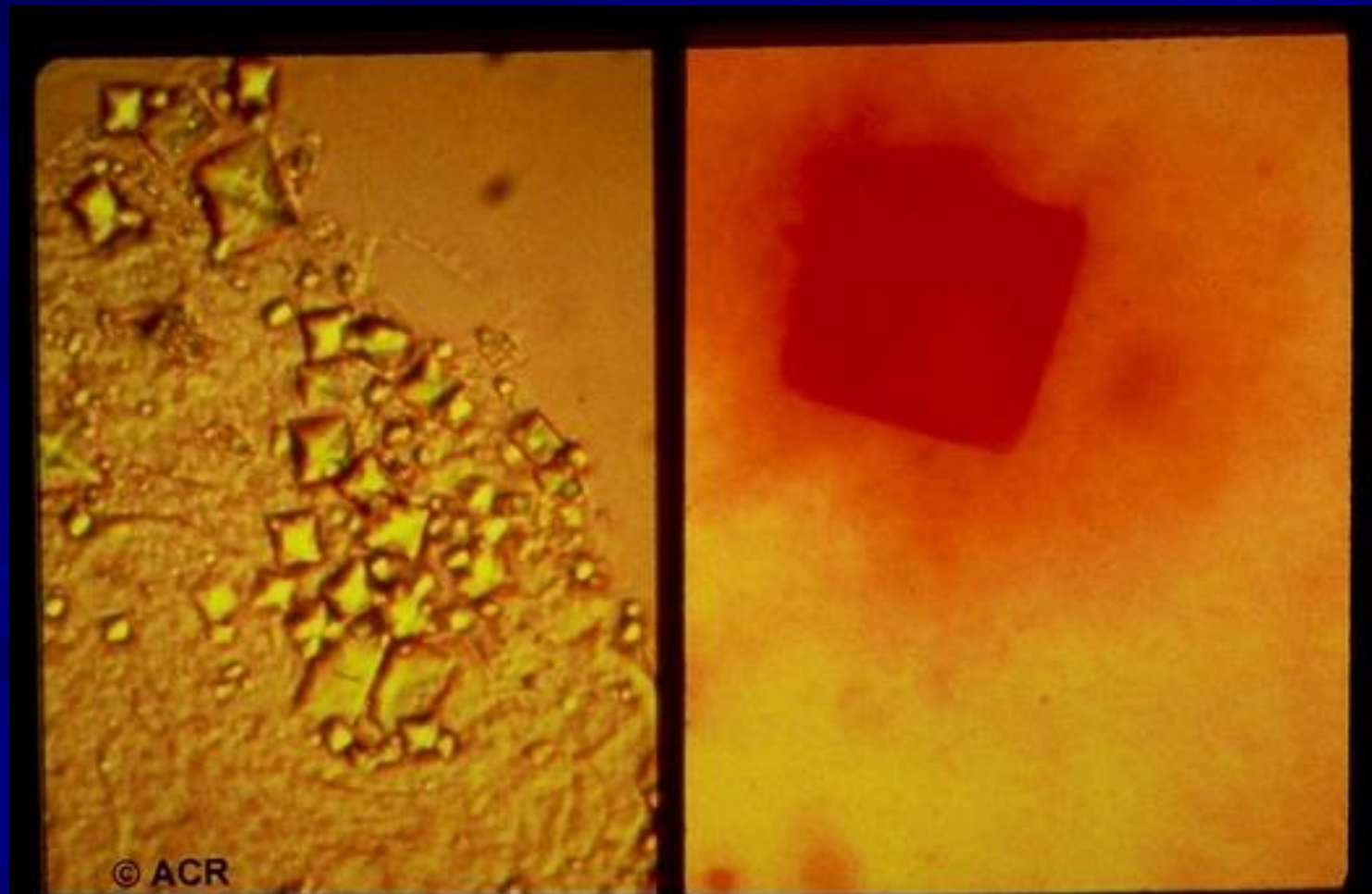
■ CHOLESTEROL

LIPID



CALCIUM OXALATE

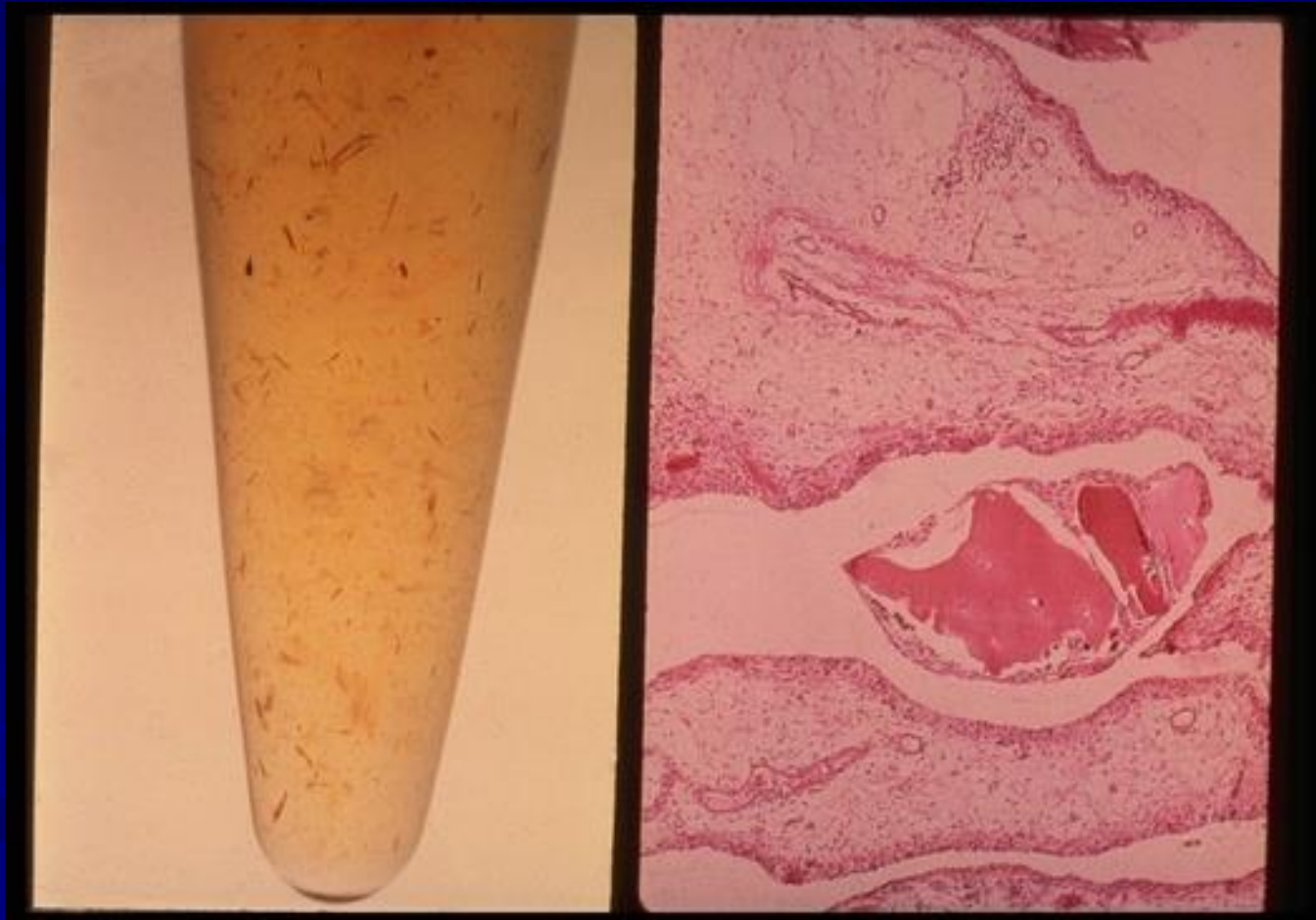- Light Microscopy Alizarin Red



STERIOD CRYSTALS



OCHRONOSIS



Contact Information

Howard Feinberg, D.O., F.A.C.O.I., F.A.C.R.

1310 Club Drive

Vallejo, CA 94592

Howard.Feinberg@TU.edu