

Venous Thromboembolism 2017: An Update



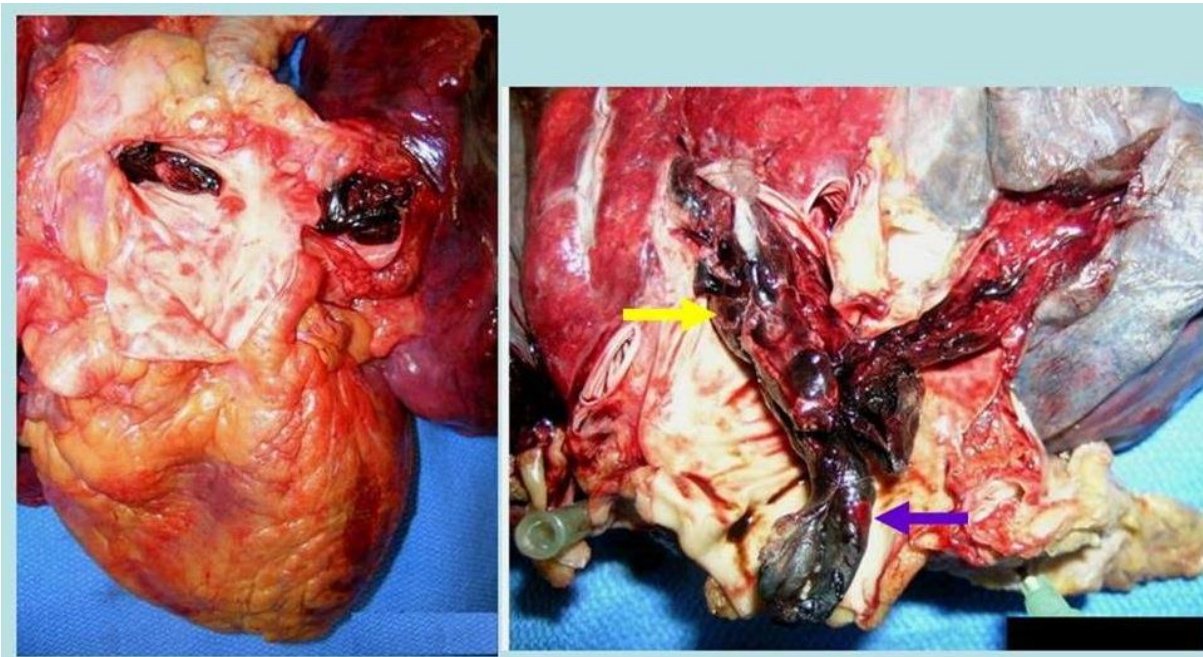
Thomas F. Morley, DO, FACOI, FCCP, FAASM
Professor of Medicine
Chairman Department of Medicine
Director of the Division of Pulmonary, Critical Care and Sleep
Medicine
Rowan University School of Osteopathic Medicine



No Disclosures

Pulmonary Embolism

Its severity ranges from asymptomatic, incidentally discovered subsegmental thrombi to massive, pressor-dependent PE complicated by cardiogenic shock and multisystem organ failure.



Risk Factors for Venous Thromboembolism

ACQUIRED

- Virchow's Triad
(stasis, venous injury, hypercoagulable)
- Prior history of thromboembolic disease
- Prior surgical history or trauma
- Immobilization/paralysis
- Cancer
- Estrogen Therapy
- Pregnancy/Postpartum
- Antiphospholipid antibody syndrome




Established or Potential Hypercoagulable States

- Activated protein C resistance
- Alpha-macroglobulin deficiency
- Anticardiolipin antibodies
- Antithrombin deficiency**
- Dysfibrinogenemia
- Factor V Leiden**
- Factor V deficiency/excess
- Factor VII excess
- Factor VIII excess
- Factor XI excess
- Heparin cofactor II deficiency
- Hyperhomocysteinemia
- Hyperfibrinogenemia
- Lupus anticoagulants
- PAI-1 excess
- Plasminogen deficiency
- Protein C deficiency
- Protein S deficiency
- Prothrombin G20210A
- tPA deficiency
- TFPI deficiency
- Thrombomodulin deficiency

PAI-1=plasminogen activator inhibitor-1; TFPI=tissue factor pathway inhibitor; tPA=tissue plasminogen activator

When to suspect a hypercoagulable state?

- 
-
- Clots in low risk patient
 - Clots in odd locations
 - Recurrent clots
 - Family history of clots
 - Spontaneous abortion



Hypercoagulable states associated with BOTH Arterial and Venous Thrombosis

Cancer

Myeloproliferative syndromes

Antiphospholipid antibodies
(APA)

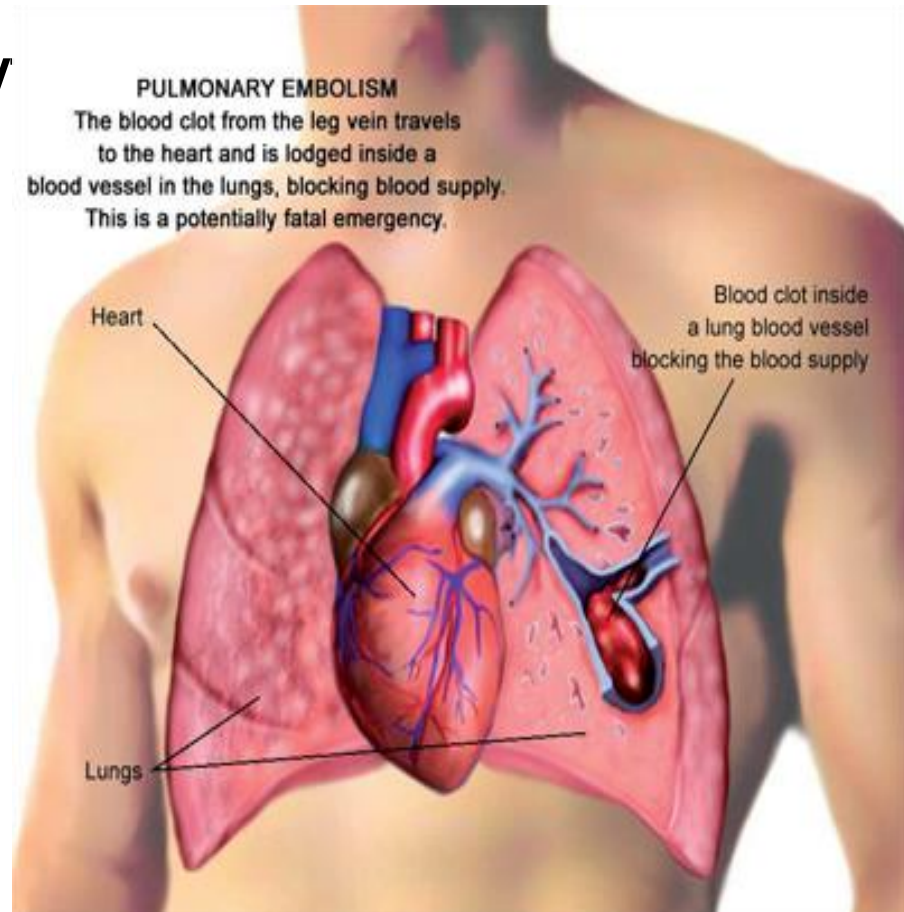
Hyperhomocysteinemia

Heparin-induced
thrombocytopenia

Nephrotic syndrome

Pulmonary Embolism Sources

- Lower extremity DV
 - 70% cases of PE
- Unusual sites
 - Right heart
 - Upper extremity
 - Renal veins
 - Iliac veins
 - Hepatic veins



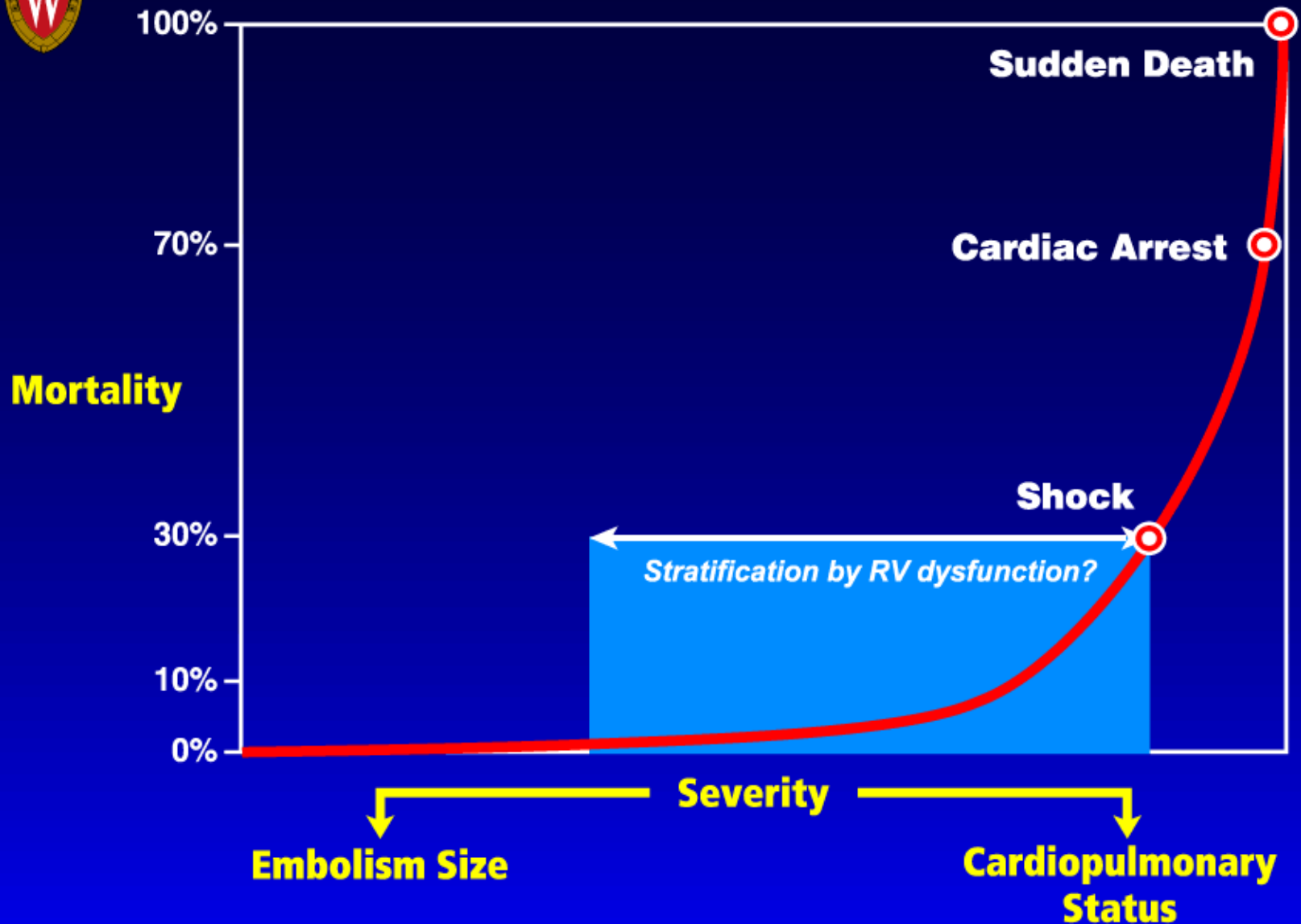


Pathophysiology

- Key consequences are hemodynamic
 - Emboli abruptly increase pulmonary vascular resistance to a level of afterload which cannot be matched by the RV.
- Sudden death may occur
 - usually in the form of electromechanical dissociation
- These effects of depend:
 - Extent of obstruction
 - Duration over which obstruction accumulates
 - Pre-existing cardiopulmonary state of patient



Outcomes in Pulmonary Embolism



European Heart Journal

Pulmonary Embolism

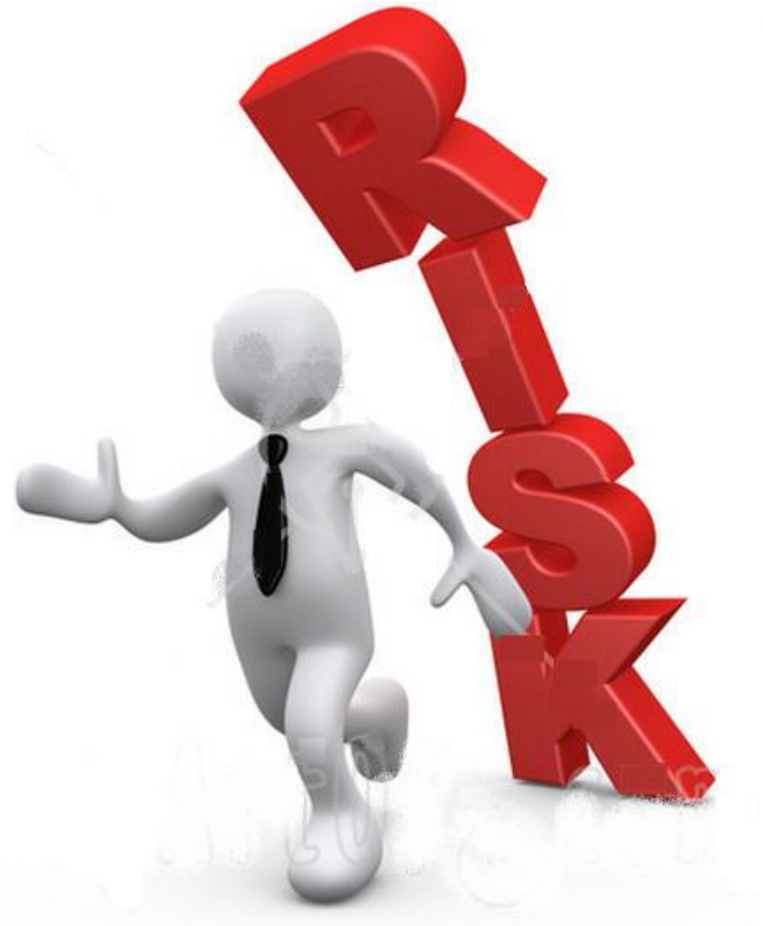Risk Assessment and Management

Stavros Konstantinides, Samuel Z. Goldhaber

Eur Heart J. 2012;33(24):3014-3022.

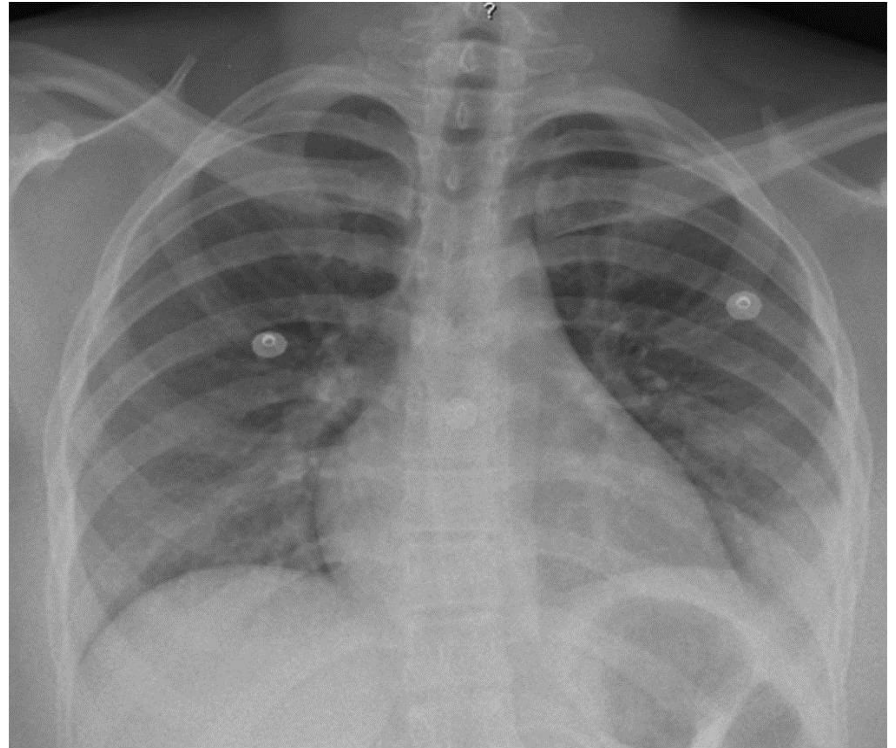
Initial Risk Stratification

- Effective treatment of PE in the acute phase lies in the assessment of the patient's early death risk
- Crucial determinant is the presence and severity of right ventricular (RV) dysfunction resulting from acute pressure overload.



Clinical Definitions

- The definition of **high-risk** (European classification) or **massive** (North American classification) PE is usually straightforward and **relies on the presence of clinically overt RV failure which results in haemodynamic compromise.**





Initial Risk Stratification

- High-risk (European classification)
- Massive (North American classification)
- Patients present with hypotension or syncope or PEA
- Some would add refractory hypoxemia to this group

Torbicki A, et al. Guidelines on the diagnosis and management of acute pulmonary embolism: The Task Force for the Diagnosis and Management of Acute Pulmonary Embolism of the European Society of Cardiology (ESC). *Eur Heart J* 2008;

Jaff MR, et al. Management of massive and submassive pulmonary embolism, iliofemoral deep vein thrombosis, and chronic thromboembolic pulmonary hypertension: a scientific statement from the American Heart Association. *Circulation* 2011;123:1788–1830.

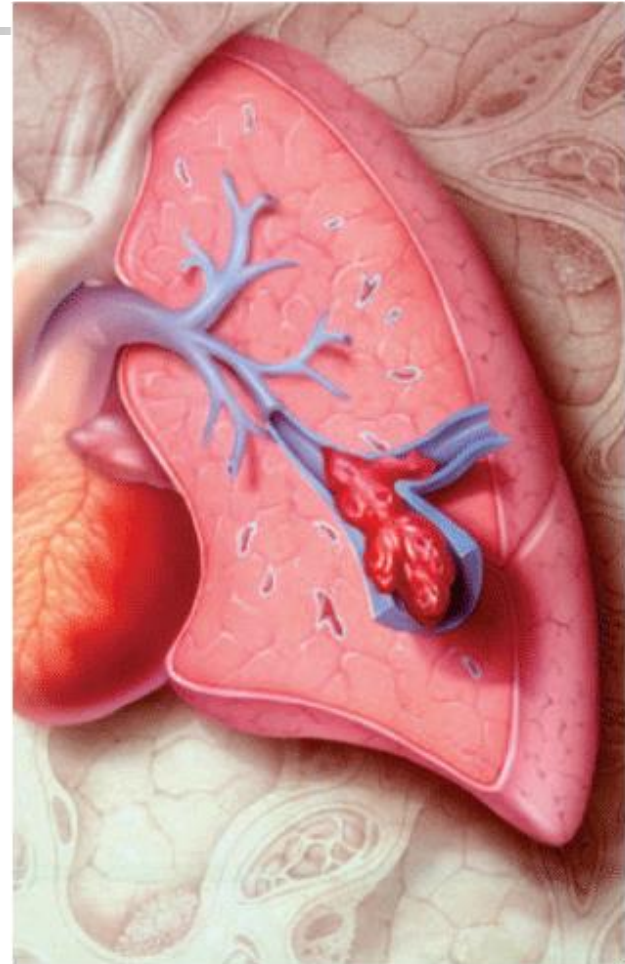


High Risk or Massive PE

- This condition, which is encountered in <5% of all patients presenting with acute PE constitutes a medical emergency, since it is associated with at least a 15% risk of in-hospital death, particularly during the first hours after admission.

Advanced Risk Stratification: Clinical Scores

- Some of the (initially) normotensive patients with acute PE may have an elevated risk of death or major complications (intermediate-risk PE in Europe; submassive PE in North America) which warrants further risk stratification and possibly specific advanced therapy.





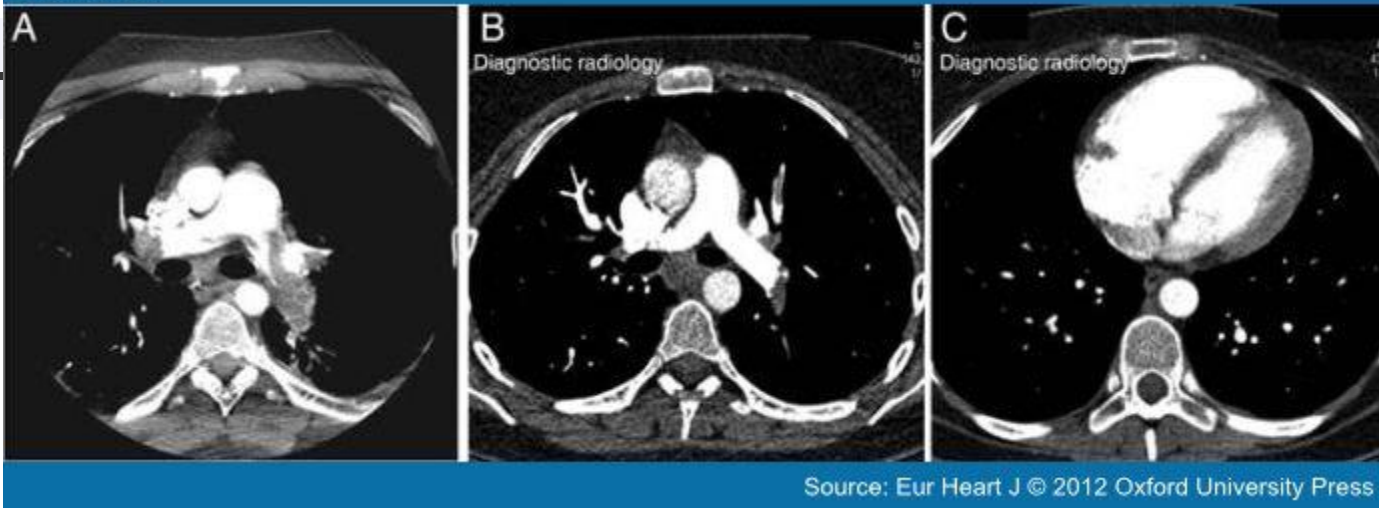
BNP and proBMP

- A meta-analysis of 13 studies found that 51% of 1132 patients with acute PE had elevated brain natriuretic peptide (BNP) or N-terminal (NT)-proBNP concentrations; these were associated with an increased risk of early death and a complicated in-hospital course.[34] Nevertheless, their positive predictive value for an elevated risk has been consistently low.

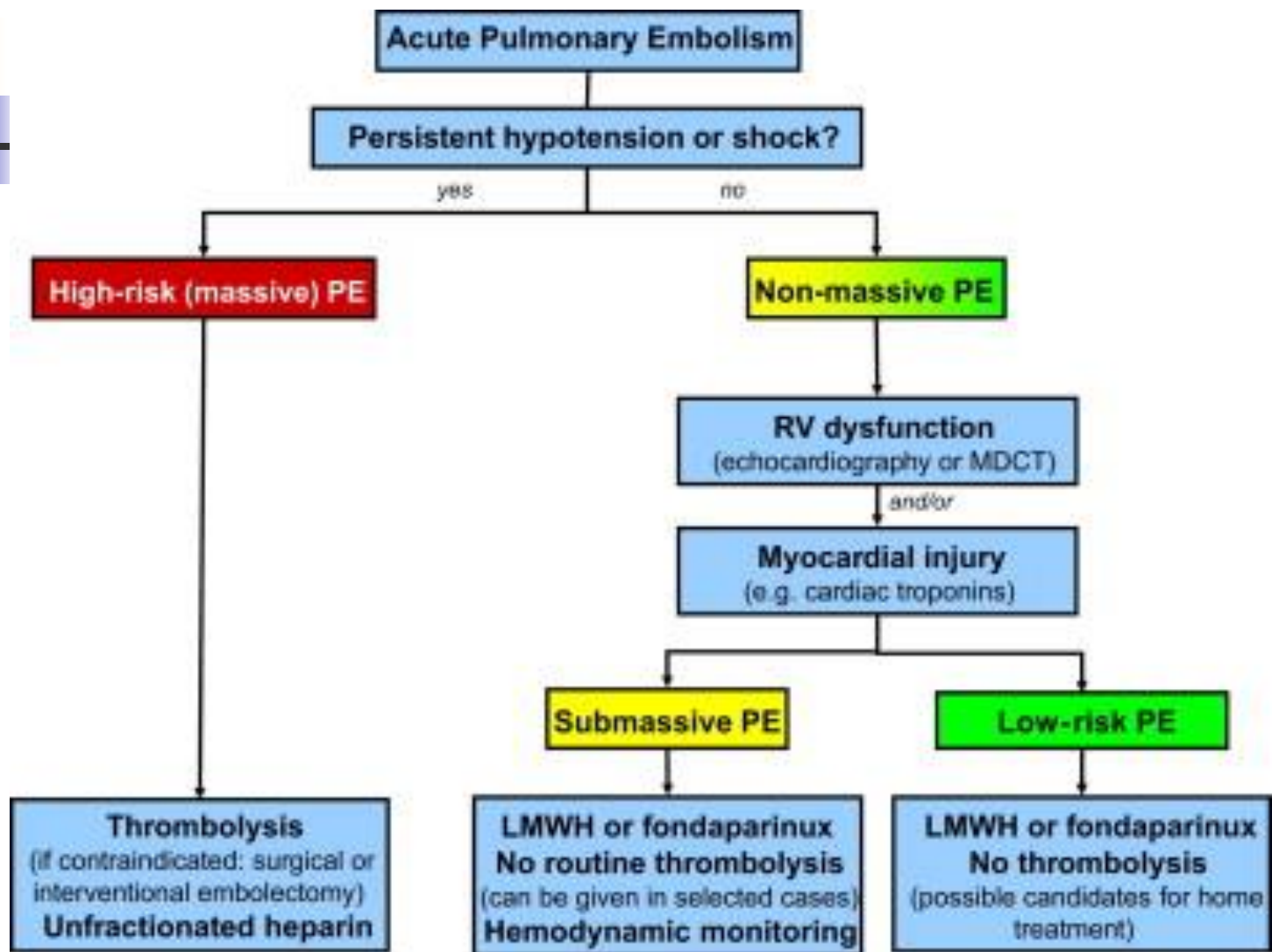



Troponin

- Elevated cardiac troponin I or T levels are also found in up to 50% of the patients with acute PE.
- A meta-analysis of studies published between 1998 and 2007, with a total of 1985 patients, showed that cardiac troponin elevation was associated with an increased risk of death and major adverse events in the acute phase.
- However, another meta-analysis which excluded hypotensive patients did not confirm the prognostic value of circulating troponin levels.
- Recently developed high-sensitivity assays may improve the prognostic performance of this biomarker, at least at the low-risk end of the severity spectrum. More specifically, a derivation study showed that high-sensitivity troponin T (hsTnT) was useful for excluding an adverse outcome in the acute phase of PE.[39] In a multicentre, multinational cohort of 526 normotensive patients with acute PE, hsTnT exhibited a high NPV (98%).



The extent of thrombotic load on computed tomography does not always correlate with the clinical severity of acute pulmonary embolism or its impact on right ventricular function. (A) A straightforward case in which massive thrombi are present in both the right and the left pulmonary artery of a patient presenting with haemodynamic instability (persistent tachycardia, systolic blood pressure between 90 and 100 mmHg). (B) However, a patient presenting with similar clinical findings had an apparently much smaller thrombotic load on computed tomography; in this latter patient, the size of thrombi was also in discordance with the impressive enlargement (as a surrogate for dysfunction) of the right ventricle (C).





Advanced Risk Stratification: Clinical Scores

- The Pulmonary Embolism Severity Index (PESI) is the most extensively validated prognostic clinical score to date.
- Its major strength lies in excluding (ruling out) an adverse outcome as indicated by the high negative predictive value (NPV) of the lowest PESI classes I and II.
- The main limitation of the index is that it requires numerous variables and is relatively complex to calculate, which may reduce its practicability in high-volume centres.

Wells' Criteria for Assessment of Pretest Probability

The Wells Criteria for assessing pretest probability is important for diagnosing DVT and PE. Below describes the criteria and scoring system:

Criteria	Points
Suspected DVT	3.0
An alternative diagnosis is less likely than PE	3.0
Heart rate > 100 beats per minute	1.5
Immobilization or surgery in the previous four weeks	1.5
Previous DVT or PE	1.5
Hemoptysis	1.0
Malignancy (on treatment, treated in the past six months or palliative)	1.0

Score range	Mean probability of PE	% with this score	Interpretation of risk
<2 points	3.6%	40	Low
2 to 6 points	20.5%	53	Moderate
>6 points	66.7%	7	High

Source: Adapted with permission from Wells PS, Anderson DR, Rodger M, et al. Derivation of a simple clinical model to categorize patients' probability of pulmonary embolism: Increasing the models utility with the SimpliRED D-dimer. *Thromb Haemost.* 2000;83:416-420.

Revised Geneva score⁶⁴		Wells score⁶⁵	
Variable	Points	Variable	Points
Predisposing factors		Predisposing factors	
Age >65 years	+1	Previous DVT or PE	+1.5
Previous DVT or PE	+3	Recent surgery or immobilization	+1.5
Surgery or fracture within 1 month	+2	Cancer	+1
Active malignancy	+2	Symptoms	
Symptoms		Haemoptysis	+1
Unilateral lower limb pain	+3	Clinical signs	
Haemoptysis	+2	Heart rate	
Clinical signs		>100 beats/min	+1.5
Heart rate		Clinical signs of DVT	+3
75–94 beats/min	+3	Clinical judgement	
≥95 beats/min	+5	Alternative diagnosis less likely than PE	+3
Pain on lower limb deep vein at palpation and unilateral oedema	+4	Clinical probability (3 levels)	
Clinical probability		Low	0–1
Total		Intermediate	2–6
Low	0–3	High	≥7
Intermediate	4–10	Clinical probability (2 levels)	
High	≥11	PE unlikely	0–4
		PE likely	>4

From Torbicki. *Eur Heart J* 2008



D-dimer

- Plasma D-dimer degradation product of crosslinked fibrin
- Useful in ruling out clot
 - High negative predictive value (NPV)
- Fibrin present in many other disorders
 - Low positive predictive value (PPV)
- ELISA-derived assays have highest sensitivity
 - Latex-derived & whole-blood agglutination assays have lower sensitivity



Techniques for Diagnosis of PE

EKG

Chest Radiographs

Echocardiogram

V/Q Scans

Helical CT

MRI

EKG Findings *of Pulmonary Embolism*



- ↗ Tachycardia
- ↗ T-wave changes
- ↗ ST-segment changes
- ↗ Right axis deviation
- ↗ S1-Q3-T3
- ↗ RBBB
- ↗ p-pulmonale

Rx:
Dx:

Room:
Oper:

Sinus tachycardia, rate 119..... Normal P axis, rate \geq 100
 High QRS voltage..... R in aVL \geq 1.2 mV
 Inferior infarct, age indeterminate..... Q's & neg T's II, III, aVF
 Anterior infarct..... 2 Q waves in V2-V4

S1Q3T3

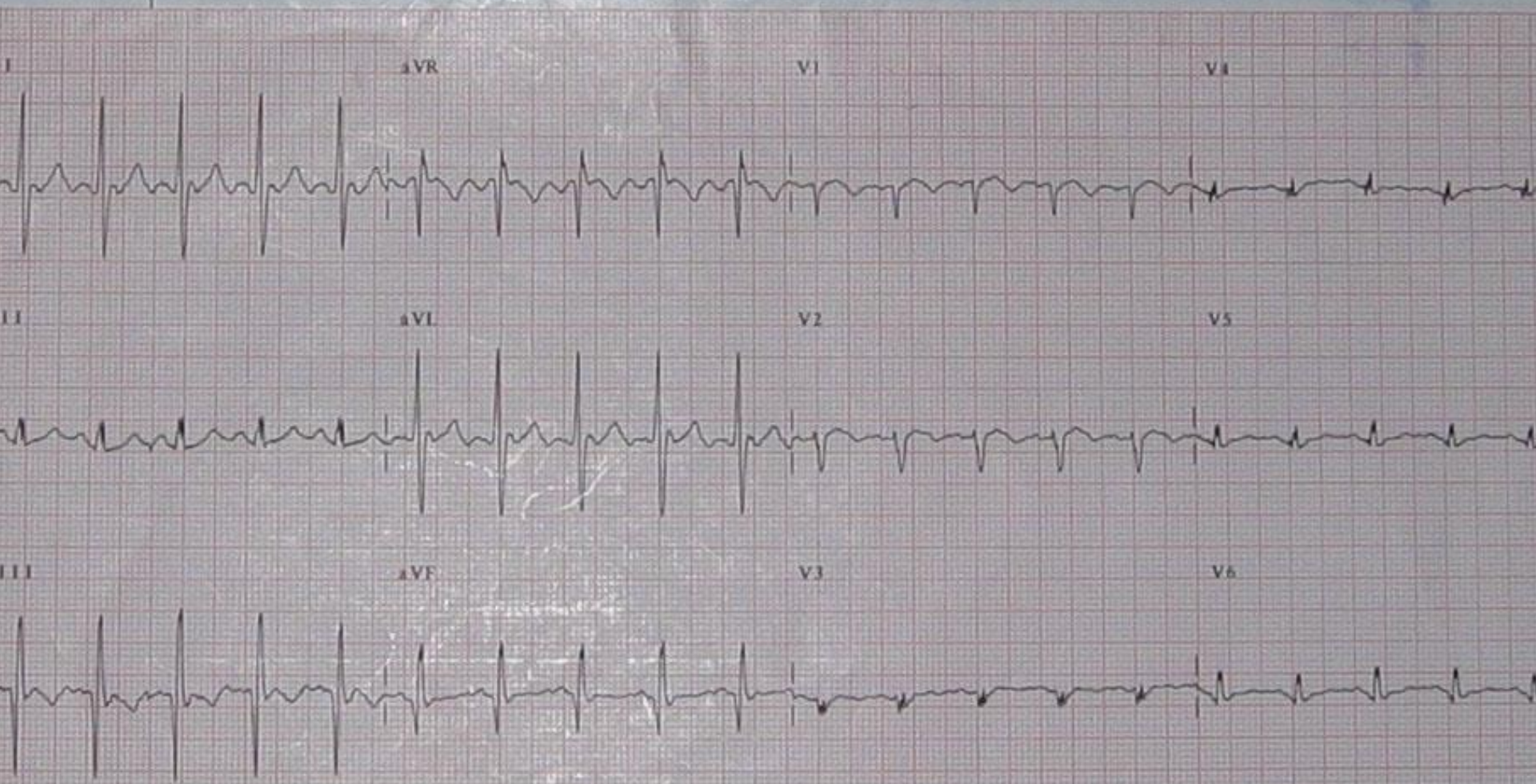
Rate 119
 PR 112
 QRSD 89
 QT 435
 QTc 435
 --AXIS--
 P 36
 QRS 57
 T -7

Requested by:



- ABNORMAL ECG -

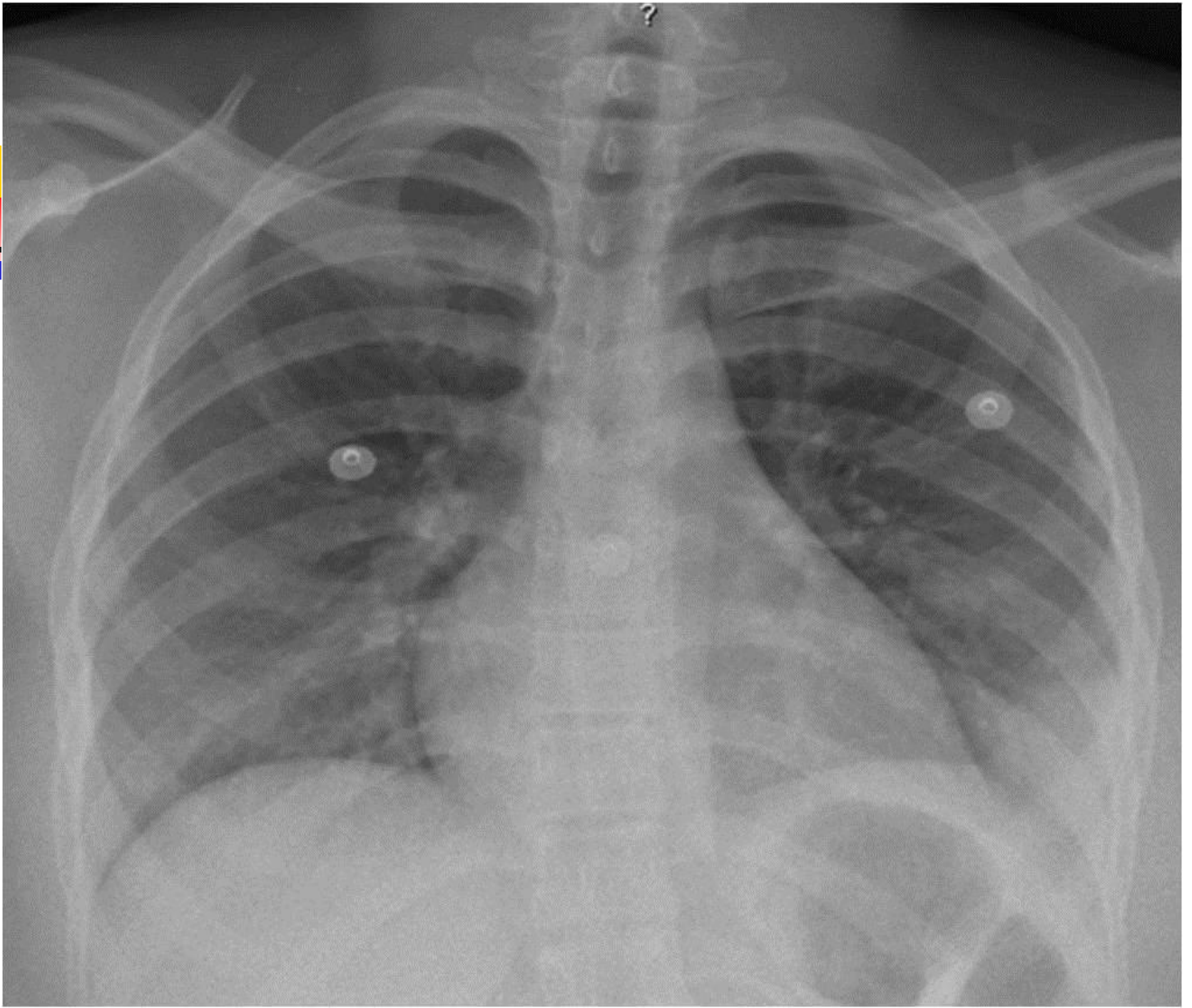
PRELIMINARY-MD MUST REVIEW

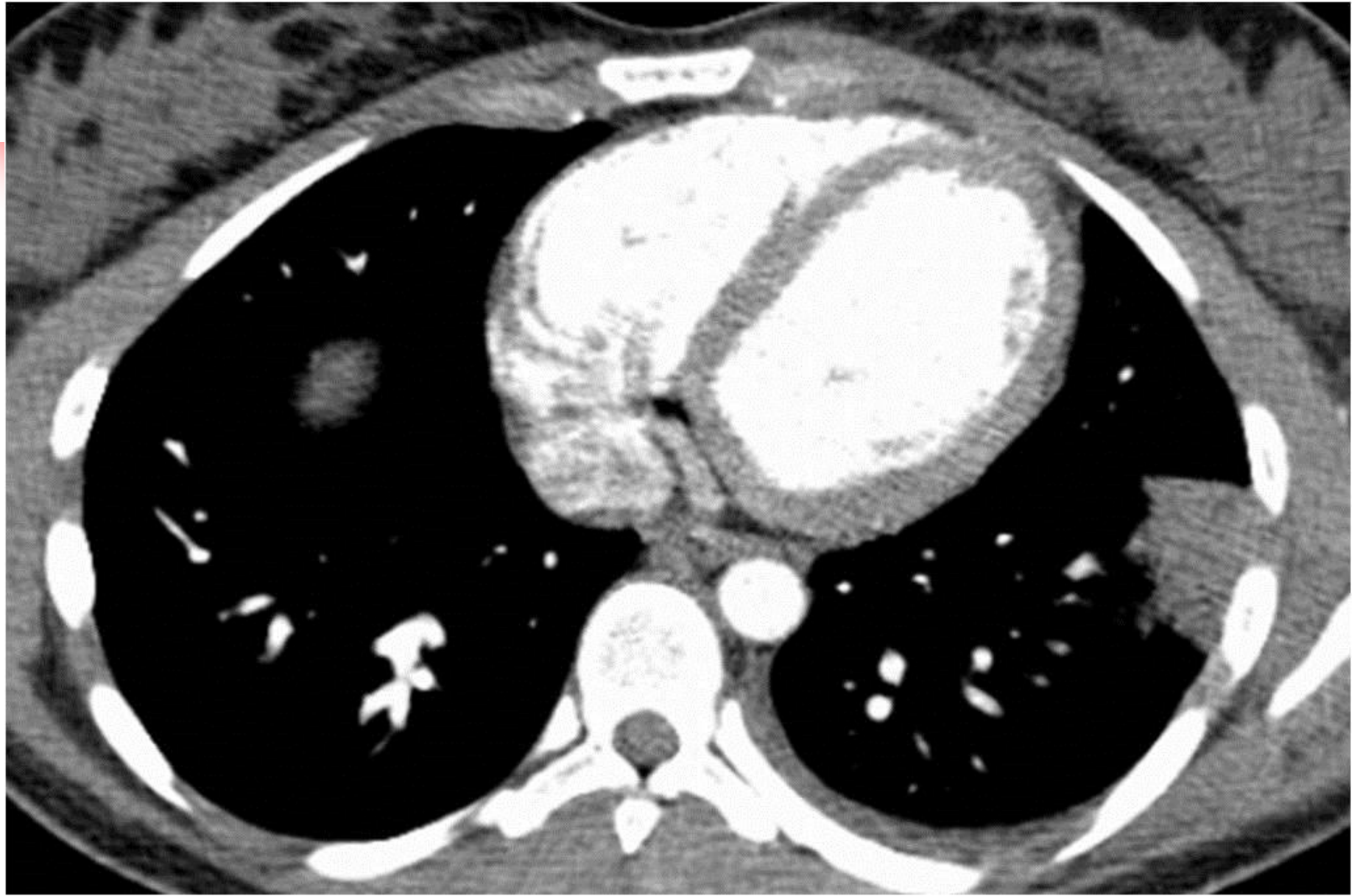




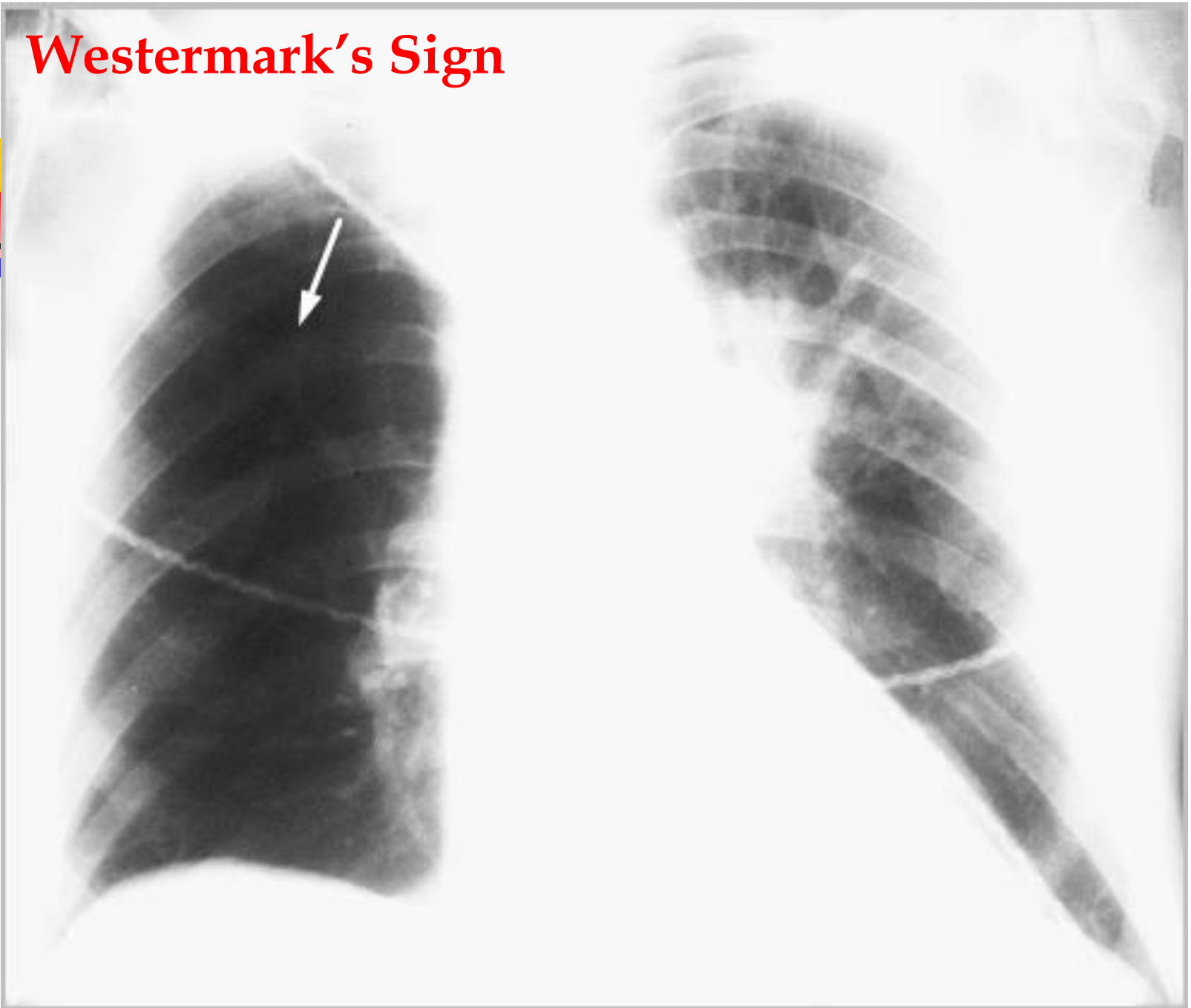Chest Radiography

- Valuable in excluding other diagnoses
 - Pneumothorax, Pneumonia, CHF, tumor, rib fx
- Aids in interpreting V/Q scan
- Radiographic signs suggest PE:
 - Hampton's hump
 - Westermark sign
 - Fleischner sign

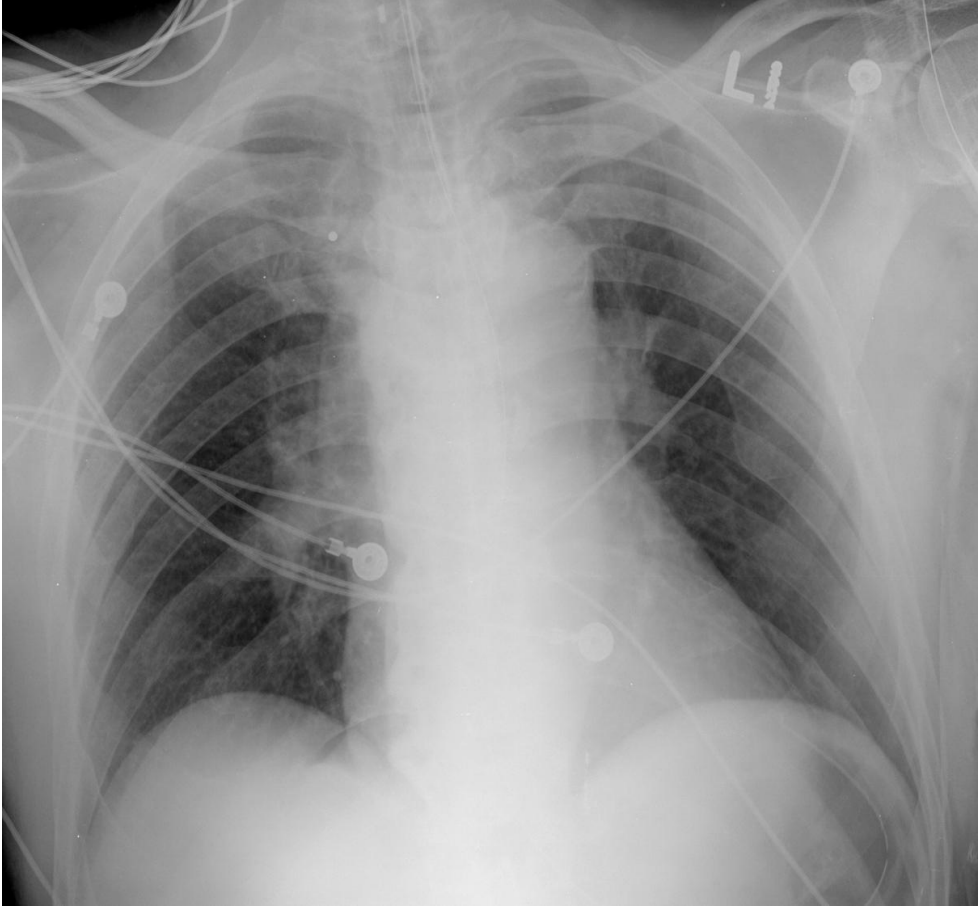
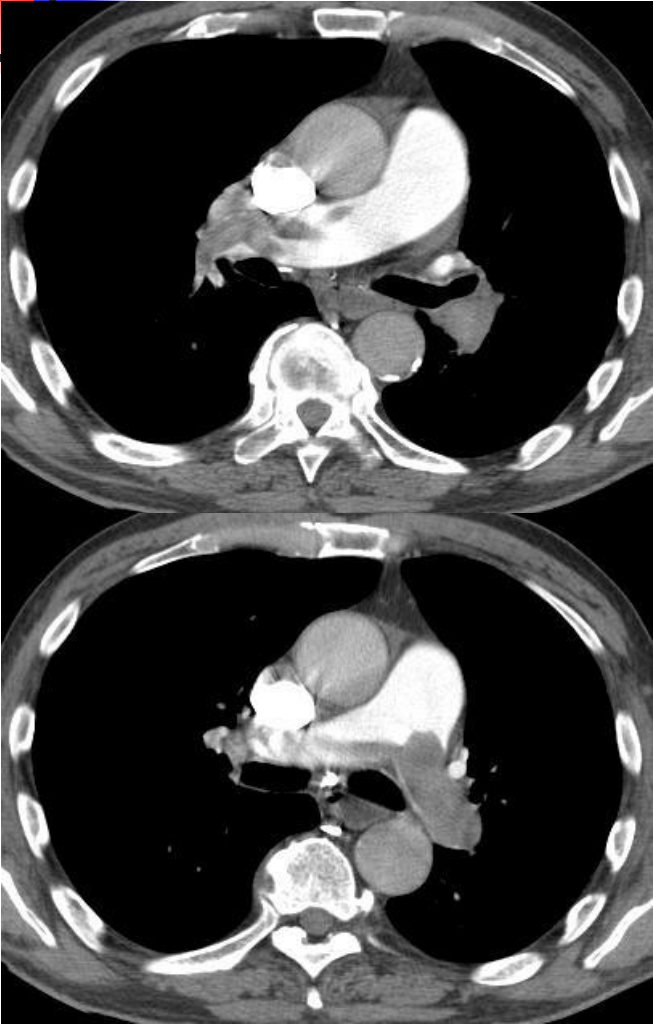




Westermarck's Sign



Fleischner sign



Echocardiogram




- Useful for rapid triage of pts
- Assess right and left ventricular function
- Diagnostic of PE if hemodynamics by echo are consistent with clinical hx

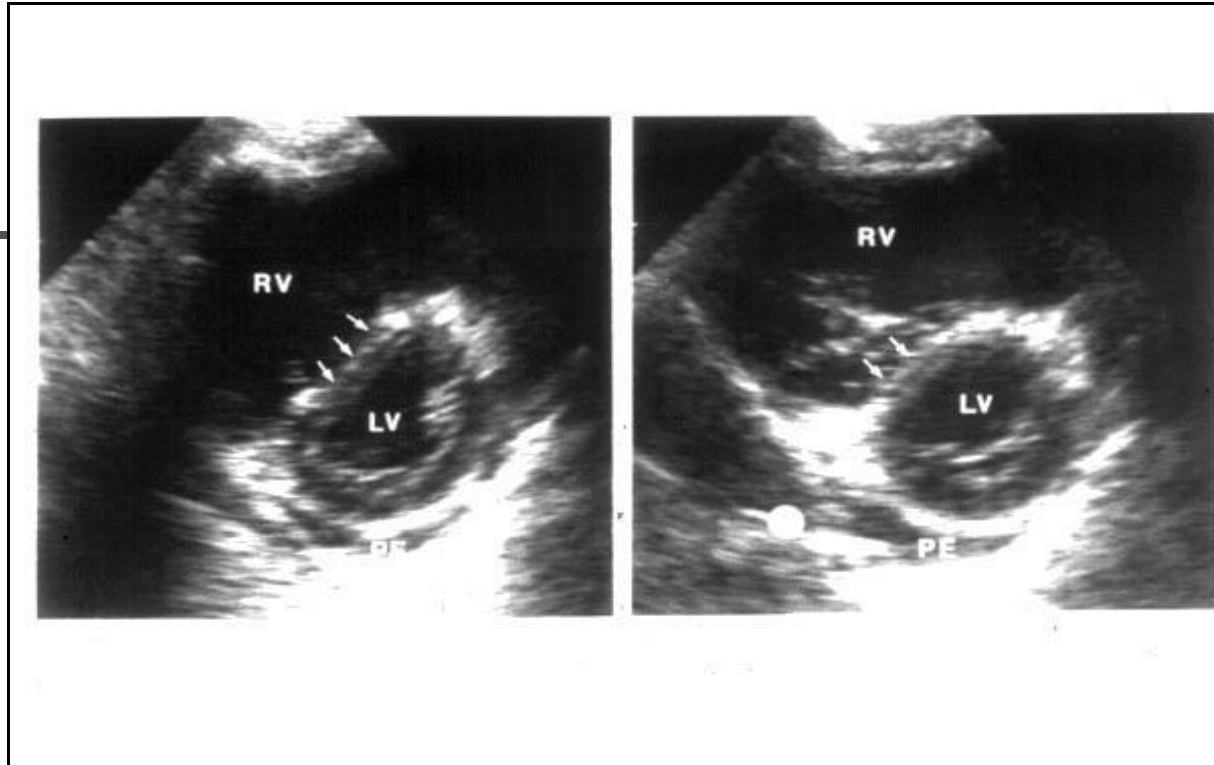
Echocardiogram



- TEE more sensitive than TTE
- Demonstrate intracardiac clot or signs of right ventricular failure
- Indirect evidence
 - right ventricular dilation
 - dilated pulmonary artery
 - abnl right ventricular wall motion
 - dilated vena cava

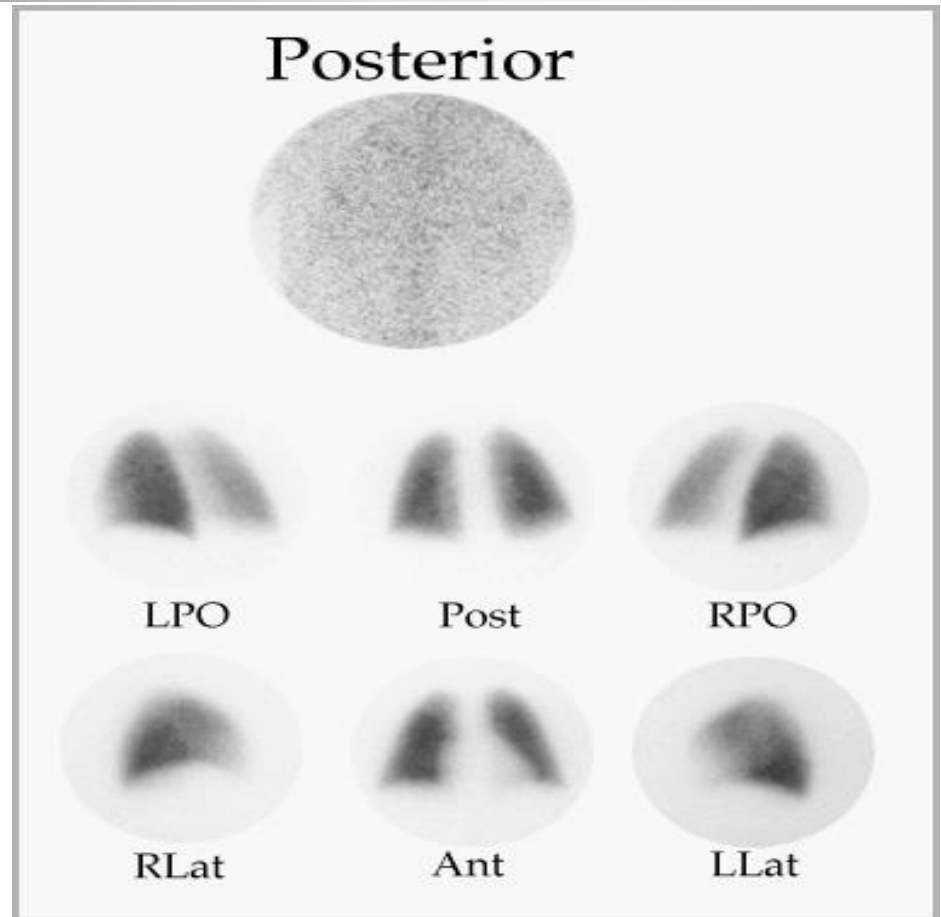
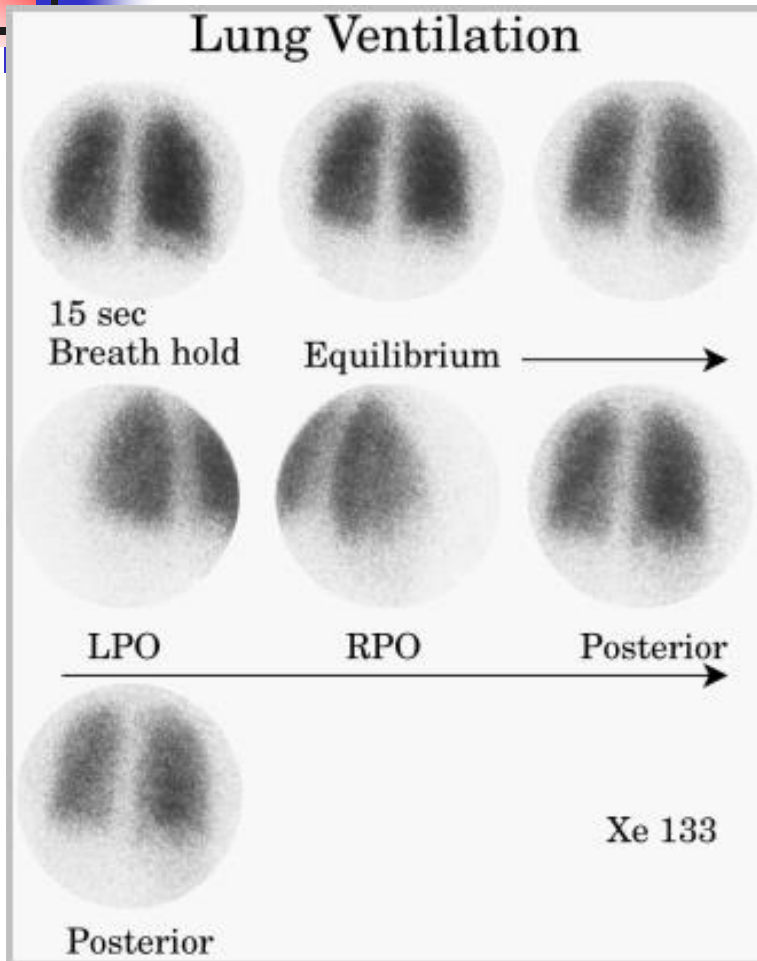
Right Ventricular Dysfunction

- 
- Progressive right heart failure is the usual immediate cause of death from PE
 - As pulmonary vascular resistance increases, right ventricular wall tension rises and perpetuates further right ventricle dilation and dysfunction
 - Interventricular septum bulges into and compresses the normal left ventricle



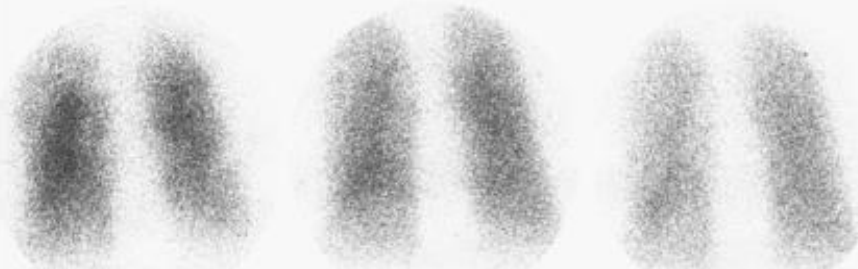Echocardiogram suggesting a PE. Diastole on the left, systole on the right

Ventilation-Perfusion (V/Q) Scans



V/Q with Multiple Defects

Lung Ventilation



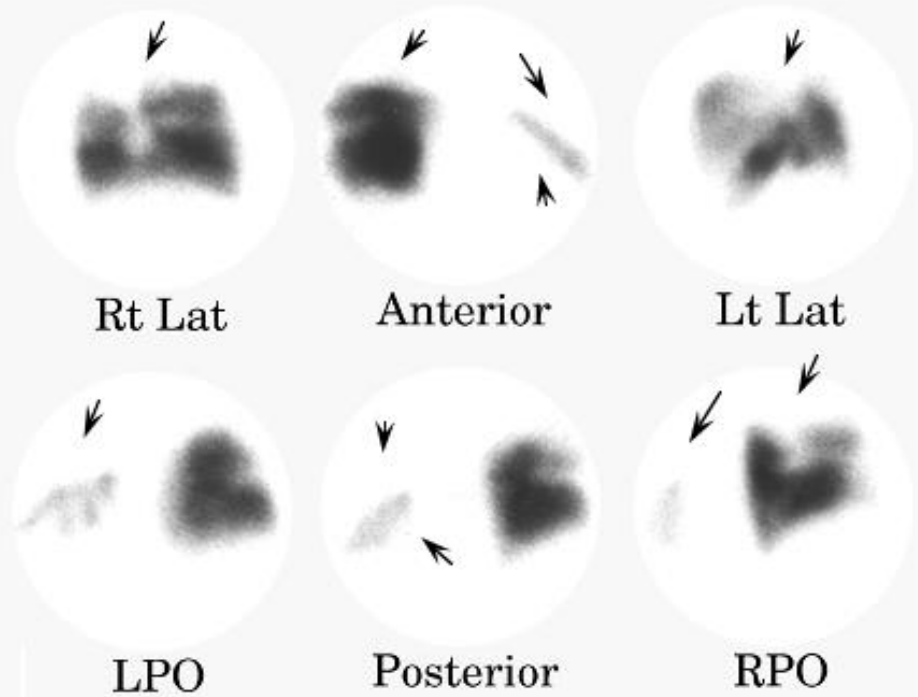
Breath hold
15 sec

Equilibrium →

LPO

RPO →

Lung Perfusion



Rt Lat

Anterior

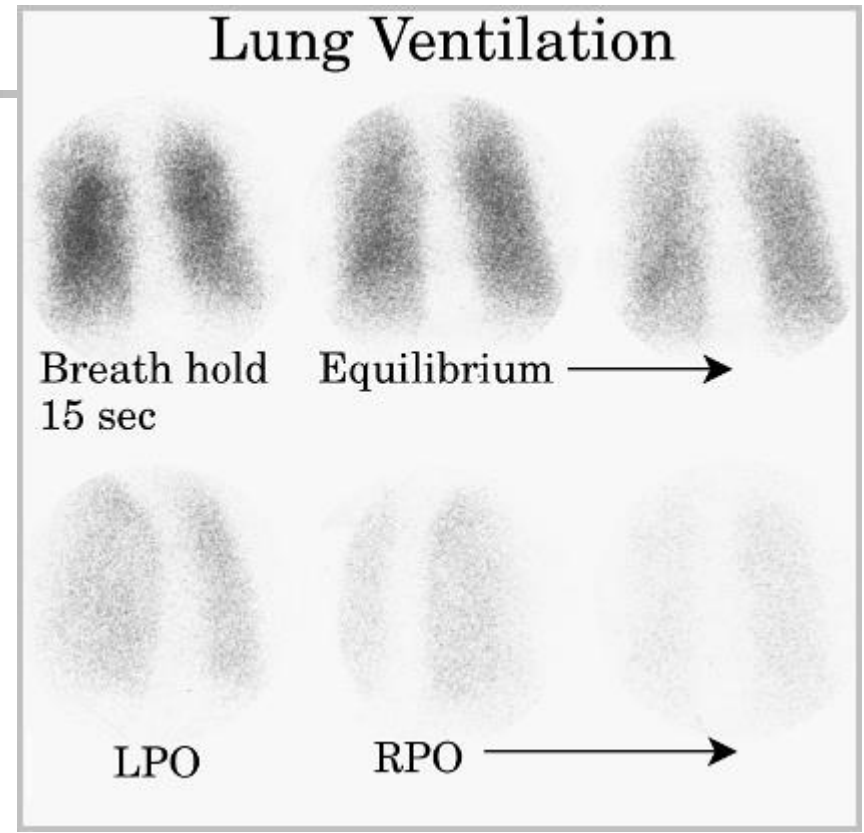
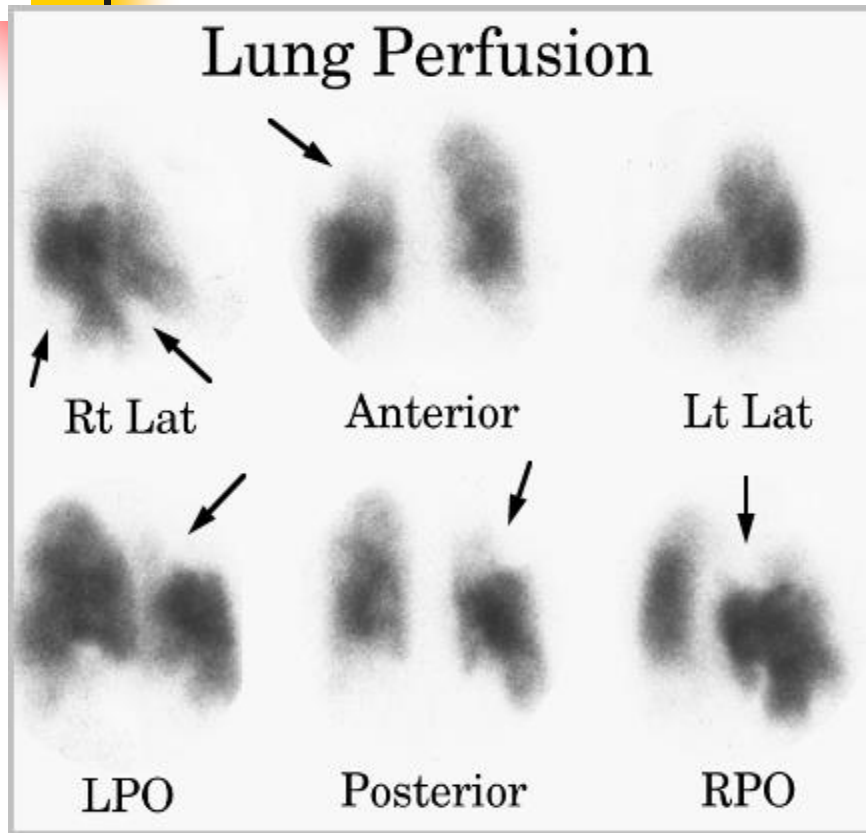
Lt Lat

LPO

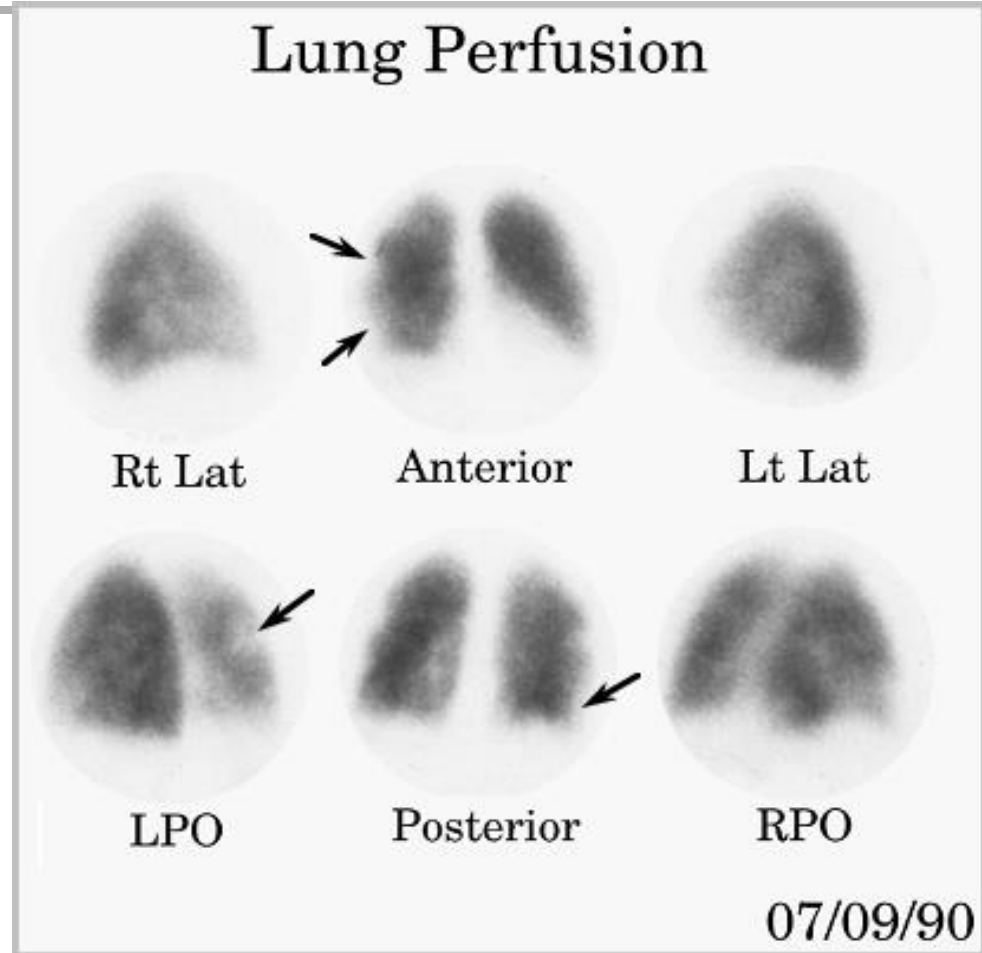
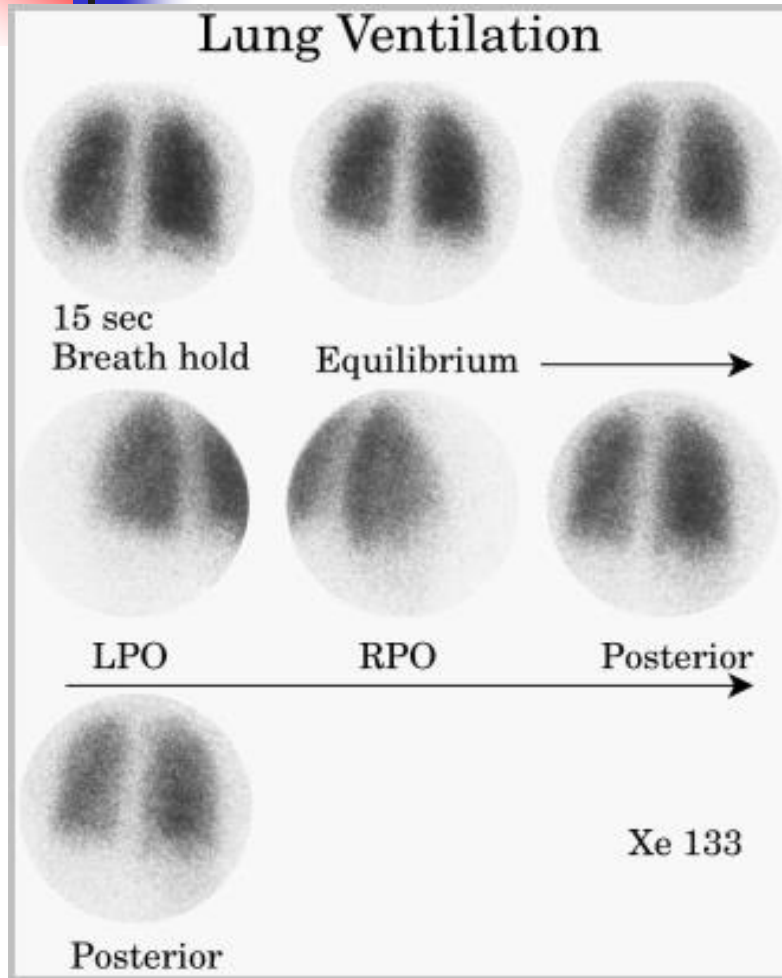
Posterior

RPO

High Probability V/Q Scan



V/Q with Subsegmental Defects




V/Q Lung Scan

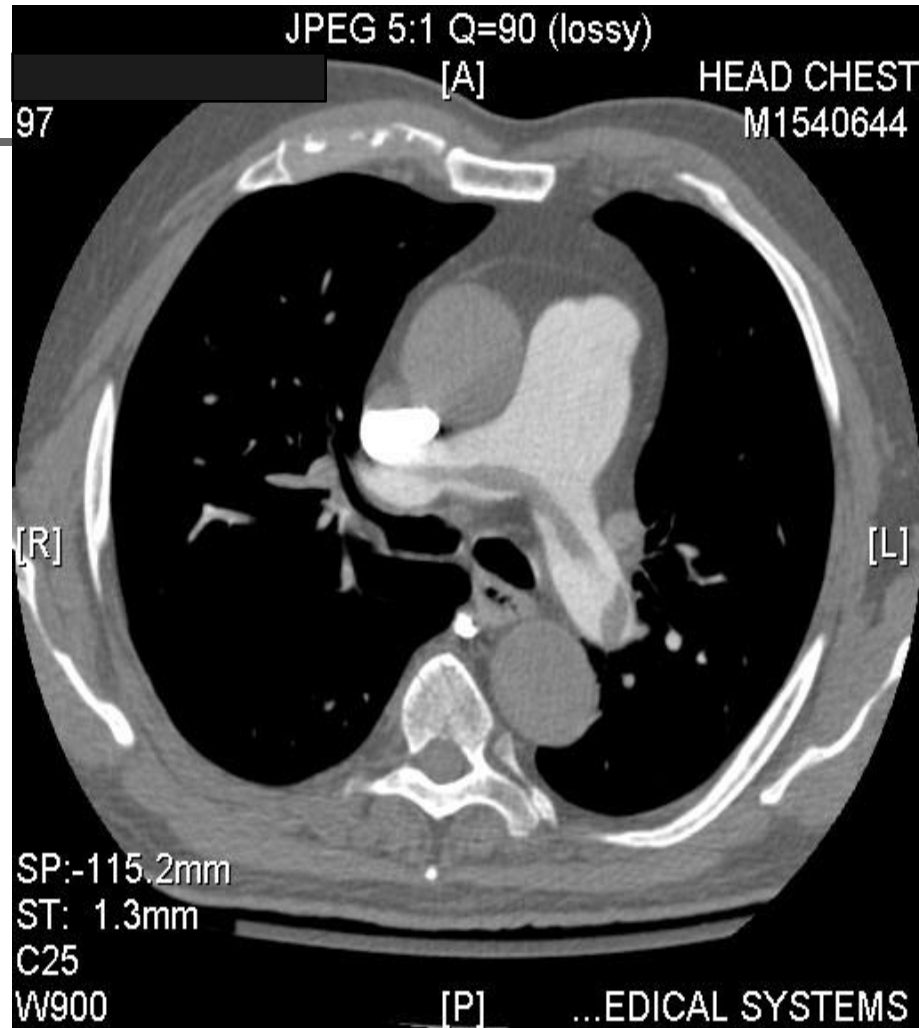


- Normal V/Q Sensitivity 99%
 - Rules *out* PE
- High Prob V/Q Specificity 96%
 - Rules *in* PE
- But, >60% nondiagnostic
- Takes >2 hr to perform
- Not available at all times

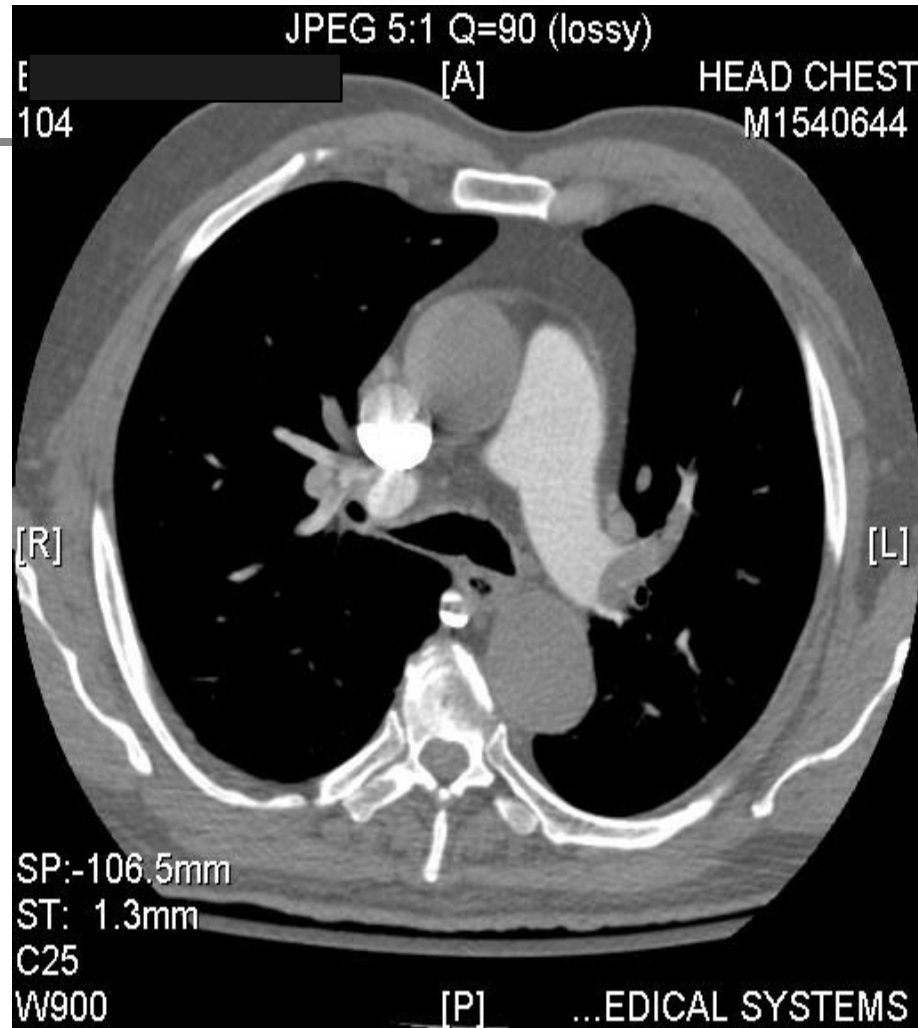
CT Pulmonary Angiogram

- 
-
- Identifies proximal PE (which are the ones usually hemodynamically important)
 - Not as accurate with peripheral PE

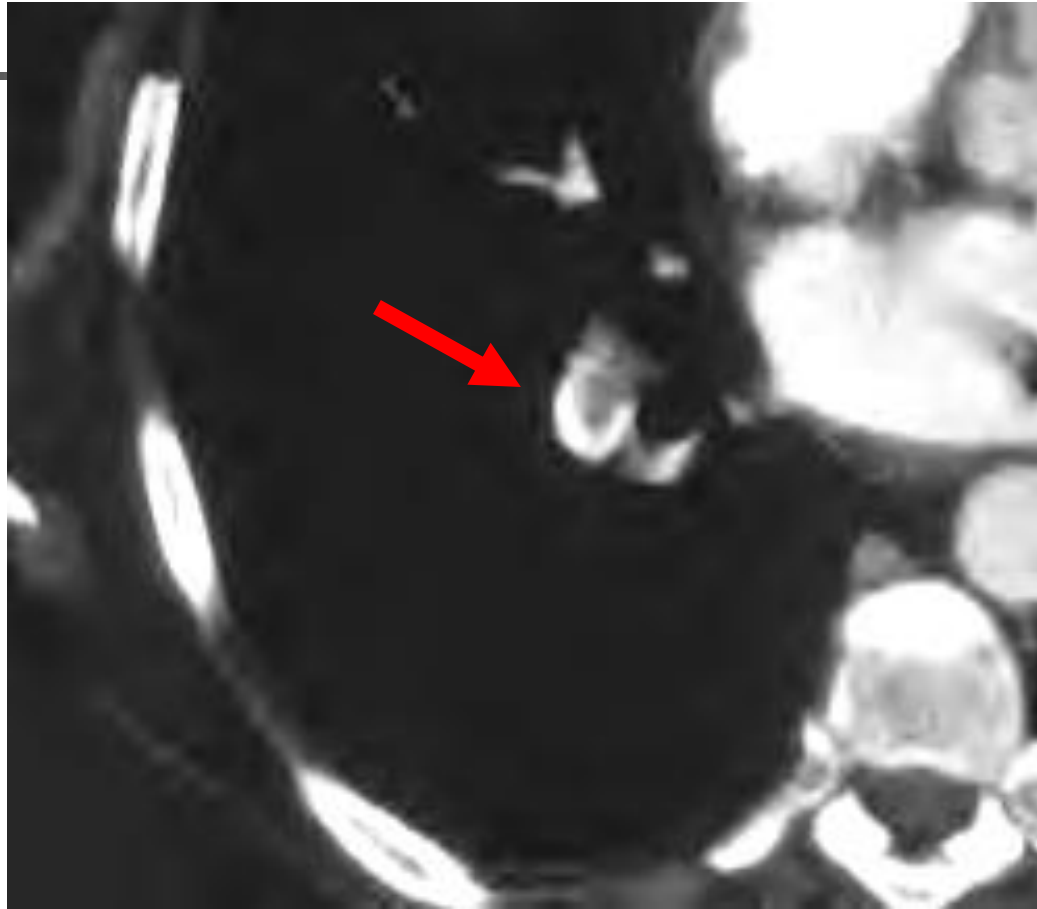Spiral CT for Dx PE



Spiral
CT for
Dx
PE



Pulmonary Embolism by CT



Pulmonary Angiogram



- Most specific test available for diagnosis of PE
- Can detect emboli as small as 1-2 mm
- Most useful when the clinical likelihood of PE differs substantially from the lung scan or CTPA results

Pulmonary Angiography

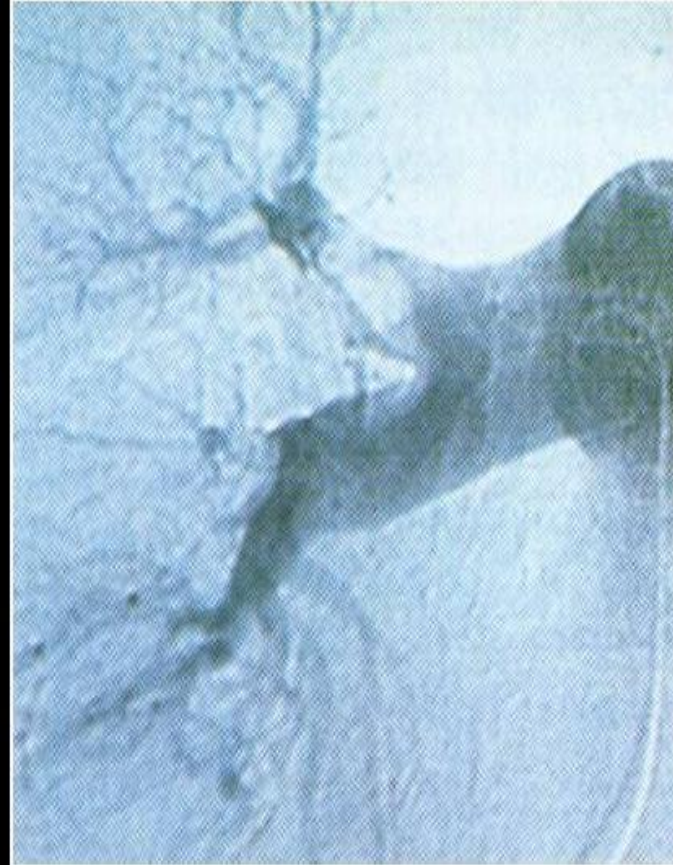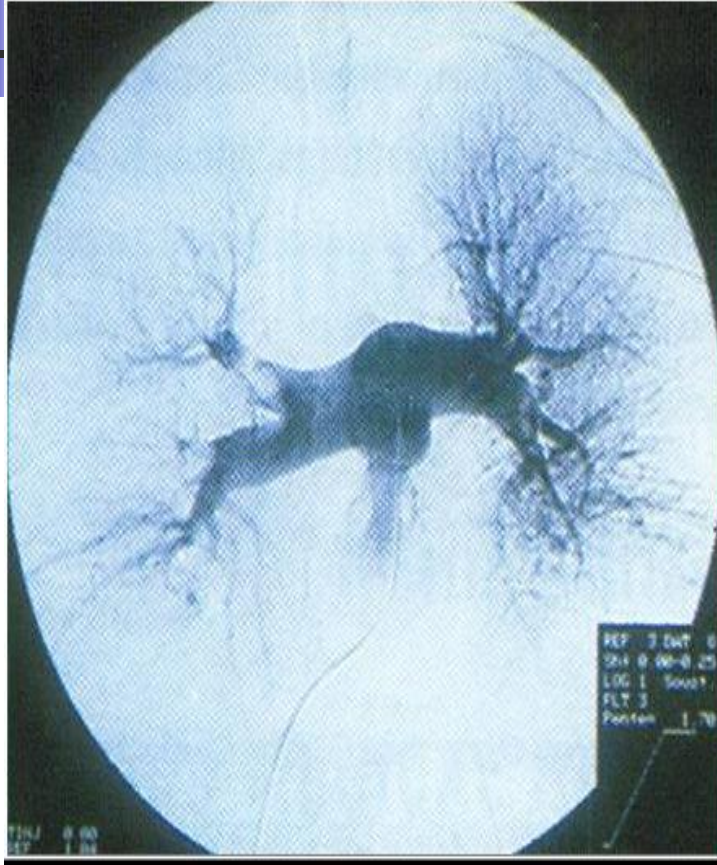
Diagnostic Findings

0.5 % Mortality

1 % Major Morbidity

Diagnostic Findings	
	Intraluminal filling defects
	Vascular Cutoffs

Pulmonary angiogram





Initial Treatment of Pulmonary Embolism

- Anticoagulant treatment should be administered to all patients with high or intermediate clinical probability of acute PE, without awaiting definitive confirmation by imaging procedures.



Initial Treatment of Pulmonary Embolism

- Unfractionated heparin is the preferred mode of initial anticoagulation for patients with severe renal impairment (creatinine clearance $<20\text{--}30$ mL/min)
- for those at high risk of bleeding
- for high-risk hypotensive patients
- as a rule, for extremely overweight, underweight, or old patients



Initial Treatment of Pulmonary Embolism

- With the exception of these circumstances
- LMWH or fondaparinux is given subcutaneously at weight-adjusted doses
- Anticoagulation with unfractionated heparin or LMWH/fondaparinux should be continued for at least 5 days



Antithrombotic Therapy for VTE Disease: CHEST Guideline and Expert Panel Report

***Chest.* 2016;149(2):315-352.**



Initial Treatment of Pulmonary Embolism

- Oral anticoagulants (vitamin K antagonists) should be initiated as soon as possible in hemodynamically stable patients, preferably on the same day as heparin
- Parenteral anticoagulation can be stopped as soon as the international normalized ratio (INR) has been in the therapeutic range (between 2.0 and 3.0) on 2 consecutive days.



For VTE and no cancer, as long-term anticoagulant therapy

- we suggest
 - dabigatran (Grade 2B) Pradaxa
 - rivaroxaban (Grade 2B) Xarelto
 - apixaban (Grade 2B), or Eliquis
 - edoxaban (Grade 2B) Savaysa
 - over vitamin K antagonist (VKA) therapy,




For VTE and Cancer as long-term anticoagulant therapy

- we suggest LMWH over VKA (Grade 2B),
 - dabigatran (Grade 2C)
 - rivaroxaban (Grade 2C)
 - apixaban (Grade 2C), or
 - edoxaban (Grade 2C).



Initial Therapy

- Initial parenteral anticoagulation is given before dabigatran (Pradaxa) and edoxaban (Savaysa), is not given before rivaroxaban (Xarelto) and apixaban (Eliquis), and is overlapped with VKA therapy.



First VTE that is an unprovoked proximal DVT of the leg or PE and who have a (i) low or moderate bleeding risk

- We suggest extended anticoagulant therapy (no scheduled stop date) over 3 months of therapy (Grade 2B),
- For high bleeding risk we recommend 3 months of anticoagulant therapy over extended therapy (no scheduled stop date)

Proximal DVT of the leg or PE provoked by surgery



- We recommend treatment with anticoagulation for 3 months over (i) treatment of a shorter period (Grade 1B), (ii) treatment of a longer time-limited period (eg, 6, 12, or 24 months) (Grade 1B), or (iii) extended therapy (no scheduled stop date) (Grade 1B).



Proximal DVT of the leg or PE provoked by a nonsurgical transient risk factor

- We recommend treatment with anticoagulation for 3 months over (i) treatment of a shorter period (Grade 1B) and (ii) treatment of a longer time-limited period (eg, 6, 12, or 24 months) (Grade 1B).



Outpatient Tx for PE

- Normotensive patients without serious comorbidity or signs of (right) heart failure belong to a low-risk group which could be treated out of hospital.

Davies CW, et al. Early discharge of patients with pulmonary embolism: a two-phase observational study. *Eur Respir J* 2007;30:708–714.

Zondag W, et al. Outpatient treatment in patients with acute pulmonary embolism: the Hestia Study. *J Thromb Haemost* 2011;9:1500–1507.

Agterof MJ, et al. Out of hospital treatment of acute pulmonary embolism in patients with a low NT-proBNP level. *J Thromb Haemost* 2010;8:1235–1241



Outpatient Tx for PE

- A randomized study reported that low-risk patients as defined by the PE severity index can safely be discharged within 24 h and treated as outpatients.

Aujesky D, et al. Outpatient versus inpatient treatment for patients with acute pulmonary embolism: an international, open-label, randomised, non-inferiority trial. *Lancet* 2011;378:41–48.



Other Approved Oral Agents

- Apixaban (Eliquis)
 - 10 mg PO BID for 7 days then 5 mg BID

- Dabigatran (Pradaxa)
 - 150 mg PO BID
 - 75 mg PO BID for renal disease patients



Other Approved Oral Agents

- Edoxaban (Savaysa)
 - 60 mg PO once daily
 - 30 mg PO daily with renal disease



Problems

- If bleeding occurs – no reversal agents at present
- Cost



Duration of Anticoagulation

- Patients who have pulmonary embolism and preexisting irreversible risk factors, such as deficiency of antithrombin III, protein S and C, factor V Leiden mutation, or the presence of antiphospholipid antibodies, should be placed on long-term anticoagulation.



Thrombolytic Therapy

- Thrombolytic therapy is clearly indicated for hemodynamically unstable patient who lack contraindication
- In only one randomized thrombolysis trial with clinical endpoints, early thrombolytic treatment given to normotensive patients with evidence of RV dysfunction significantly reduced the need for emergency escalation of therapy during the hospital stay

Konstantinides S, et al. Heparin plus alteplase compared with heparin alone in patients with submassive pulmonary embolism. *N Engl J Med* 2002;347:1143–1150.



Thrombolytic Therapy

- Overall, >90% of patients with PE appear to respond favourably to thrombolysis as indicated by clinical and echocardiographic improvement within the first 36 h.
- The greatest benefit is observed when treatment is initiated within 48 h of symptom onset, but thrombolysis can still be useful in patients who have had symptoms for 6–14 days.

Meneveau N, et al. Management of unsuccessful thrombolysis in acute massive pulmonary embolism. *Chest* 2006;129:1043–1050.

Daniels LB, et al. Relation of duration of symptoms with response to thrombolytic therapy in pulmonary embolism. *Am J Cardiol* 1997;80:184–188.

Thrombolysis for pulmonary embolism

Agents and regimens

Streptokinase^a

250 000 U as a loading dose over 30 min, followed by
100 000 U/h over 12–24 h

Accelerated regimen: 1.5 million IU over 2 h^b

Urokinase^{a,c}

4400 U per kg of body weight as a loading dose over
10 min, followed by 4400 U/kg/h over 12–24 h

Accelerated regimen: 3 million U over 2 h^b

Alteplase^a

100 mg over 2 h^d

Accelerated regimen: 0.6 mg/kg for 15 min

Retepase^{a,e}

Two bolus injections of 10 U 30 min apart

Tenecteplase^f

30–50 mg bolus for 5–10 s adjusted for body weight

<60 kg	30 mg
≥60 to <70 kg	35 mg
≥70 to <80 kg	40 mg
≥80 to <90 kg	45 mg
≥90 kg	50 mg

Contraindications

Absolute

- History of haemorrhagic stroke or stroke of unknown origin
- Ischaemic stroke in previous 6 months
- Central nervous system neoplasms
- Major trauma, surgery, or head injury in previous 3 weeks

Relative

- Transient ischaemic attack in previous 6 months
- Oral anticoagulation
- Pregnancy or first postpartum week
- Non-compressible puncture sites
- Traumatic resuscitation
- Refractory hypertension (systolic blood pressure >180 mmHg)
- Advanced liver disease
- Infective endocarditis
- Active peptic ulcer

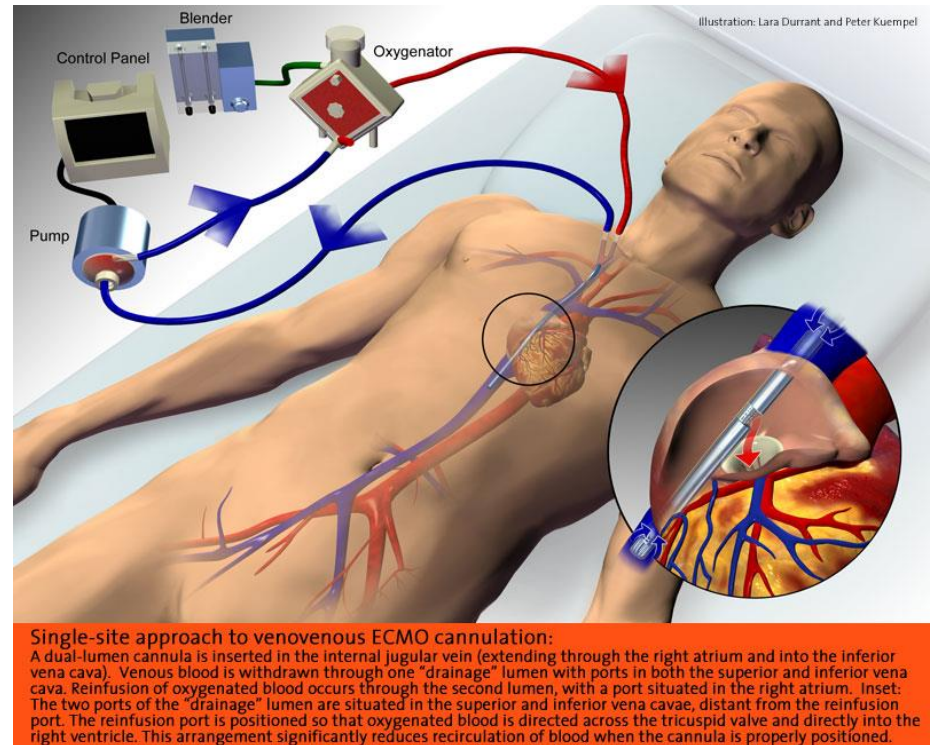
Indications for Vena Caval *Interruption*



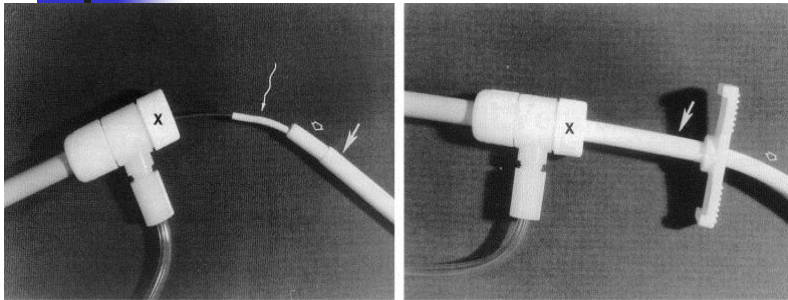
- 1.** Contraindication to anticoagulation
- 2.** Recurrent emboli on adequate Tx
- 3.** Serious bleeding on anticoagulation
- 4.** Massive pulmonary embolism
- 5.** Psychosocial reasons

Surgical Treatment

- **Pulmonary embolectomy is a recommended therapeutic option in patients with high-risk PE in whom there are absolute contraindications to thrombolysis, or if thrombolysis has failed.[5,53]**
- **Recent technical advances in transportable extracorporeal assist systems, and particularly the timely early involvement of the cardiac surgeon as part of an interdisciplinary approach to high-risk PE before haemodynamic collapse, have contributed to improved postoperative outcomes and case fatality rates as low as 23%.[58]**

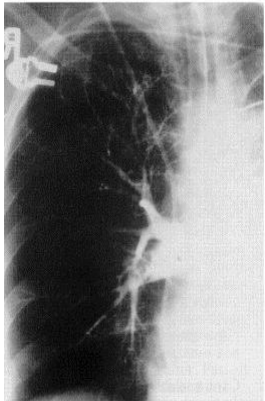


Interventional Treatment

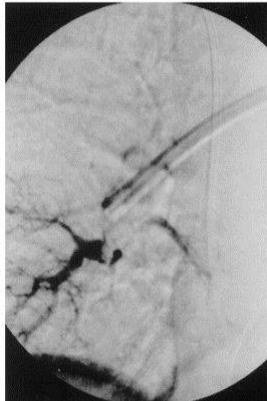

a.

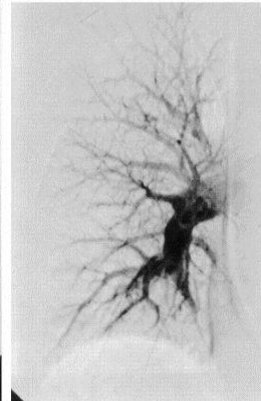
b.



c.



d.



e.

In case of absolute contraindications to thrombolysis:

thrombus
fragmentation
rheolytic
thrombectomy
suction thrombectomy
rotational

Catheter-Directed Embolectomy, Fragmentation, and Thrombolysis for the Treatment of Massive Pulmonary Embolism After Failure of Systemic Thrombolysis*

CHEST. 2008;134(2):250-254. doi:10.1378/chest.07-2846

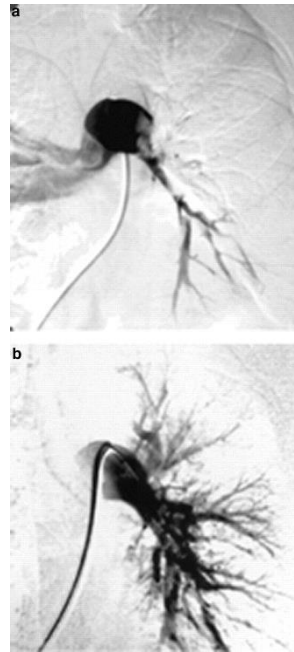


Figure Legend:

A 57-year-old woman presented in extremis from massive bilateral PE. The patient was referred to the Interventional Radiology Department when there was no response to IV infusion of 100 mg of tPA. Both lungs were treated emergently with CDI, including 20 mg of local TNK. Pulmonary angiograms of the left lung, before and after CDI, are shown. Top, a: left pulmonary angiogram demonstrates a persistent massive PE, despite treatment with systemic TPA, and flow into the left lung is severely compromised. Bottom, b: following CDI, left lung perfusion is improved. Similar maneuvers were performed in the right lung (not shown) with good results and resolution of shock. Reproduced with permission from Sze et al.¹³



**"Hmmm... Sounds grave, very grave.
We'll know more after the autopsy!"**