

Lung Cancer and Paraneoplastic Syndromes

Amita Vasoya D.O., FACOI, FCCP, FAASM
Christiana Care Pulmonary Associates
Clinical Assistant Professor-
Rowan University-School of Osteopathic Medicine
ACOI Board Review 2017

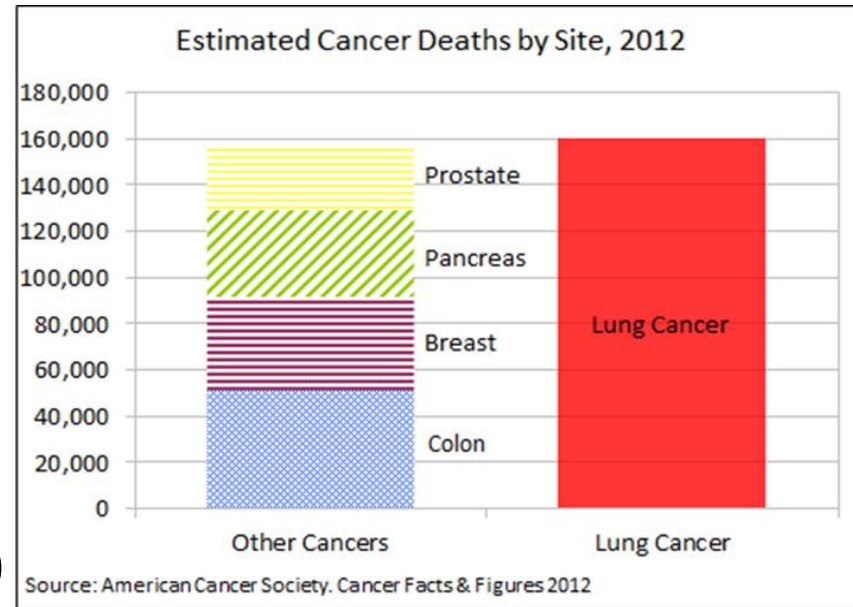


Disclosures

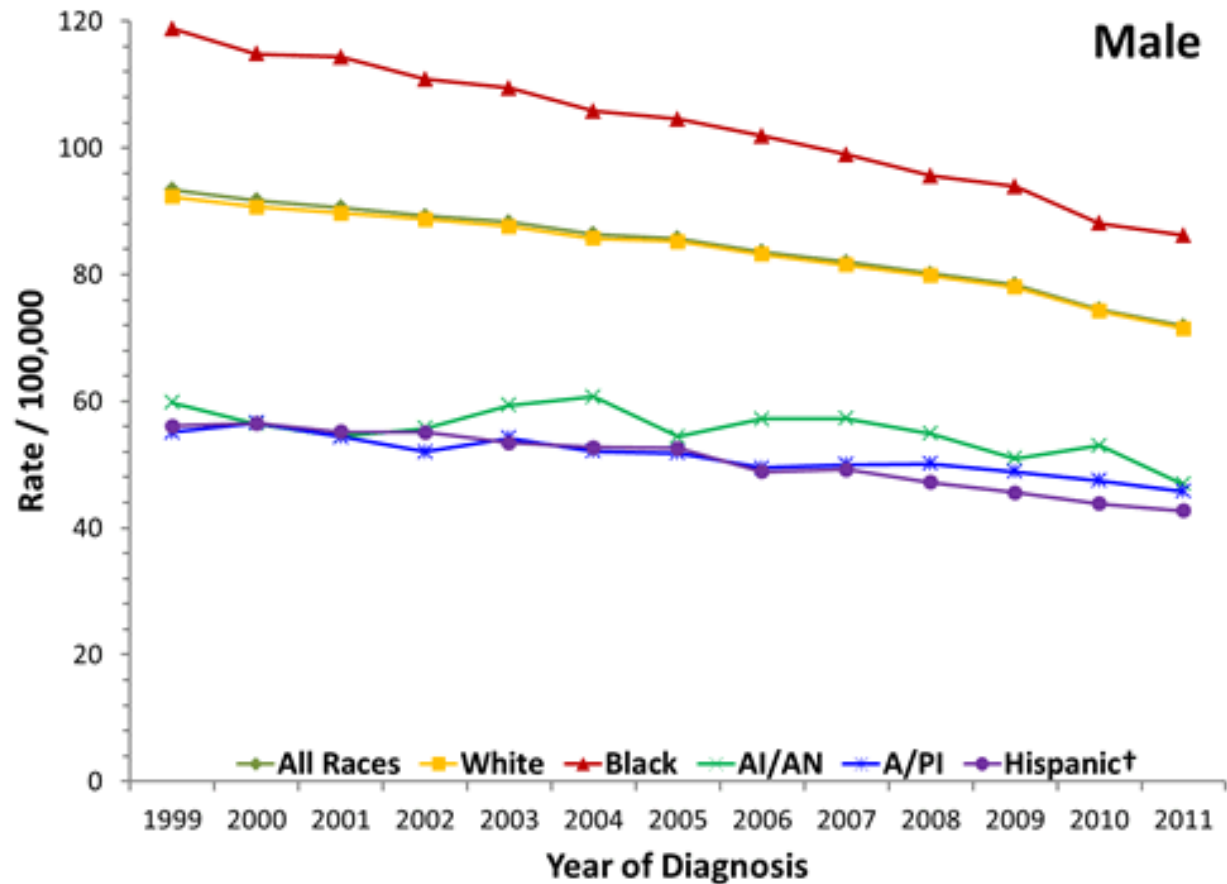
- None

Introduction

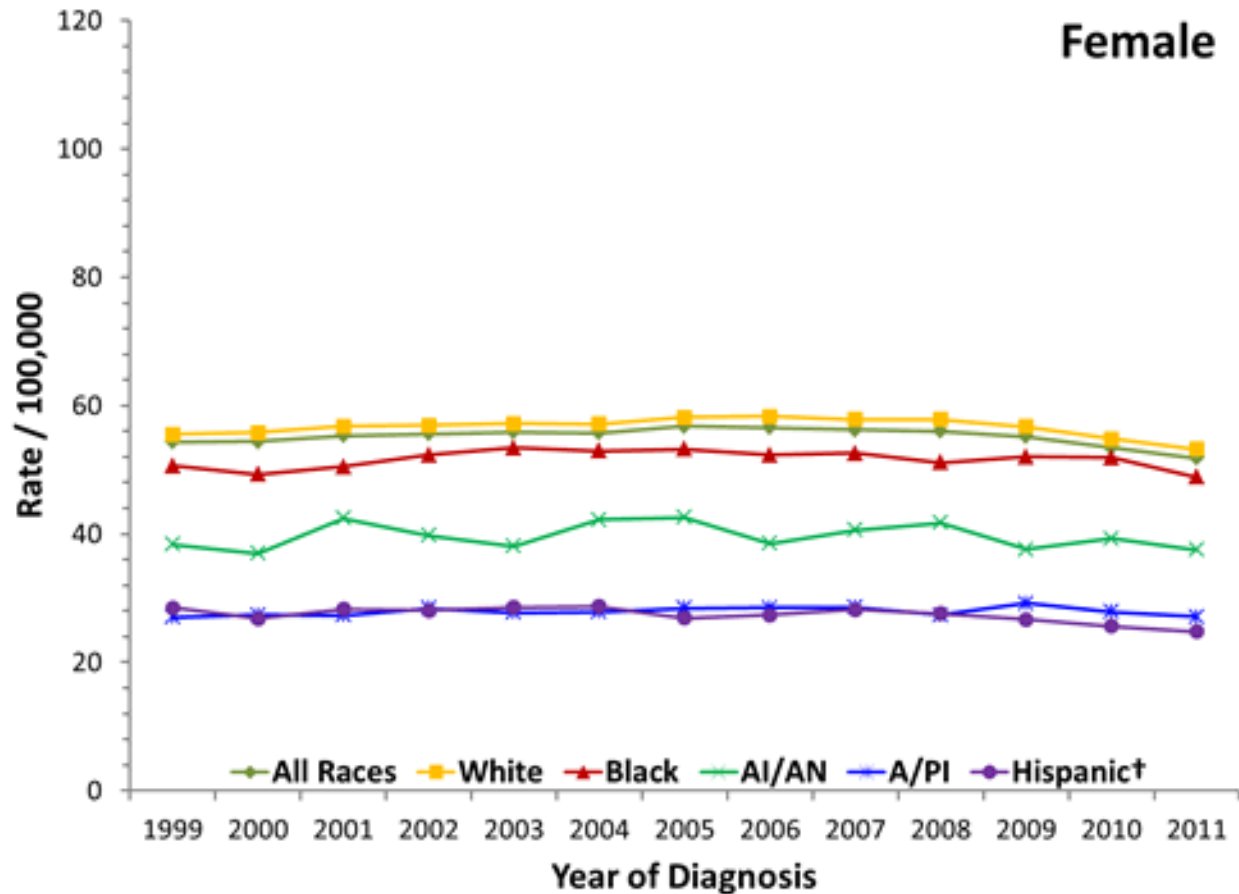
- Lung cancer is the most common cause of mortality **WORLDWIDE**
- 1.3 million deaths per year
- In U.S. 2012: 226,000 new cases



Incidence



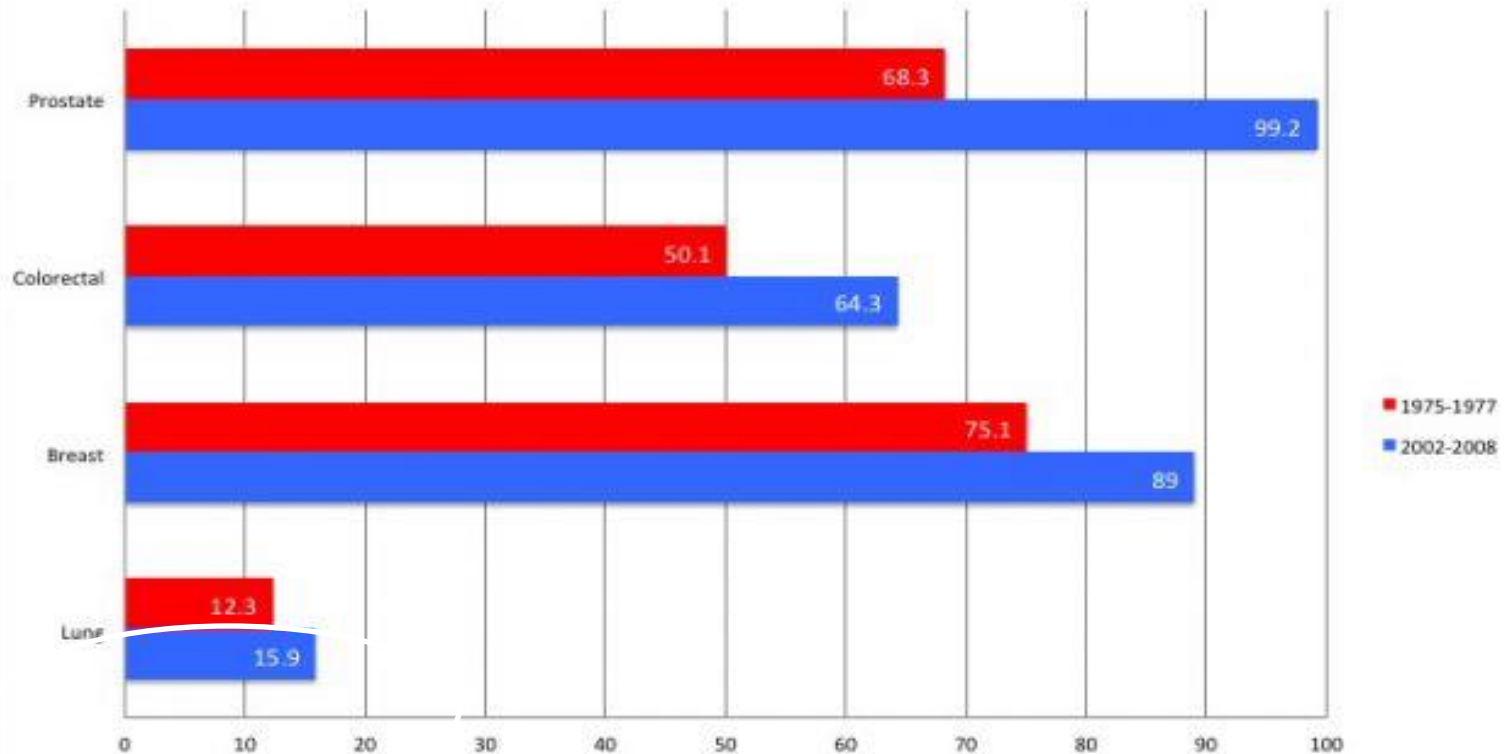
Incidence



5 year Survival Rates

Cancer Survival Rates

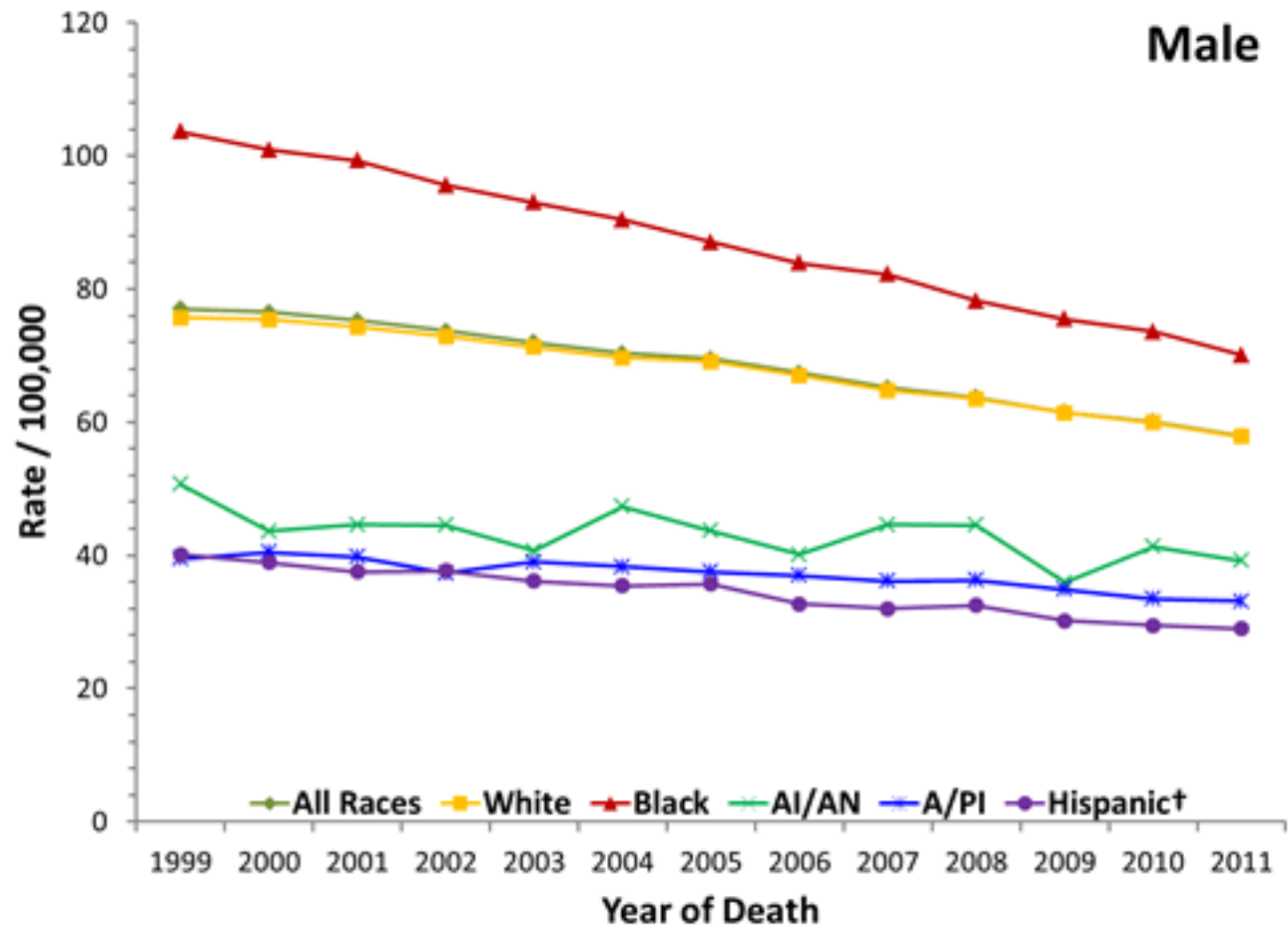
The percentage of patients still alive five years after diagnosis, as seen below, has improved. But survival rates for lung cancer remain far lower for lung cancer patients than for patients with other cancers.



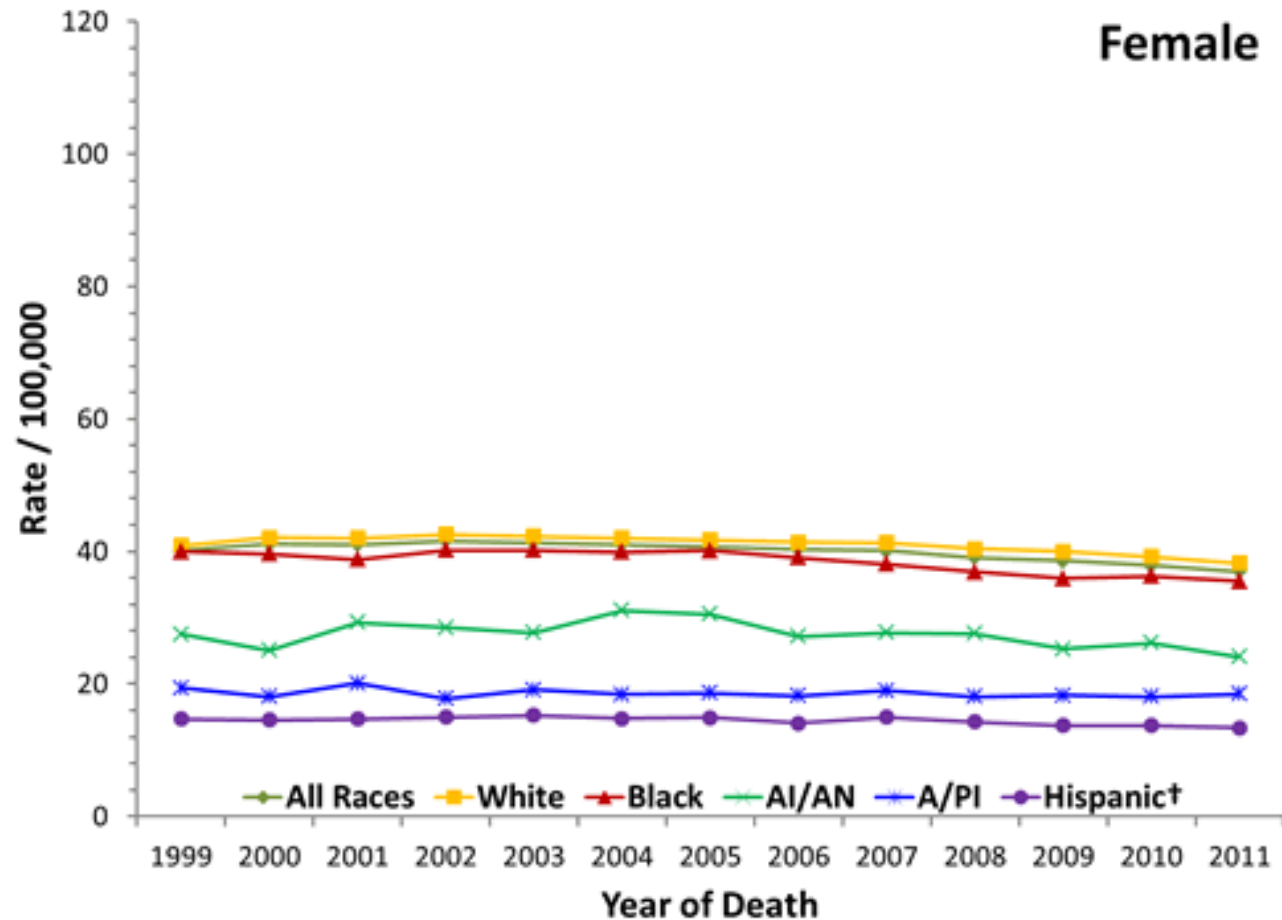
Note: 2002-2008 figures reflect data from regions of U.S. with 28% of total population, while 1975-1977 data is drawn from regions with 9.5% of U.S. population. Survival rates include diagnoses at all stages.

Source: National Cancer Institute

Death Rate

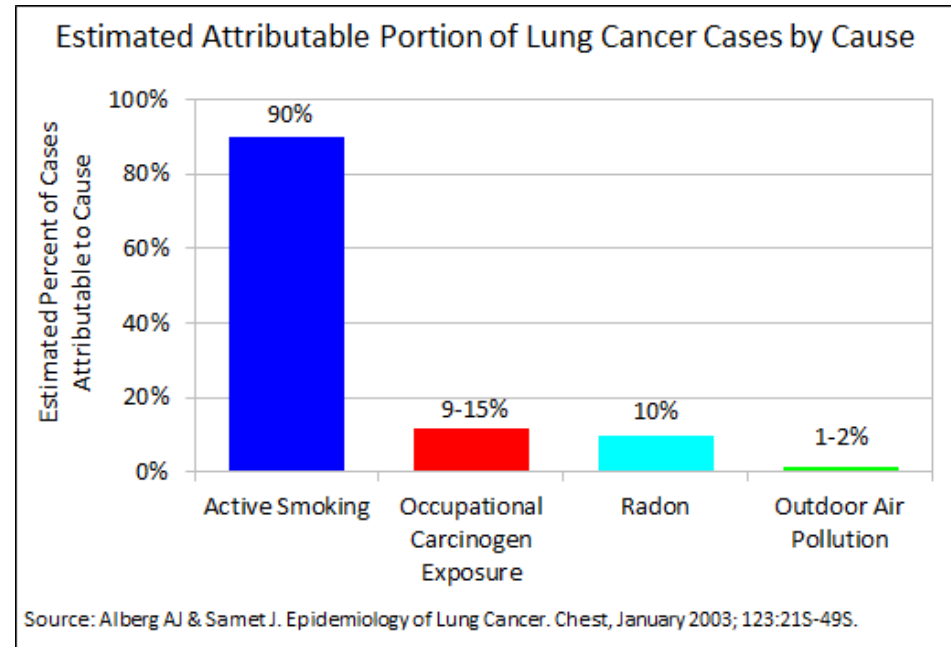


Death Rate



Risk Factors

- **SMOKING**
- Environmental
 - Radon
 - Air pollution
 - Metals
- Asbestos
- Genetics
- HIV
- Pulmonary Fibrosis
- Radiation therapy



Lung Cancer

- Encompasses all tumors which arise from the bronchi, bronchioles, alveoli, and other respiratory epithelium
- Mesotheliomas, lymphomas, and sarcomas are distinct from the epithelial derived cancers

Lung Cancer

- Primary
 - Bronchogenic
 - Carcinoid
 - Adenoid Cystic Carcinoma
 - Mucoepidermoid
- Soft Tissue
 - Sarcoma
- Metastatic

Primary Lung Cancer: Bronchogenic Carcinoma

- Small Cell
 - Classic small Cell
 - Large Cell
 - Neuroendocrine
 - Combined
- Non Small Cell
 - Squamous
 - Adenocarcinoma
 - “Bronchoalveolar cell”
 - Atypical adenomatous hyperplasia (AAH)
 - Adenocarcinoma in-situ (AIS)
 - Minimally invasive adenocarcinoma
 - Large Cell

Lung Cancer

- According to the WHO classification 88% of all primary lung neoplasms are made up of 4 different cell types
 - Small cell (Oat cell)
 - 20%
 - Squamous (Epidermoid)
 - 20-30%
 - Adenocarcinoma (Bronchioalveolar)
 - 30-40%
 - Large cell (Large cell)
 - 10%

Small Cell Lung Cancer

- Classic features:
 - Usually Central
 - 2/3 perihilar/hilar
 - 1/6 in main bronchus, 1/6 peripheral or apical
 - Most aggressive of all tumors with rapid doubling time
 - Early metastases (nearly 70% metastatic at presentation)
 - Liver 30-35%
 - Bone 40-50%
 - CNS 15%
 - Strongest association: Tobacco Use
 - Early response to therapy (chemo and radiation) but eventually becomes refractory

Small Cell Staging

- **Limited Stage**

- 30% of patients at presentation
- Confined to one hemithorax
- **Survival:**
 - Median survival is 15-20 months
 - 5 year ~ 10-15%

- **Extensive Stage**

- 70 % of patients at presentation
- Extends beyond one hemithorax
- **Survival:**
 - Median survival is 8-13 months
 - 5 year ~ 1-2%

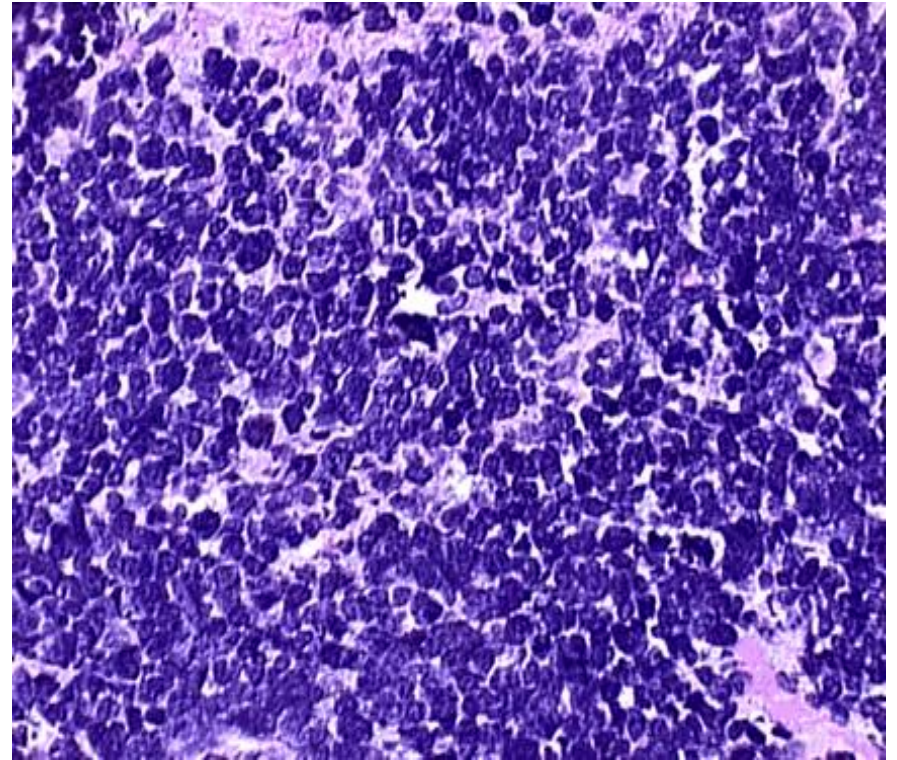
Median survival without treatment is 2-4 months

Small Cell Lung Cancer

- Paraneoplastic syndromes
 - Ectopic ADH, ACTH
 - Lambert Eaton
- Treatment
 - Chemotherapy, XRT
 - Prophylactic cranial irradiation if attain complete response with initial treatment
- Survival not related to stage

Small Cell Pathology

- Small blue cells
- Scant cytoplasm
- Nuclear “molding”
- Extensive necrosis
- Cells contain neurosecretory granules

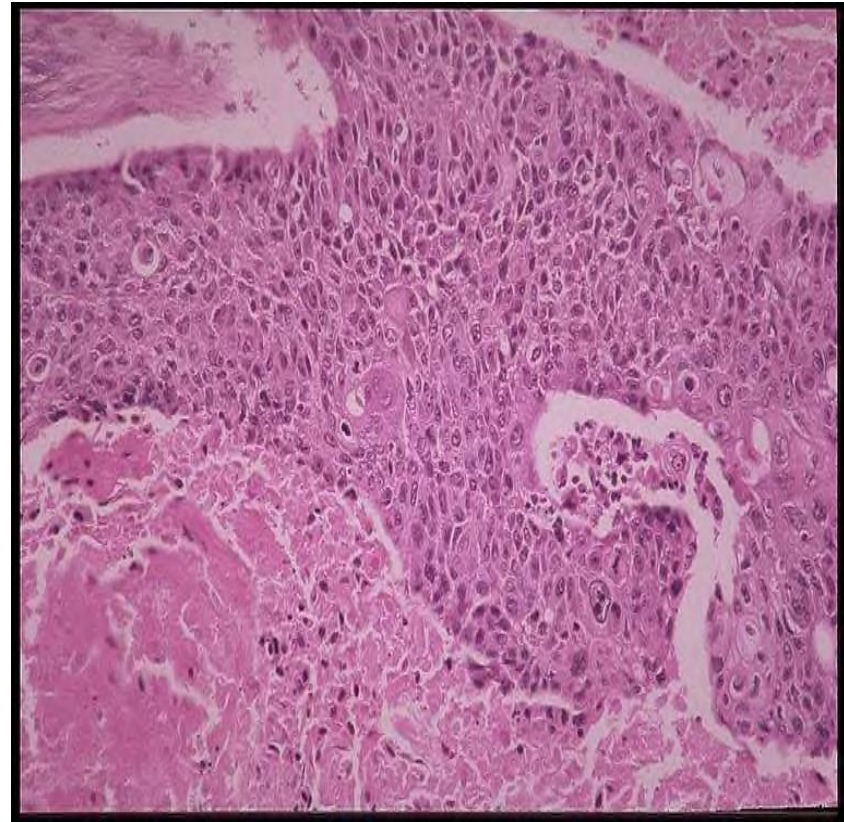


NSCLC: Squamous Cell

- Best prognosis of the major cell types
- Common Presentation:
 - Large central mass
 - Obstructive symptoms/signs,
 - May cavitate 10%
 - Locally invasive, but can metastasize widely
- Intermediate growth rate - late metastasis
- Associated with smoking
- Hypertrophic pulmonary osteoarthropathy (HPOA) is NOT most common with squamous anymore
- Hypercalcemia

Squamous Cell Carcinoma

- Intercellular bridging
- Nesting formation
- Keratinization (well-differentiated type)
- “keratin pearls”



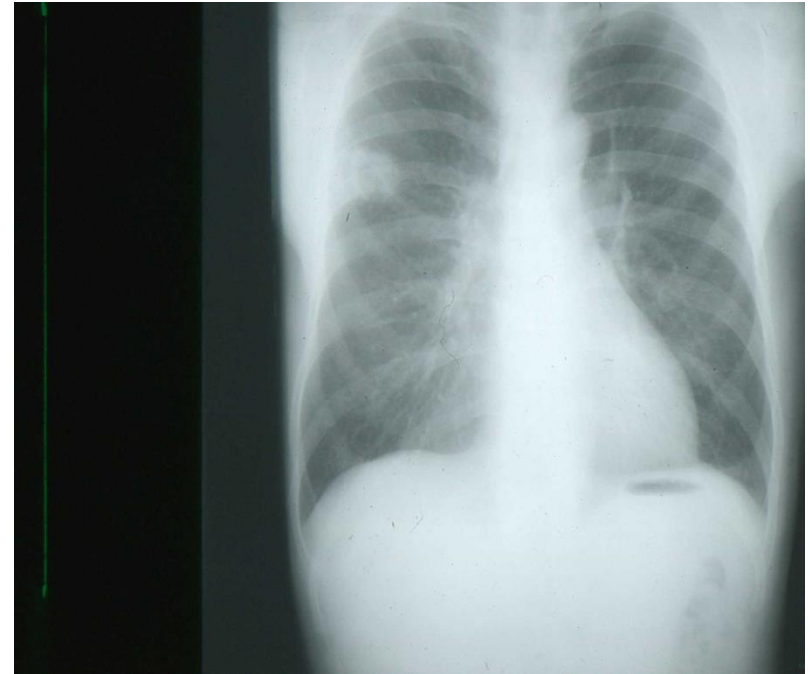
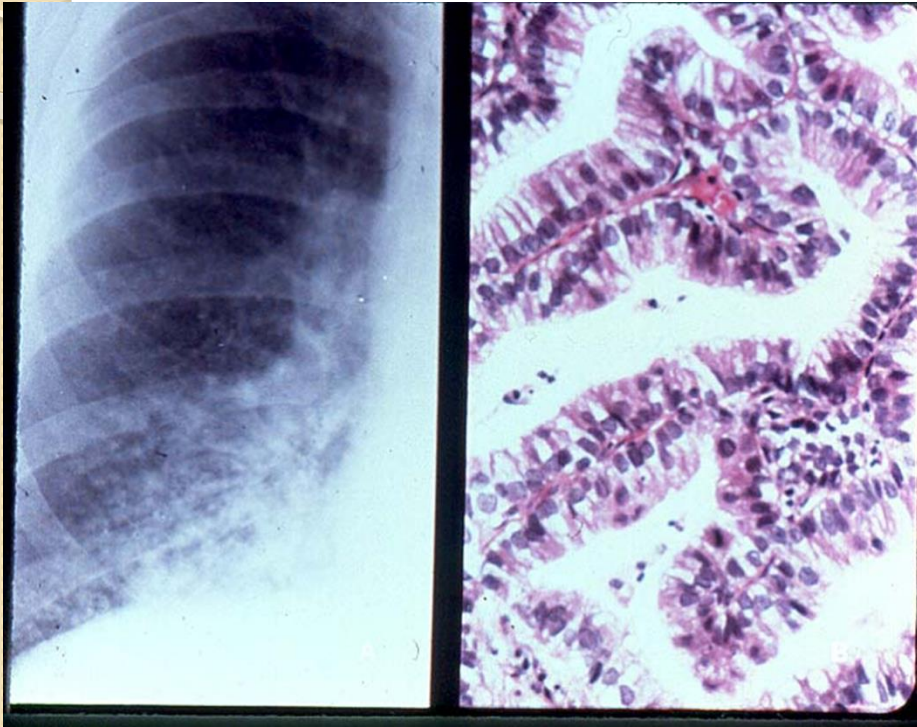
NSCLC: Adenocarcinoma

- Common Presentation
 - Peripheral in location
 - May metastasize widely before symptoms/signs develop
 - Not related to smoking
- Most common type of bronchogenic carcinoma in **NON-SMOKERS**
- Slow growing but invades lymphatics and blood vessels
- May develop in or adjacent to fibrous lung “scar carcinoma”

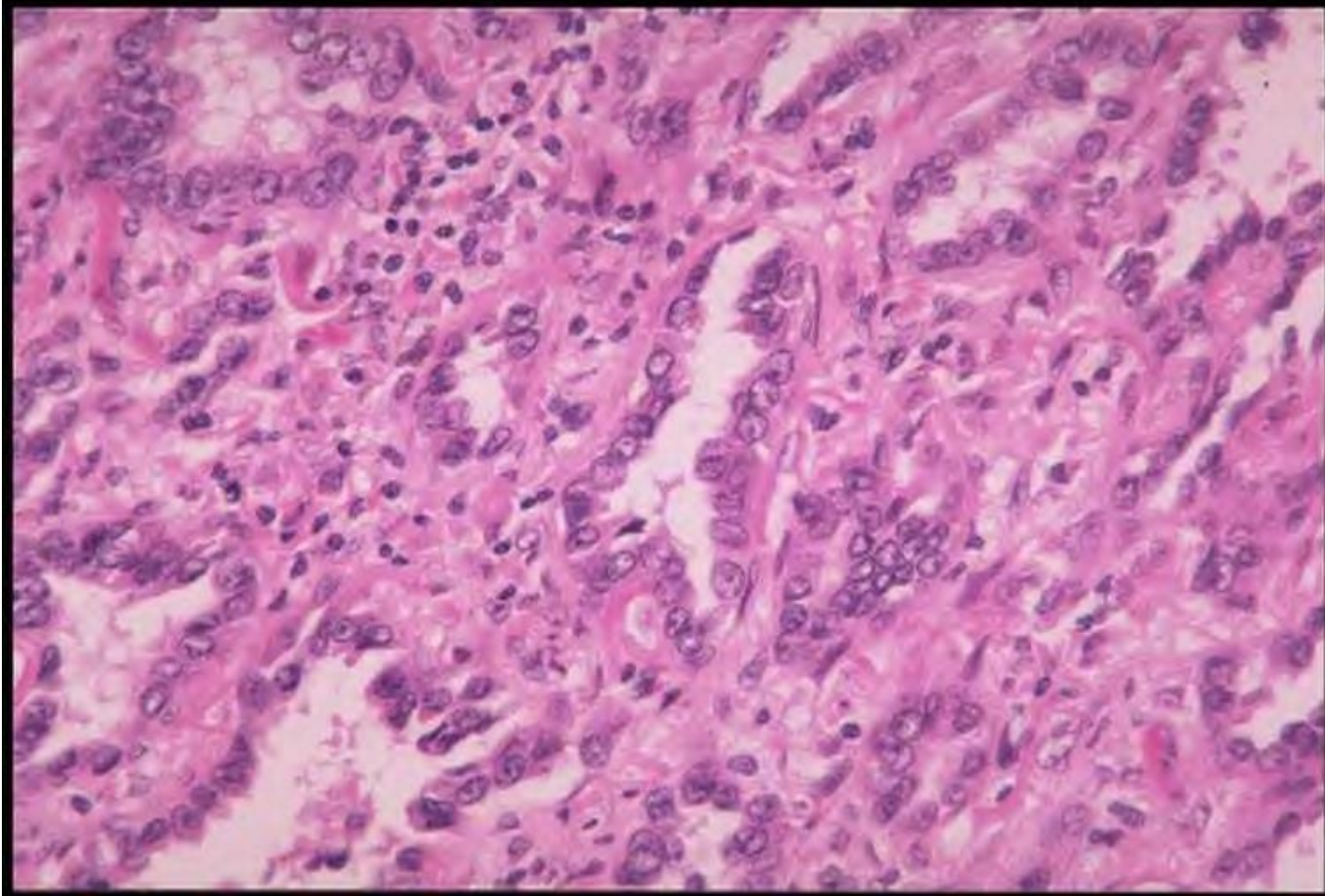
NSCLC: Adenocarcinoma

- Many growth patterns exist: acinar, papillary, bronchioalveolar and solid w/ mucin formation
- Bronchioalveolar carcinoma occurs in the terminal bronchioloalveolar regions
 - Represents 1-9% of all lung carcinomas

NSCLC: Adenocarcinoma



Adenocarcinoma



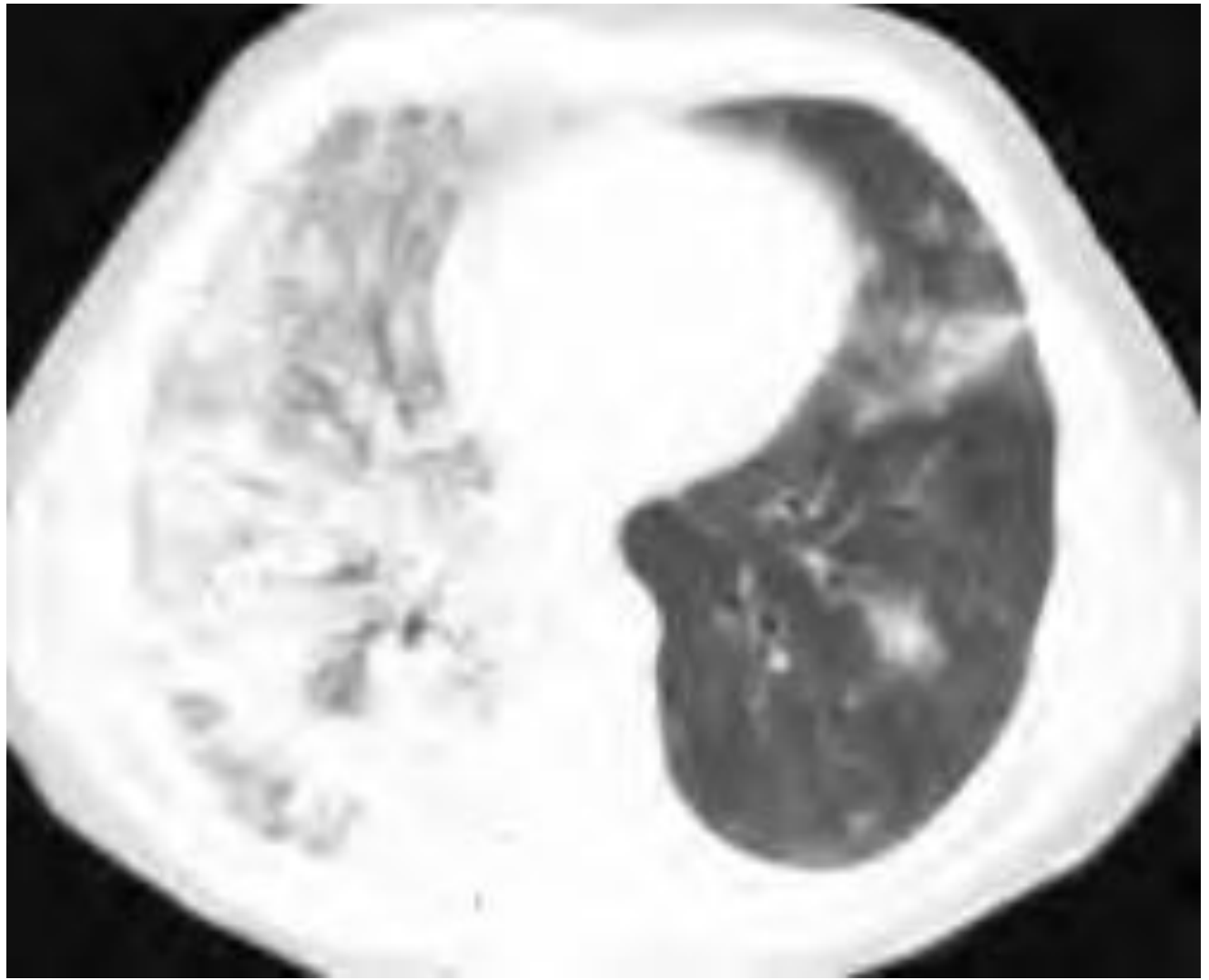
Tumor type	Immunoperoxidase staining
Carcinoma	Epithelial stains (eg, CK 7, 20 variable), EMA (+) CLA, S-100, vimentin (-)
Colorectal carcinoma	CK 7 (-); CK 20 (+)
Lung carcinoma	
Adenocarcinoma	TTF-1 (+), Surf-A and Surf-B (+)
Other non-small-cell carcinoma	CK 7 (+), CK 20 (-), TTF-1 (-)
Small-cell carcinoma	TTF-1 (+), chromogranin (+), NSE (+)
Neuroendocrine carcinoma	NSE, chromogranin, synaptophysin (+), epithelial stains (+)
Germ cell tumor	HCG, AFP (+)
	Oct4 transcription factor (+)
	Placental alkaline phosphatase (+)
	Epithelial stains (+)
Prostate carcinoma	PSA (+), rare false (-) and (+)
	Epithelial stains (+)
	CK 7 (-), CK 20 (-)
Pancreas carcinoma	Ca ¹⁹⁻⁹ (+), CK 7 (+)
	Mesothelin (+), trifoil factor 1 (+)
Breast carcinoma	ER, PR (+)
	Her-2-neu (+)
	CK 7 (+), CK 20 (-)
	Gross cystic fluid protein 15 (+)

NSCLC: Adenocarcinoma In-Situ

- Presentation
 - Usually peripheral
 - Ground glass or infiltrative appearance
 - Can be diffuse, unifocal, or multicentric
 - +/- bronchorrhea
- Tumor may **NOT** invade stroma, pleura, or vasculature
- Lepidic growth
 - Tumor cells line alveolar walls

Invasive Adenocarcinoma

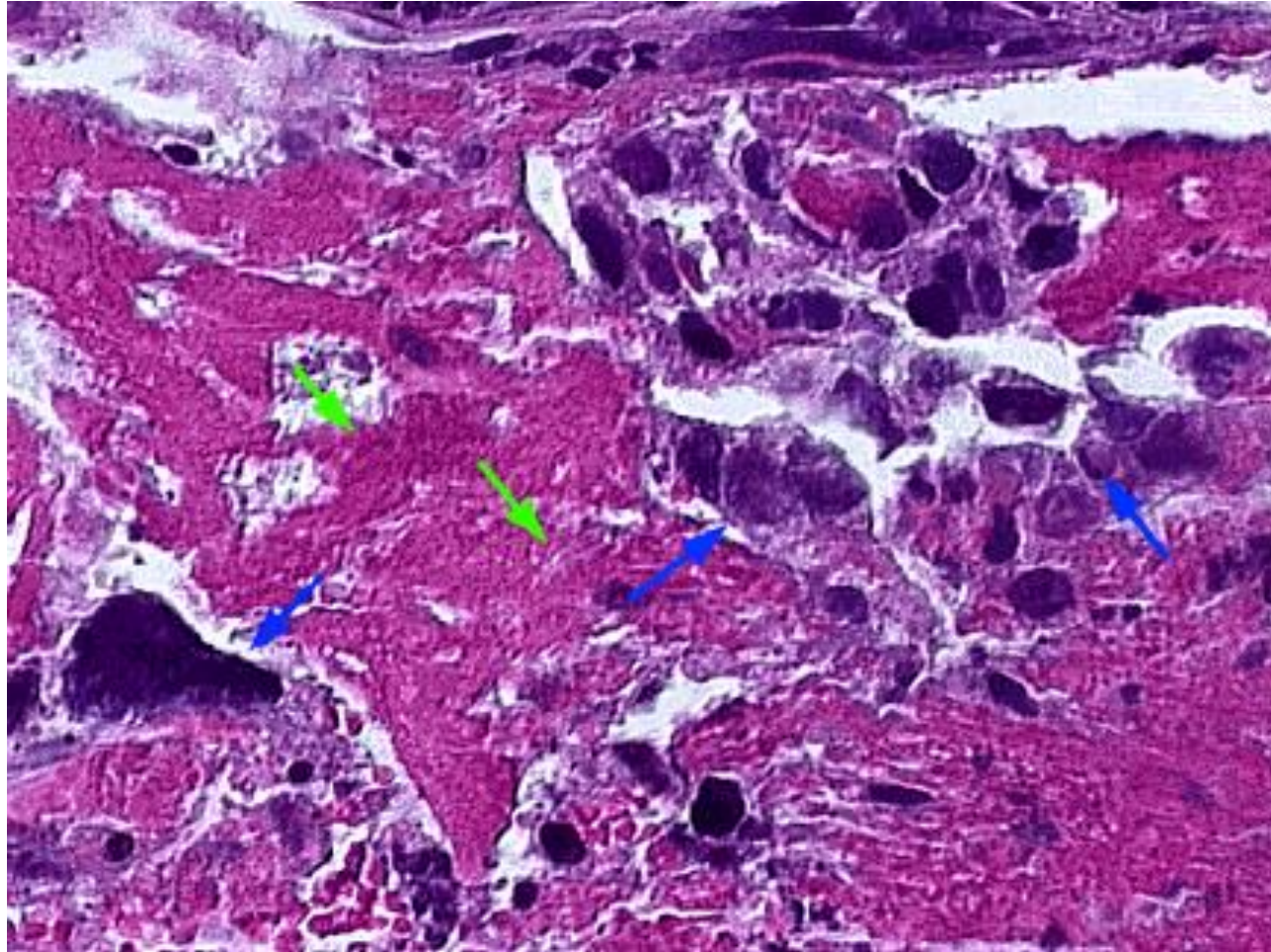
- Subtypes
 - Nonmucinous (lepidic predominant-LPA)
 - Mucinous (invasive mucinous adenocarcinoma)
 - Mixed/Indeterminate (rare)
- Increased risk with tobacco
 - However – 30-40% are non-smokers



NCSLC: Large Cell

- 95% are undifferentiated
- Present as large masses (similar to squamous cell)
- Centrally located
- Fairly uncommon - 3% of all lung cancers
- Rapid Growth / Early metastasis
- Giant Cell variant - even more lethal with mean survival less than 6 months

Large Cell Carcinoma



Lung Cancer: Other types

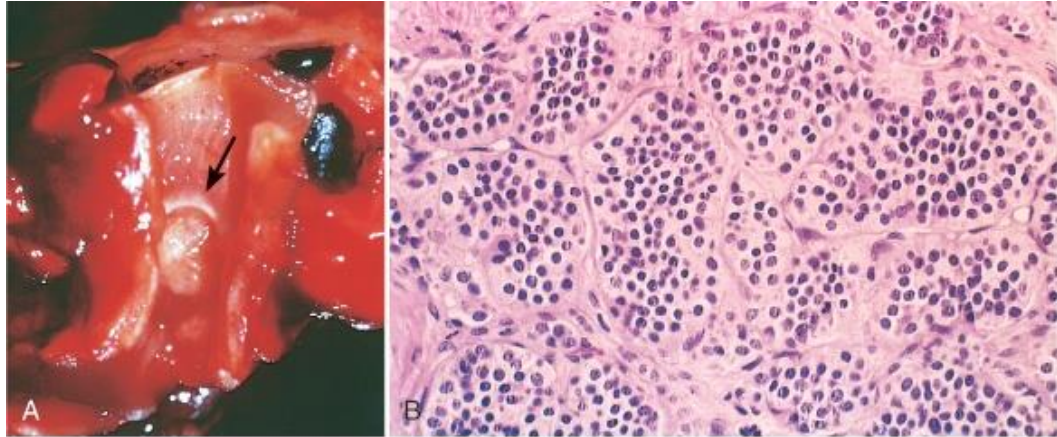
- Undifferentiated carcinoma
- Bronchial gland tumors
 - Adenoid cystic
 - Mucoepidermoid
- Other rare tumors
 - Sarcomatoid carcinoma
 - Carcinoid
 - Typical
 - Atypical
- Preinvasive lesions

Carcinoid (Bronchial Neuroendocrine Tumors)

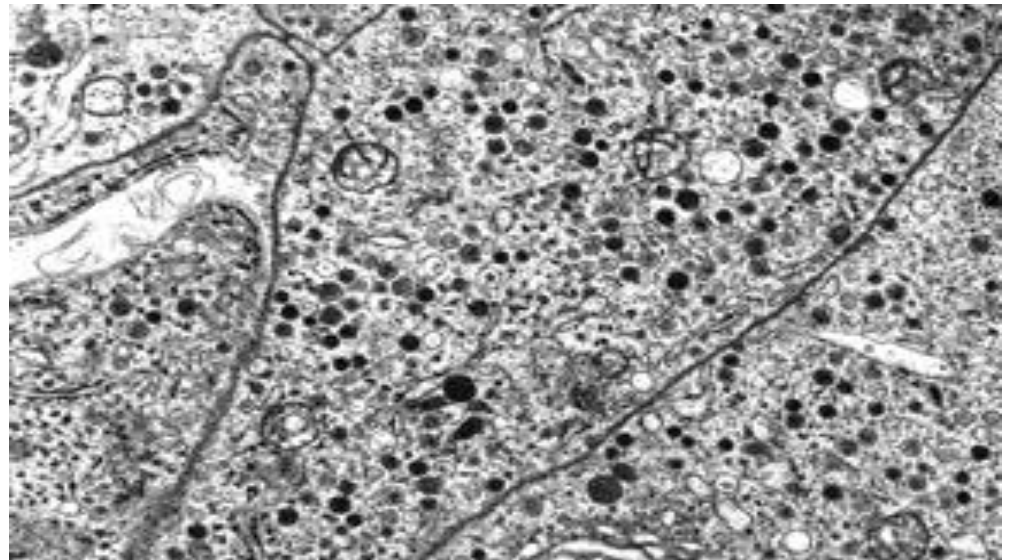
- Neuroendocrine differentiation with relatively indolent clinical behavior
 - GI is most common site, lung is 2nd
- Carcinoid tumors represent 1-5% of all lung tumors
- Patients are usually younger than 40 years of age
- Subclassifications include typical and atypical
 - Typical carcinoid: no p53 mutations or BCL2/BAX imbalance
 - Low grade, well-differentiated, slowly growing tumors
 - Rarely metastasize
 - Often cause endobronchial obstruction
 - Atypical: can see p53 mutations or BCL2/BAX imbalance
 - Intermediate-grade tumors with a higher mitotic rate and or necrosis

Carcinoid

- Carcinoids may arise centrally or peripherally
- Rarely exceed 3-4 cm
- Histologically: organoid, trabecular, palisading, ribbon or rosette-like arrangement
- On electron microscopy, the cells exhibit the dense core granules characteristic of other neuroendocrine tumors

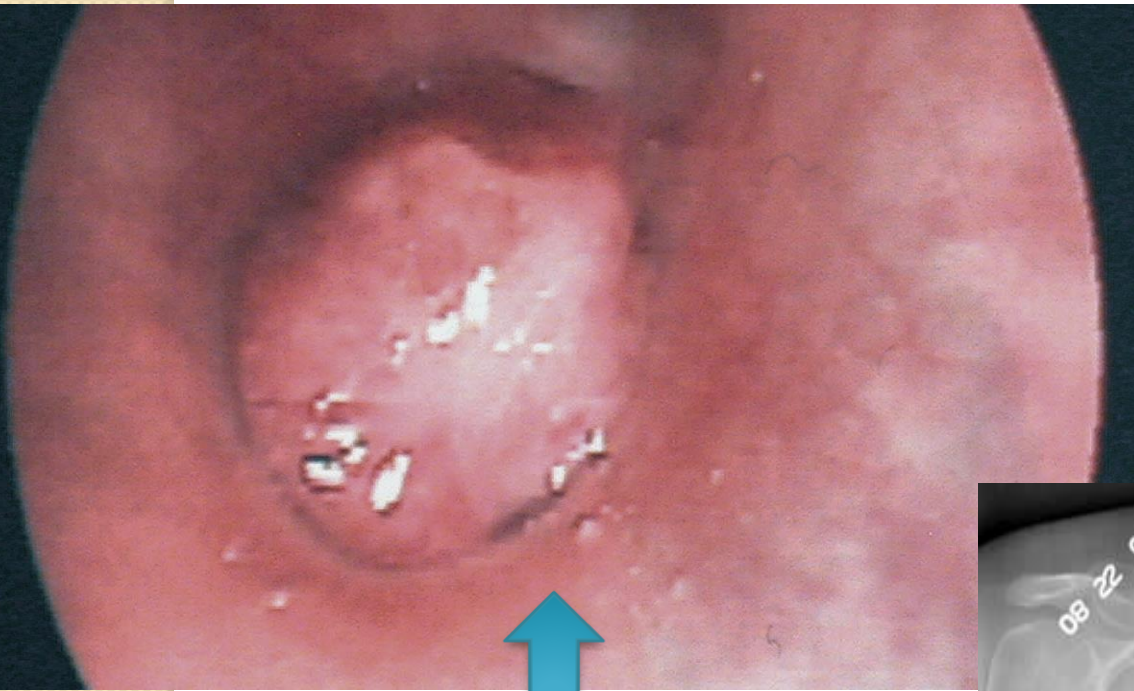


© Elsevier 2005

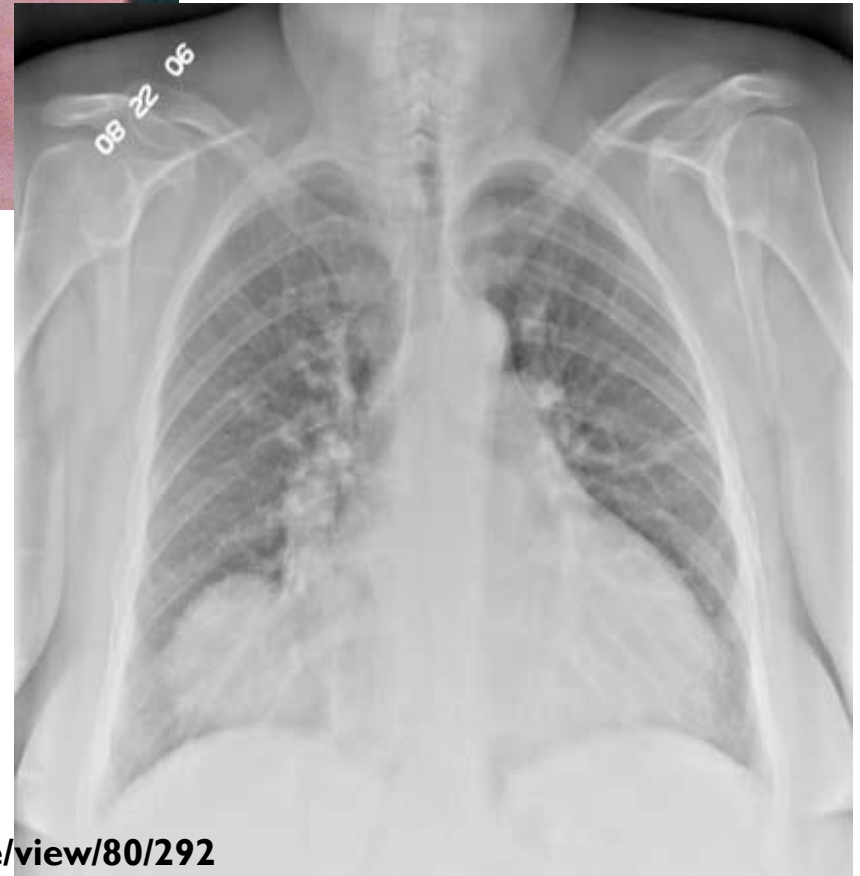


Carcinoid

- Clinical manifestations come from intraluminal growth, capacity to metastasize and the ability of some to elaborate vasoactive amines
- **Most** bronchial carcinoids are non-secretory and do not metastasize
- **Some** are rarely functioning and capable of producing the “carcinoid syndrome” (diarrhea, flushing and cyanosis)
- Patients can develop persistent cough, hemoptysis, secondary infections, bronchiectasis and atelectasis, especially with bronchial obstruction
- Usually amenable to complete resection



Carcinoid tumors are often endobronchial



<http://najms.net/v02i01p017f01h/>

<http://radiology.casereports.net/index.php/rcr/article/view/80/292>

Lung Cancer Facts

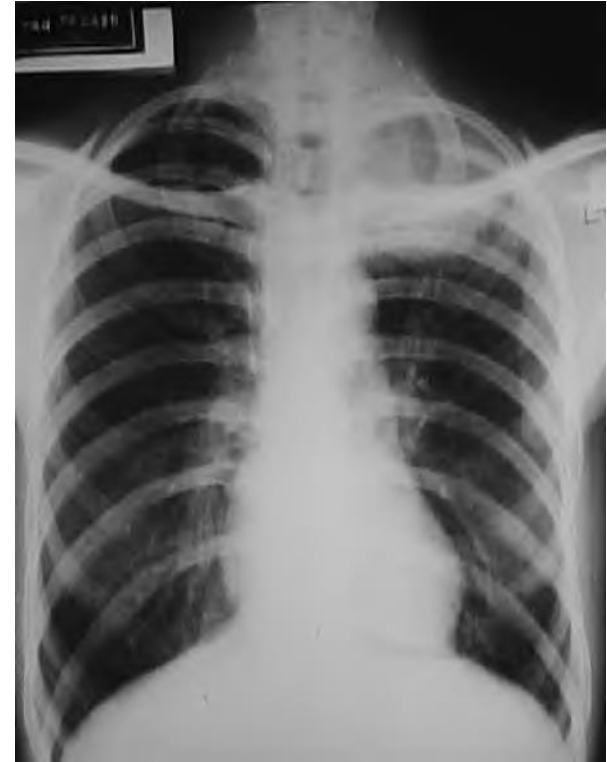- Due to the enormous variance of history and therapeutic response, a correct histological diagnosis is necessary.
- Over the past 25 years adenocarcinoma has become the histological subtype most frequently associated with both sexes and all races combined, replacing squamous cell
- The most common form of lung cancer arising in lifetime nonsmokers, in women, and the young (< 45 years) is Adenocarcinoma

Lung Cancer Facts

- Small cell and epidermoid cancers present as central masses with endobronchial growth
- Adenocarcinomas and large cell cancers present as peripheral nodules/masses, with pleural involvement.
- 10% - 20% of Epidermoid and Large cell cancers cavitate. Squamous cell can cavitate.

Pancoast Syndrome

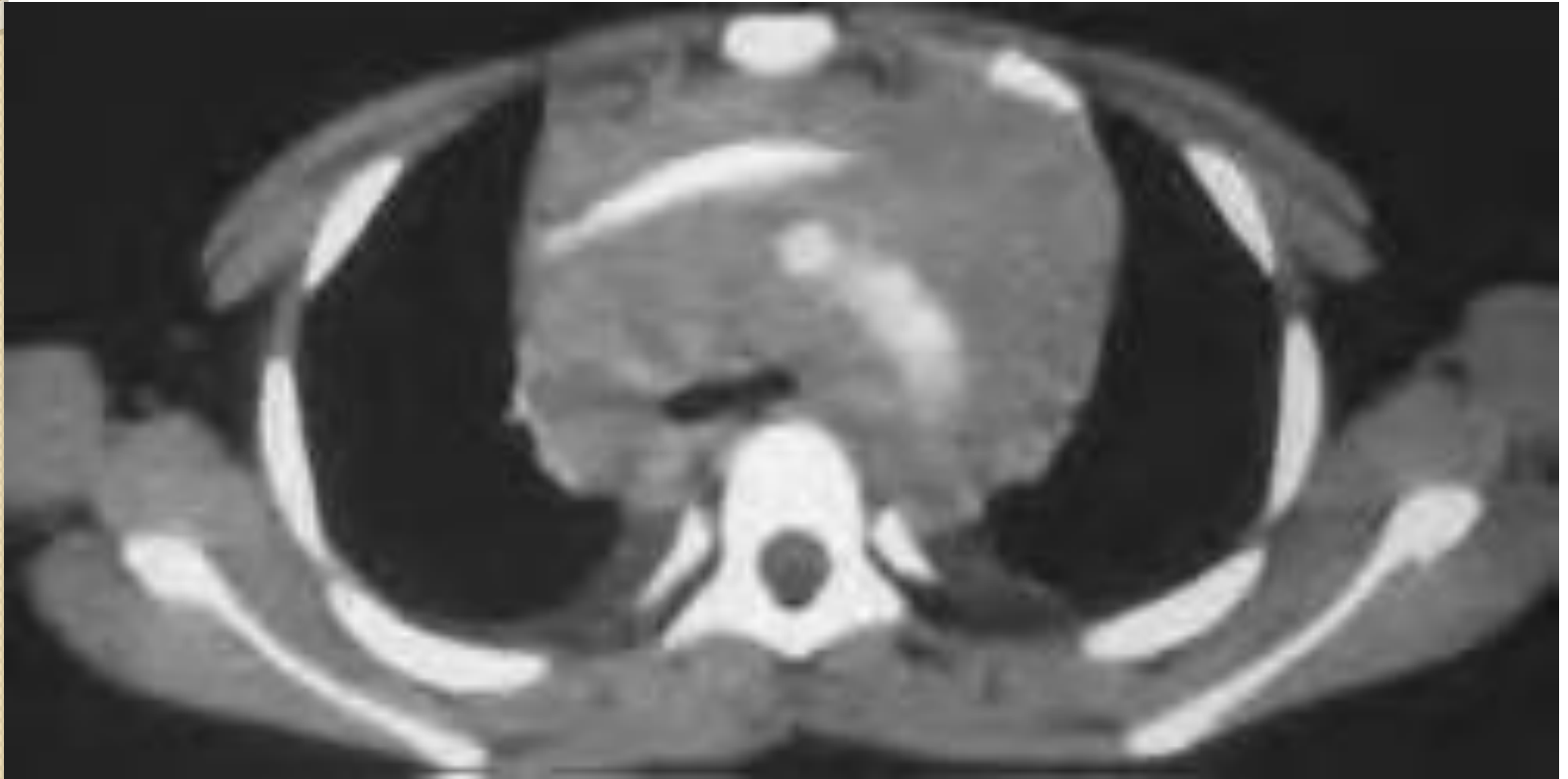
- Superior sulcus tumor
- Horner's syndrome
 - Ptosis
 - Miosis
 - Anhydrosis
- Brachial plexus
- Local erosion of vertebrae



Superior Vena Cava Syndrome

- Over 95% caused by malignancy
 - 5-10% lymphoma
- Histology: predominantly small cell or squamous
- May not be an “emergency” as previously thought
- Approach:
 - establish histologic diagnosis
 - institute therapy promptly (usually XRT)
 - steroids, diuretics, phlebotomy may help

Superior Vena Cava Syndrome



Metastasis

- Every organ system is susceptible to lung cancer metastasis
- Brain metastasis with deficits neurologically
- Bone metastasis with pain and fractures
- Spinal cord compression from bone or epidural metastasis
- Invasion of the marrow with cytopenias
- Liver metastasis causing biliary obstruction
- Lymph node metastasis in supraclavicular region
- Adrenal metastasis are common but rarely cause insufficiency

Clinical Evaluation

- Stage Patient: clinical stage and pathologic stage
- History and Physical
 - Cough, hemoptysis, exposures
 - Weight loss
- CT of chest and abdomen/pelvis with contrast,
- PET (sensitive for metastasis, recurrence)
- CT Brain/MRI Brain
- Bone Scan
- Review of any prior films very important
- Tissue diagnosis
 - Bronchoscopy (degree of obstruction/recurrence)
 - Mediastinoscopy
 - VATS/Thoracotomy

New Bronchoscopy Modalities

- EBUS
 - Endobronchial ultrasound → will be able to get tissue samples from many more nodal stations without invasive surgical procedures
- Navigational Bronchoscopy
 - Via GPS mapping

PET Scans

- Whole Body Positron-emission Tomography
 - Nuclear medicine, functional imaging technique
 - ^{18}F -fluorodeoxyglucose as a tracer (glucose analogue)
 - “Metabolic Imaging Technique”
 - Increased metabolism of glucose in all tumor cells
 - Carcinomas metabolize the tracer and “light-up” on the image
 - Concentrations of tracer imaged will indicate tissue metabolic activity by virtue of the regional glucose uptake
 - ~ 95% sensitivity for detecting primary bronchial tumors → if lesion is greater than 1 cm!

Clinical Presentation

- 10% Asymptomatic at Time of Presentation!

Symptoms of lung cancer in over 3500 patients at presentation

Symptom	Patients (percent)
Cough	45-74
Weight loss	46-68
Dyspnea	37-58
Chest pain	27-49
Hemoptysis	27-29
Bone pain	20-21
Hoarseness	8-18

Modified from: Hyde, L, Hyde, CI. *Chest* 1974; 65:299-306 and Chute CG, et al. *Cancer* 1985; 56:2107-2111.

Associated Presentations

- Large Airway Obstruction
- Obstructive Pneumonitis
 - Obstructive pneumonia
- Atelectasis
 - Especially with endobronchial lesion
- Lymphangitic spread
- Pleural or Pericardial Effusion
- Hemoptysis

Lung Cancer Screening

Mayo Lung Project

- Randomized controlled trials have NOT demonstrated a reduction in mortality from screening with CXR or sputum cytology

Low Dose Spiral Chest CT Screening

- Radiation dose exposure is one third that of a standard CT scan
- NLST
 - Large randomized control trial of annual low-dose CT screening in patients with a 30+ pack year history of smoking (including those who quit in the last 15 years) demonstrated a decrease in lung cancer and all-cause mortality
 - *High rate of false + (non-cancer) findings causing additional testing and additional procedures
 - Yearly CXR has NOT been shown to be effective for lung cancer screening and should NOT be done (Grade IA level of evidence)

Treatment of SCLC

- LIMITED

- Radiation and Chemotherapy
- PCI for complete responders
- Occasionally surgery

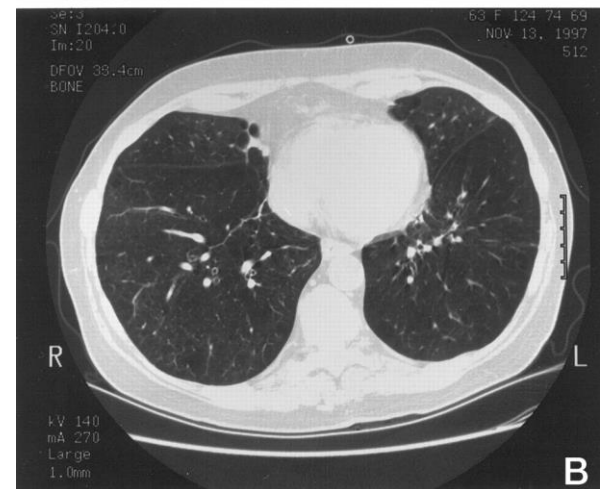
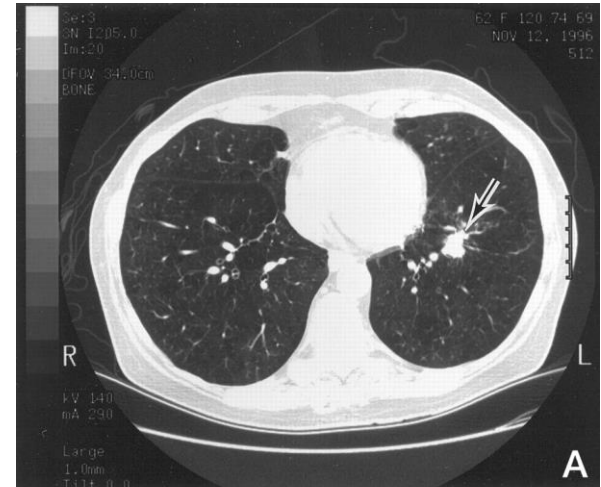
- EXTENSIVE

- Chemotherapy
- PCI for complete responders
- Radiation therapy for symptomatic metastasis (bone, epidural, brain)

Surgical treatment is rarely possible

NSCLC: Stage I and II Treatment

- Complete surgical resection
- Postoperative adjuvant chemotherapy for Stage II and possibly Stage Ib
- Patients who refuse chemotherapy or are not candidates may try radiation therapy



NSCLC: Stage III Treatment

- Locoregionally advanced disease due to primary tumor extension into extrapulmonary structures (T3 or T4) or mediastinal lymph node involvement (N2 or N3) without evidence of distant metastases (M0)
- Stage IIIA
 - Combined modality approach
 - Chemotherapy followed by surgery and postoperative chemo or radiation
 - 5yr Survival 10-30% with surgery alone
 - Multimodality treatments improve survival
- Stage IIIB
 - Surgery NOT an option
 - Combination chemo & XRT → 5yr survival 10%

NSCLC: Stage IV Treatment

- Chemotherapy or Palliative treatment only options
 - Palliative Therapy:
 - Brachytherapy
 - Laser Therapy
 - Airway stents and/or photodynamic therapy for airway obstruction
 - Radiotherapy → Palliative Treatment of bronchial obstruction, painful bone metastases, or CNS metastases

Treatment

- The following are major contraindications to curative surgery or radiotherapy alone in patients with non-small cell lung cancer:
 - Extrathoracic metastasis
 - SVC, vocal cord/phrenic nerve paralysis
 - Malignant pleural effusion
 - Cardiac tamponade
 - Tumor within 2cm of carina
 - Contralateral lung metastasis
 - Bilateral endobronchial tumor
 - Metastasis to supraclavicular lymph nodes
 - Contralateral mediastinal node metastasis
 - Main pulmonary artery involvement

Treatment

- Chemotherapy: clearly effective for small cell, but relatively poor results for non-small cell carcinomas
- Laser Therapy: Nd-YAG laser for palliation of obstructing endobronchial lesions

Treatment:

Tyrosine Kinase Inhibitors

- Beyond histologic features, the status of molecular targets, such as the epidermal growth factor receptor (EGFR) gene, has been shown to correlate with response to treatment with EGFR tyrosine kinase inhibitors in patients with relapsed or refractory disease and in the first-line therapy setting.

Treatment: SPN

- Xray density that is surrounded by normal aerated lung, with circumscribed margins $> 5\text{cm}$
- 35% of such lesions are malignant (primary)
- “To resect or not to resect?” that is the question
- The following favors resection:
 - Young, large lesion, lack of calcification, chest symptoms, atelectasis, pneumonitis, adenopathy, growth revealed via x-rays
- Lack of growth over a > 2 year period and calcification would indicate a benign nature
- Dense central nidus, multiple punctate foci, “bull’s eye” (granuloma) and “popcorn ball” (hamartoma) calcifications suggest benign lesion

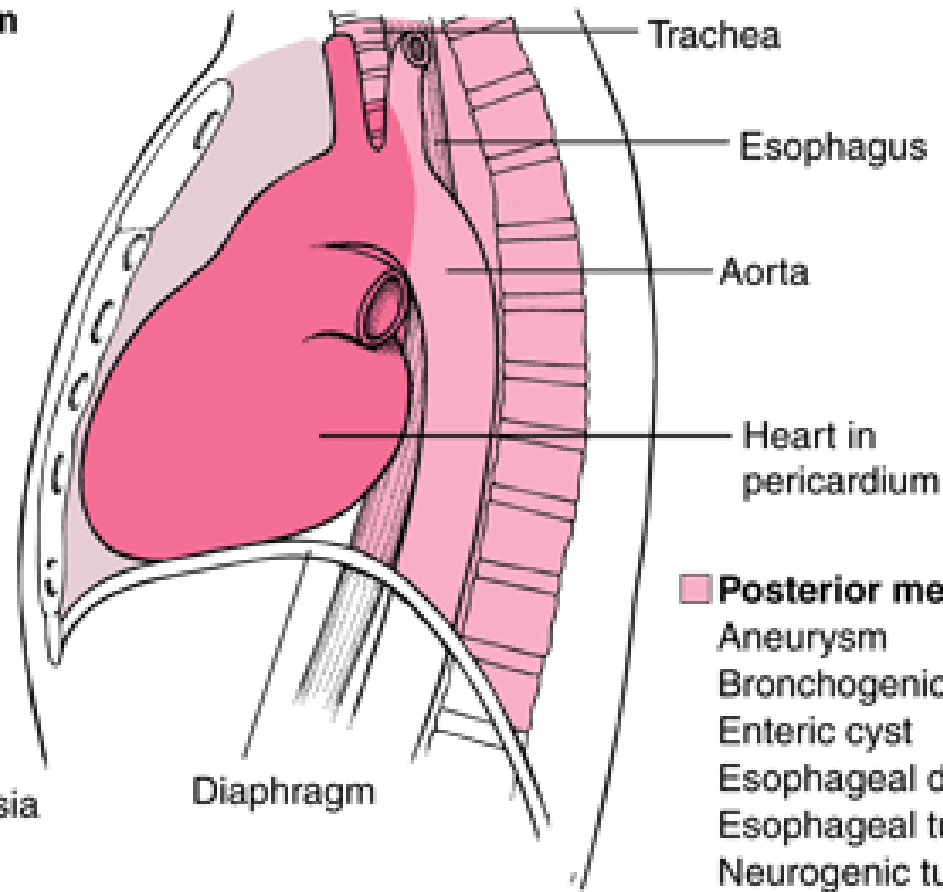
Mediastinal Mass

Anterior mediastinum

- Aneurysm
- Angiomatous tumor
- Goiter
- Lipoma
- Lymphoma
- Morgagni hernia
- Parathyroid tumor
- Pericardial cyst
- Teratoma
- Thymoma
- Thyroid tumor

Middle mediastinum

- Bronchogenic cyst
- Bronchogenic tumor
- Lymph node hyperplasia
- Lymphoma
- Pleuropericardial cyst
- Vascular masses



Posterior mediastinum

- Aneurysm
- Bronchogenic tumor
- Enteric cyst
- Esophageal diverticula
- Esophageal tumor
- Neurogenic tumor

Benign Lung Neoplasms

- Represents < 5% of all primary tumors including:
 - Bronchial adenomas
 - Hamartomas (popcorn calcification)
 - Uncommon neoplasms
 - Chondromas, Fibromas, Lipomas, Hemangiomas, Leiomyomas, Teratomas, Pseudolymphomas

Benign Lung Neoplasms

- Can all present as central-masses causing
 - Airway obstruction
 - Cough
 - Hemoptysis
 - Pneumonitis
- The masses may or may not be visible on x-ray but are usually accessible to fiberoptic bronchoscopy
- Additionally these can present without symptoms as solitary pulmonary nodules

Bronchial Adenomas

- 80% are central
- Slow growing, endobronchial lesions
- Represent 50% of all benign pulmonary lesions
- 80-90% are carcinoids
- 10-15% are adenoid cystic tumors (cylindromas)
- 2-3% are mucoepidermoid tumors

Bronchial Adenomas

- Present in patients 15-60 years old as endobronchial lesions and are often symptomatic for several years
- Bronchial carcinoids which usually follow a benign course express a neuroendocrine phenotype similar to the Kulchitsky cell
- This cell is part of the Amine Precursor Uptake and Decarboxylase (APUD) System

Bronchial Adenomas

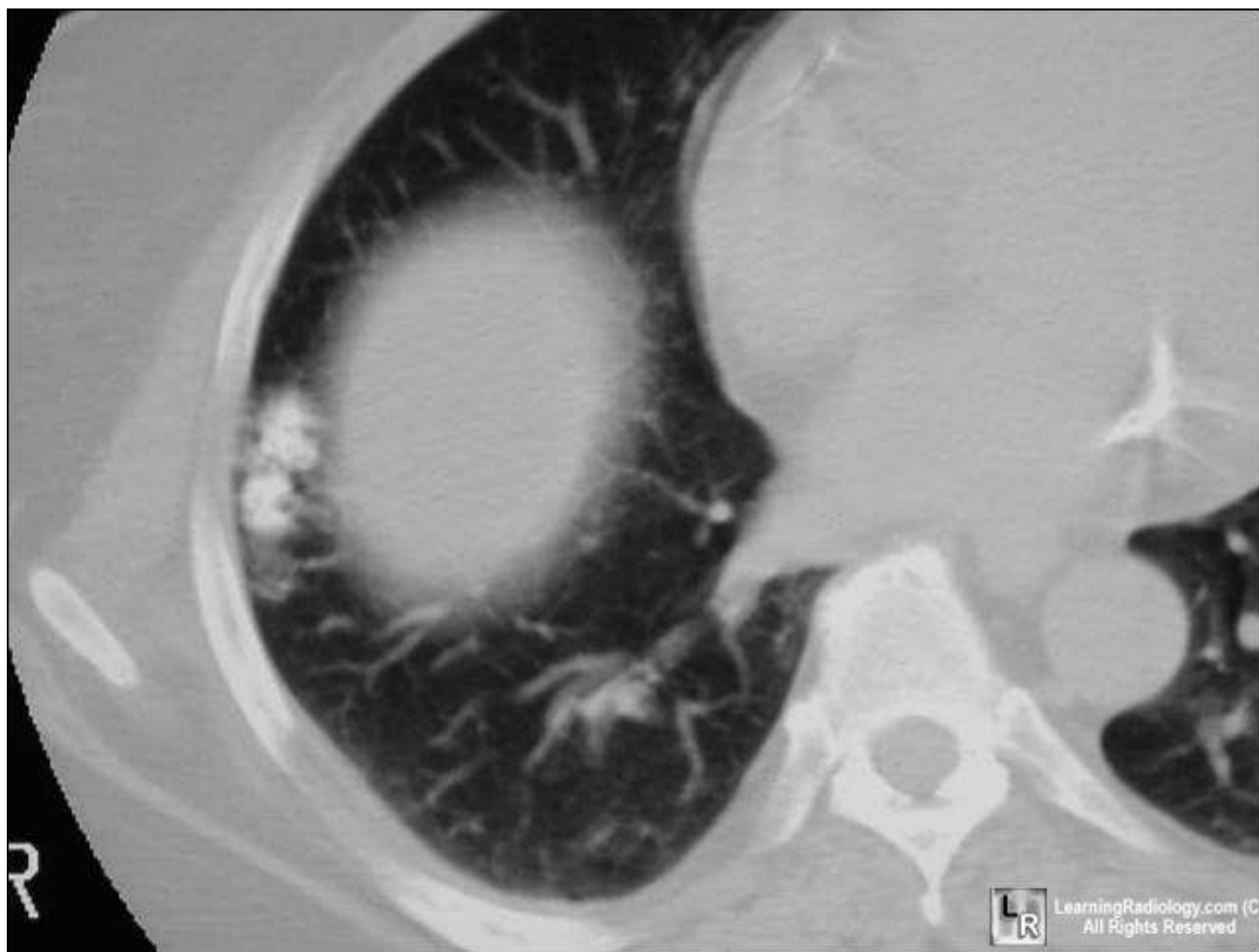- Carcinoids may secrete other hormones, such as ACTH, vasopressin, and cause paraneoplastic syndromes that resolve on resection
- Metastases may produce the carcinoid syndrome
- Metastases may produce carcinoid syndrome
 - Cutaneous flushing
 - Cough, wheeze, dyspnea
 - Diarrhea, N/V
 - Pulmonic/tricuspid valve thickening
 - Endocardial fibrosis

Bronchial Adenomas

- Are hypervascular and can bleed profusely after bronchoscopic biopsy
- Must be dealt with as potentially malignant and require resection for relief of symptoms and to prevent metastasis, which may produce paraneoplastic syndromes
- 5-year survival rate after resection is 95%
- 70% if regional lymph nodes involved

Hamartomas

- Peak incidence age 60 with a preponderance in males
- Histologically they contain normal pulmonary tissue components in a disorganized fashion
- Peripheral, clinically silent and benign in behavior
- Radiological findings are “popcorn” calcification
- The lesions usually have to be resected if patient is a smoker – VATS can be used to minimize problems



Paraneoplastic Syndromes

- Examples include:
 - SIADH causing hyponatremia (small cell)
 - ACTH- producing Cushing Syndrome (small cell)
 - Hypercalcemia:
 - Parathyroid hormone related peptide (PTHrP) from Squamous Cell
 - Digital clubbing/ Hypertrophic pulmonary osteoarthropathy
 - Usually non-small cell
 - Eaton-Lambert Syndrome (proximal muscle weakness usually in small cell)
 - Peripheral Neuropathy (small cell)
 - Subacute cerebellar degeneration
 - Dermatomyositis/ Polymyositis

Paraneoplastic Syndrome associated with Lung Cancer

- Pathogenesis: Aberrant release of humoral mediators
 - Hormones/hormone-like peptides
 - Cytokines
 - Antibodies
- Occurrence: 10% of patients with lung cancer
- Expression: May precede diagnosis

Neuroendocrine Tumors

- Spectrum of tumors
 - Small Cell
 - Well differentiated neuroendocrine tumor of the lung (atypical or malignant carcinoid)
 - Bronchial carcinoid

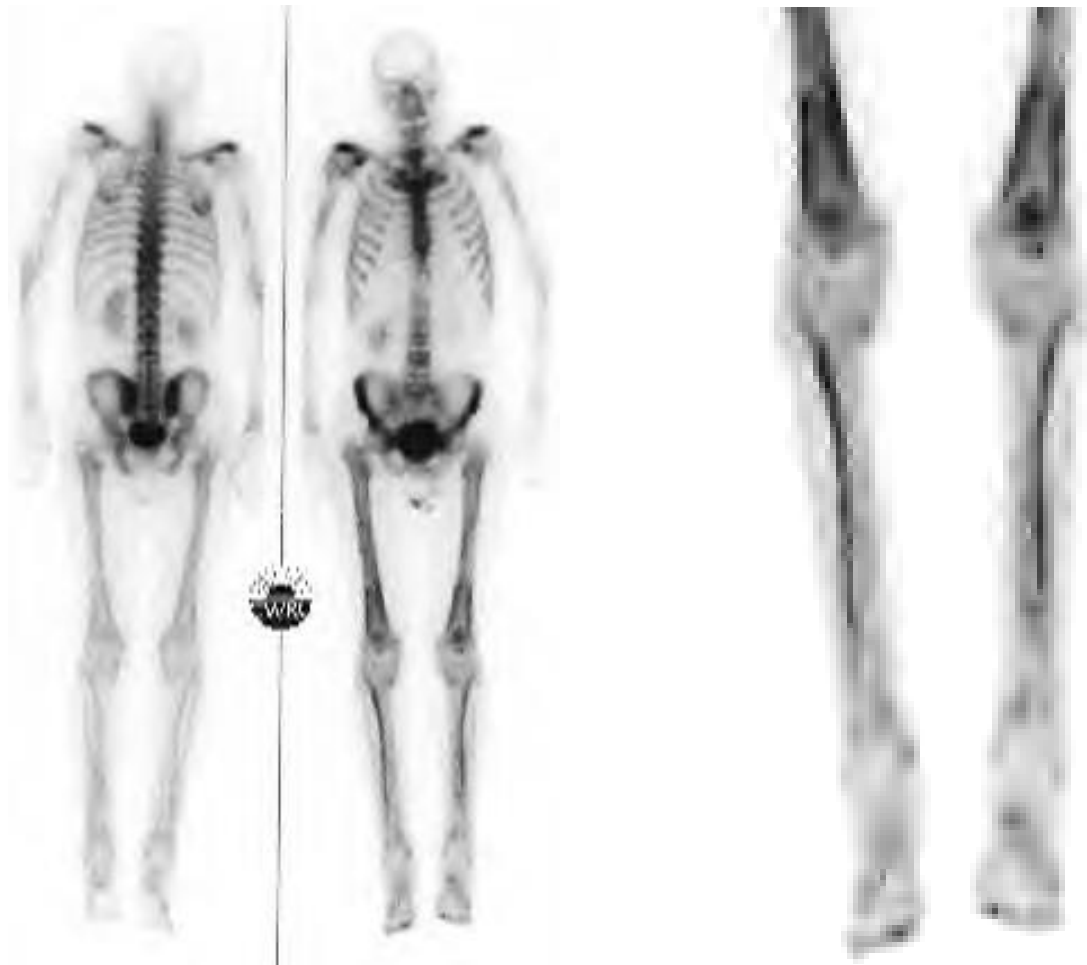
Systemic Features

- Weight loss - anorexia, cachexia, fever (20%)
- Etiology:
 - Tumor Necrosis Factor (TNF)?
 - Interleukin-1 (IL-1)?
 - Prostaglandins?
- Rule out:
 - Anemia
 - Infection
 - Malnutrition
 - Fluid and electrolyte disturbances
 - Drug reactions

Cutaneous Features

- Clubbing (hypertrophic pulmonary osteoarthropathy)
- Etiology:
 - Neurogenic (vagal)
 - Hormonal (\uparrow estrogen or growth hormone)
 - Vascular (A-V shunt and tissue hypoxia)
- Definition:
 - Soft tissue subungual thickening of fingernails
- Frequency:
 - 80% caused by bronchogenic cancer
 - Usually non-small cell

Hypertrophic Pulmonary Osteoarthropthy



Endocrine Features

- Cushing's Syndrome:
 - Many lung carcinomas contain proopiomelanocortin (precursor to corticotropin) 50%
 - Small cell carcinoma 1-5%
 - Bronchial carcinoids 28-38%
 - Symptoms: weakness, hyperglycemia, polyuria, hypokalemic alkalosis
 - Diagnosis:
 - 24 hour urine-free cortisol excretion (overnight)
 - 1 mg dexamethasone suppression test (can be confused with Pituitary Dependent Cushing's)

Endocrine Features cont.

- Therapy:
 - Tumor removal or debulking
 - Ketoconazole
 - Aminoglutethimide
 - Metyapone
 - Odd therapy:
 - RU 486
 - Octreotide (somatostatin)
 - Selective adrenal embolization
 - Adrenalectomy

Hypercalcemia – Squamous cell

Parathyroid hormone related peptide secreted

- Increased bone reabsorption
- Renal tubular reabsorption of Ca^{2+}
- Renal excretion of PO_4
- Renal excretion of cyclic adenosine monophosphate

Hypercalcemia – Squamous cell cont.

- Therapy: rehydration by forced saline diuresis and calciuric agents (LASIX)
 - Goal: ↓ bone reabsorption: ↑ Ca²⁺ excretion
 - Calcitonin (onset 4-6 hour, duration 24-48 hours)
 - Mithramycin – osteoclastic inhibitor
 - Bisphosphonates – not for squamous cell
 - Etidronate – not for Renal Failure (RF)
 - Pamidronate - not for RF
 - Gallium nitrate – 5 days 24 hour IV infusion
 - Parathyroid hormone receptor antagonists currently in research

Syndrome of Inappropriate ADH (SIADH)

- Small cell 50% - only 1-2% have SIADH
- Increased RNA levels of Atrial Natriuretic Factor (ANF)
- Symptoms: confusion, seizures, coma – check Na⁺ (usually low)
- Therapy:
 - Limit fluids
 - Enhance free water excretion
 - Remove or debulk tumor
 - IV saline and loop diuretic
 - Demeclocycline (blocks ADH in kidney → Diabetes Insipidus)
 - Lithium carbonate ?

Hematologic Features

- Anemia – 20%
- Etiology:
 - Chronic disease
 - Iron deficiency
 - Chemotherapy
 - Hemolysis
 - Bone marrow infiltration
 - Erythrocyte aplasia
- Leukocytosis

Hematologic Features

Coagulation abnormalities

- Thrombotic: Trousseau sign - Migratory Thrombophlebitis, PE, Thrombosis, Budd Chiari
 - Etiology:
 - Platelet activation?
 - Thrombosis
 - Procoagulant substances - secreted by tumor cells or macrocyte-macrophage
 - Therapy: Heparin, Thrombolytic agents
- Hemorrhagic - Dysfibrinoginemia

Neurologic Syndrome

- Small cell most common
 - Etiology: Autoimmune impairs Ca^{2+} channel activity which impairs release of acetylcholine
 - Eaton-Lambert Myasthenic Syndromes
 - Symptoms:
 - Proximal muscle weakness
 - Potential which enhances after 10-15 seconds of max
 - Voluntary contraction
 - Therapy:
 - 3,4-diaminopyridine (enhance release of acetylcholine)
 - Plasmaphoresis
 - Anticholinesterases
 - Immunosuppressive: steroids and azathioprine (IMURAN)

Other Neurologic features (Small cell)

- Subacute peripheral neuropathy:
 - Type I Anti Neuronal Nuclear Antibody (ANNA-I)
- Intestinal Dysmotilities:
 - Nausea, vomiting, abdominal discomfort, weight loss, altered bowel habits
- Limbic encephalitis:
 - Mental status changes and acute psychosis
 - ANNA-I?
- Necrotizing myelopathy:
 - ANNA-I?
 - Acute rapidly ascending paraplegia – rapid deterioration & death
- Visual:
 - Binocular loss - rare
 - ANNA-I?

Copyright 2006 by Randy Glasbergen.
www.glasbergen.com



**“Lose some weight, quit smoking, move
around more, and eat the carrot.”**