

Adult Congenital Heart Disease

Saurabh Rajpal, MBBS, MD

Assistant Professor – Medicine

COACH Program **C**olumbus **O**hio **A**dult **C**ongenital **H**ear Disease and Pulmonary
Hypertension Program

The Ohio State University

Nationwide Children's Hospital



COACH

Columbus Ohio Adult Congenital
Heart Program



THE OHIO STATE UNIVERSITY

WEXNER MEDICAL CENTER

No Disclosures

Objectives

- To discuss increasing prevalence of ACHD
- To discuss common ACHD Diagnoses
- Strategies for lifelong care of ACHD patients

Why Should the We Care?

Circulation Research

HOME

ABOUT THIS JOURNAL ▼

ALL ISSUES

SUBJECTS ▼

BROWSE FEATURES ▼

EDITORIAL

Congenital Heart Disease

The Remarkable Journey From the “Post-Mortem Room” to Adult Clinics

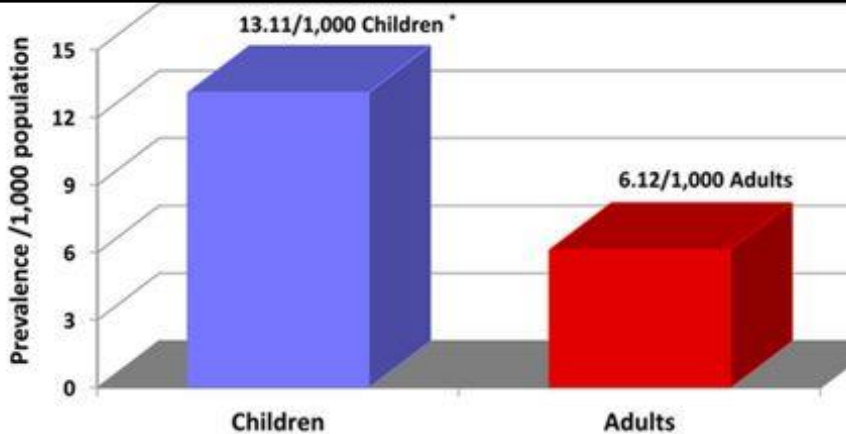
Ali J. Marian



Download PDF

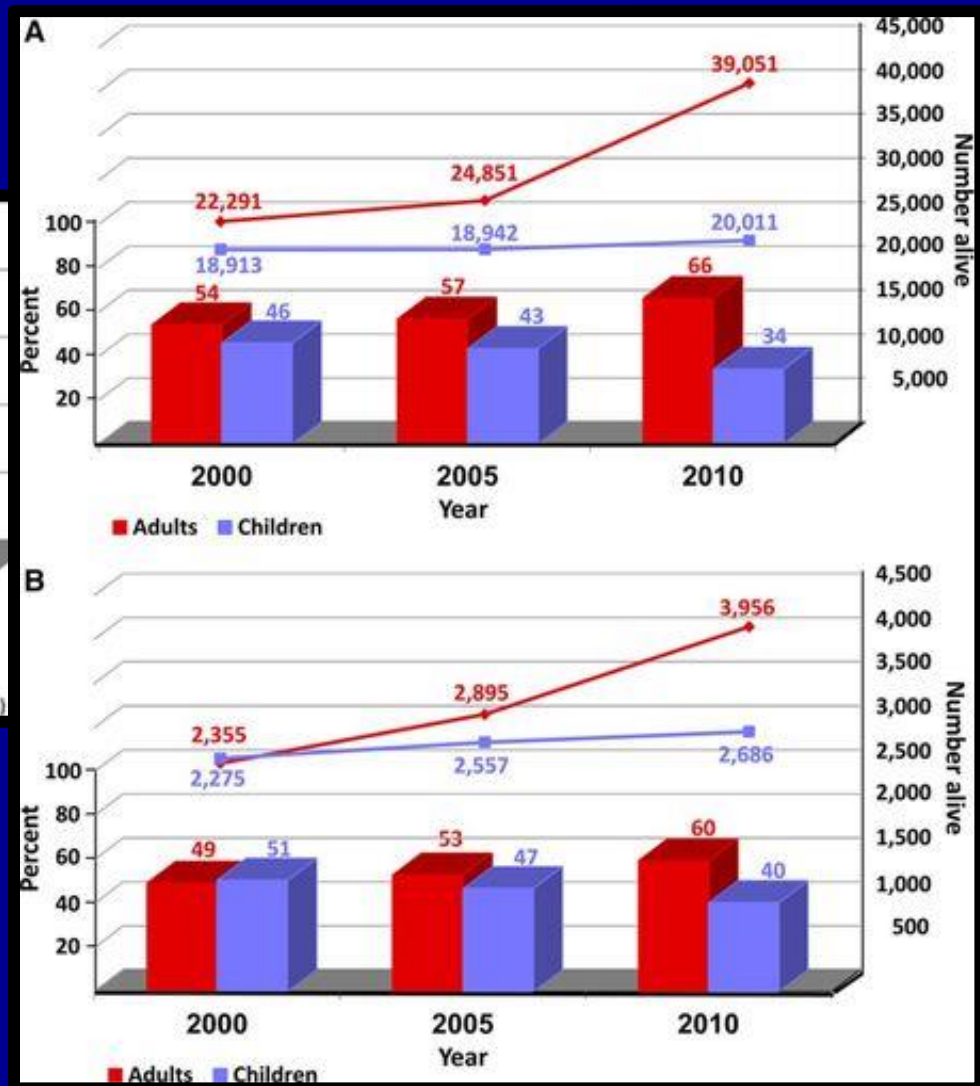
DOI <https://doi.org/10.1161/CIRCRESAHA.117.310830>
Circulation Research. 2017;120:895-897
Originally published March 16, 2017

CHD Prevalence

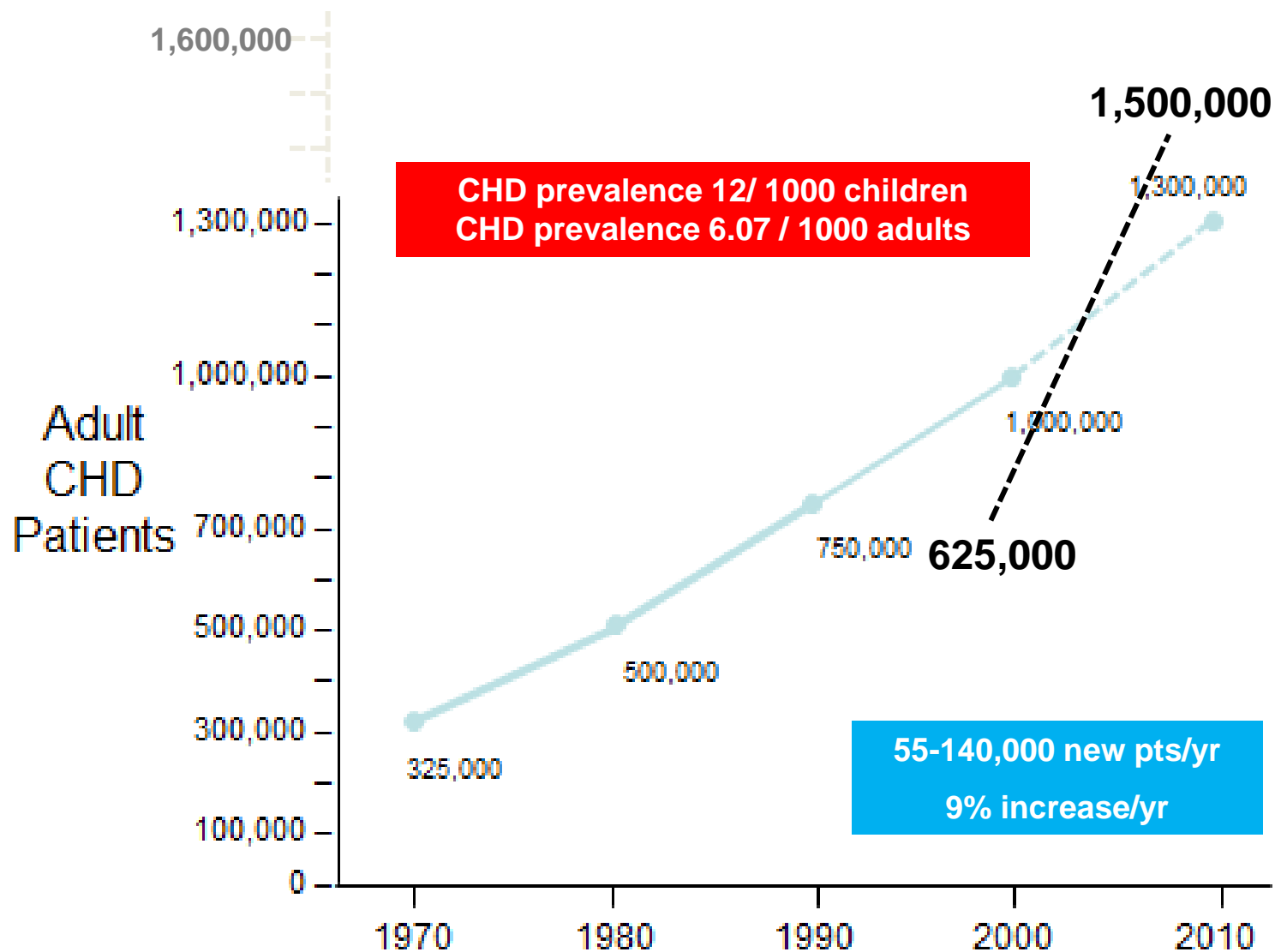


*Infants were included in Children

In 2010, the prevalence was 13.11, 95%CI = (12.43, 13.81) per 1000 children, and 6.12, 95% CI = (5.69, 6.57)

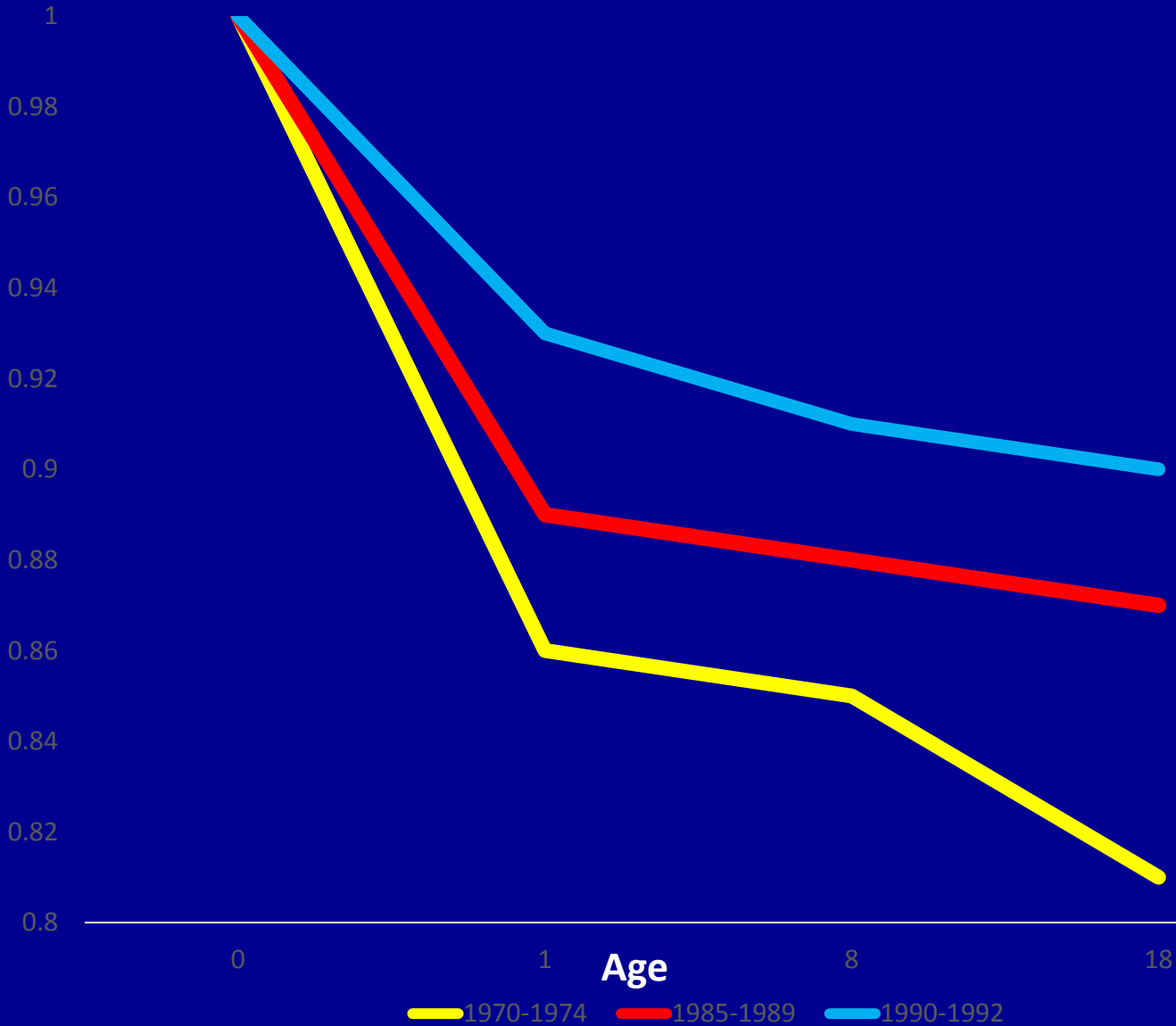


ACHD Prevalence

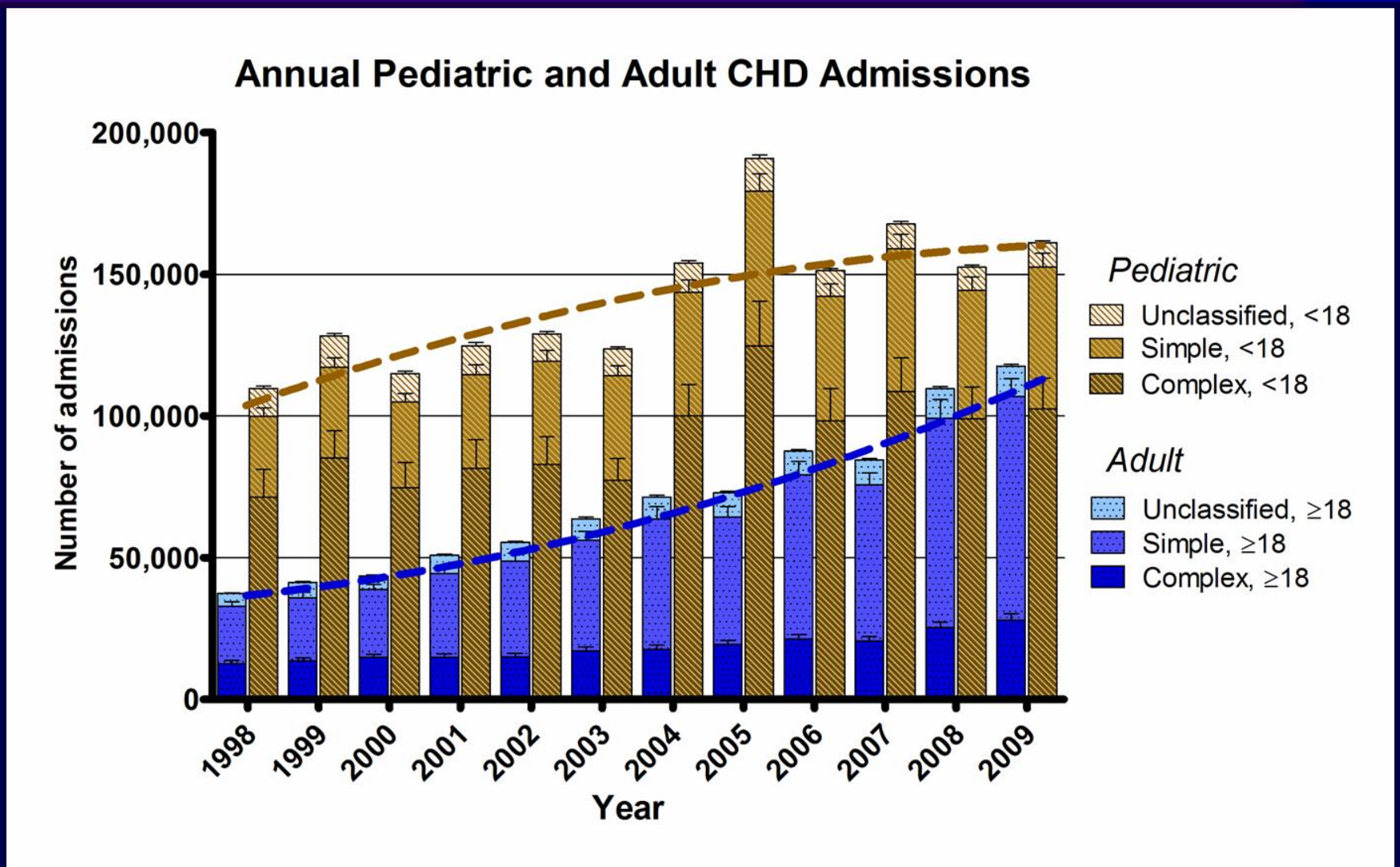


Estimated Survival- Era Effect

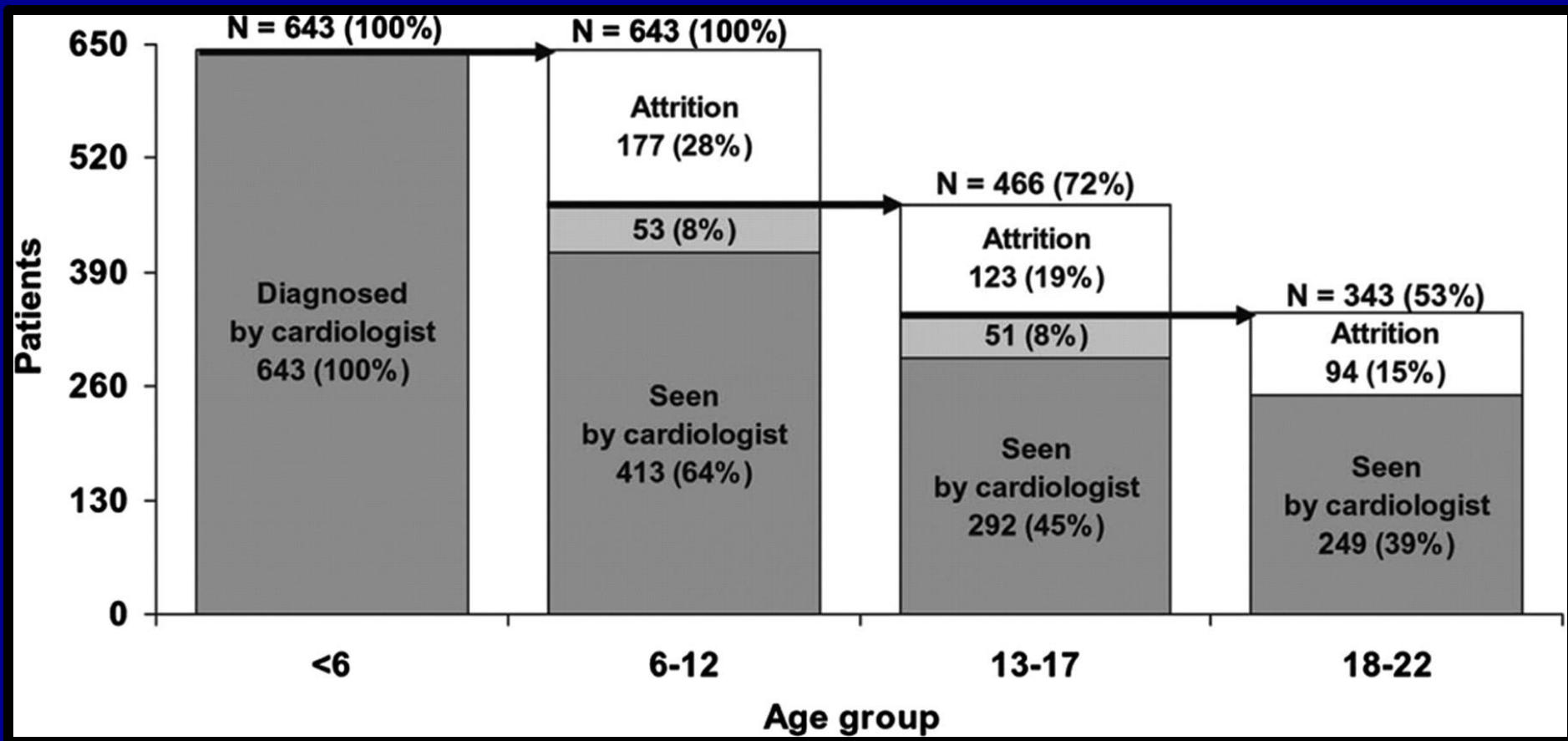
Estimated Probability of Survival



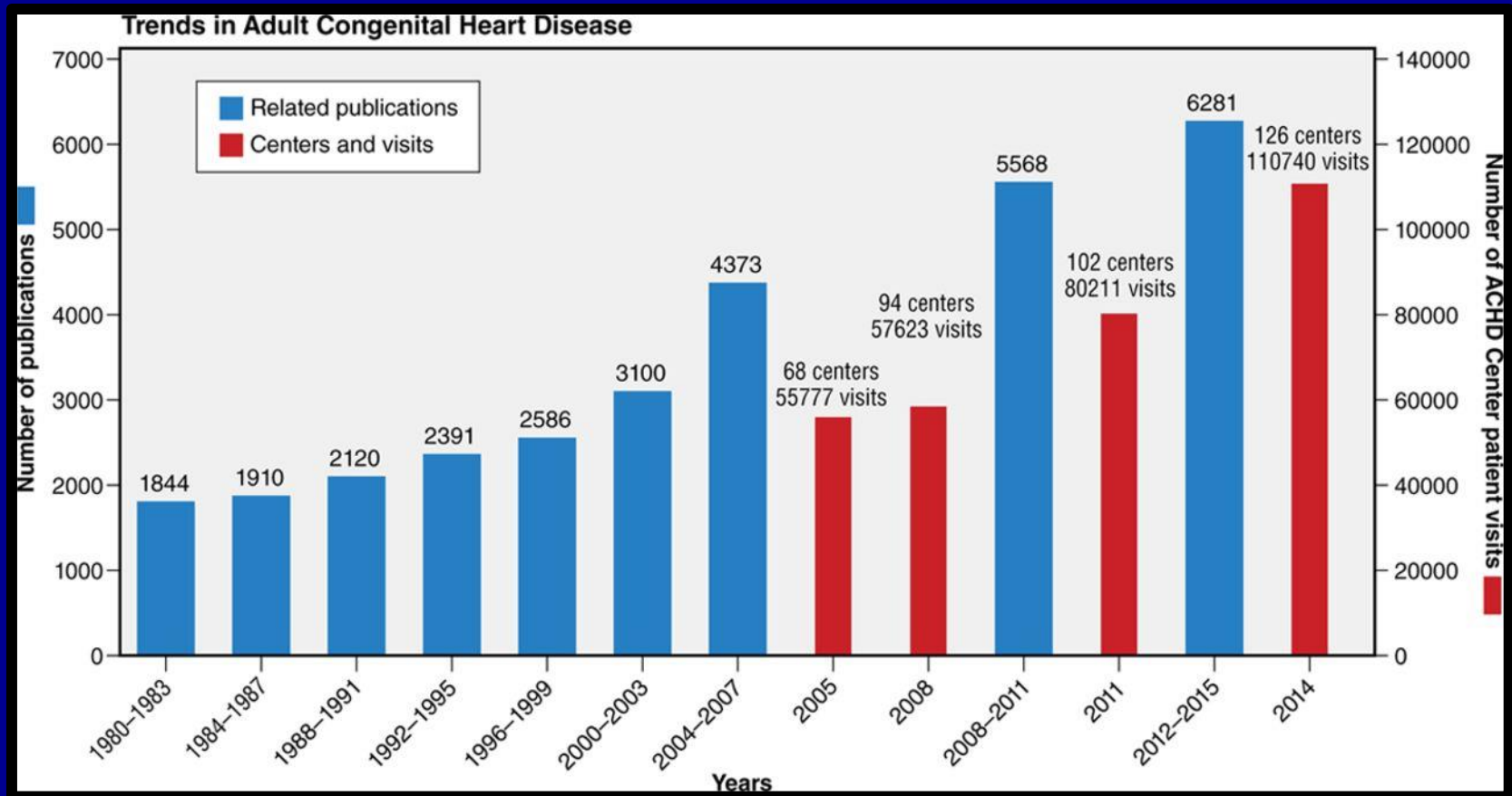
ACHD Hospitalizations in the U.S.



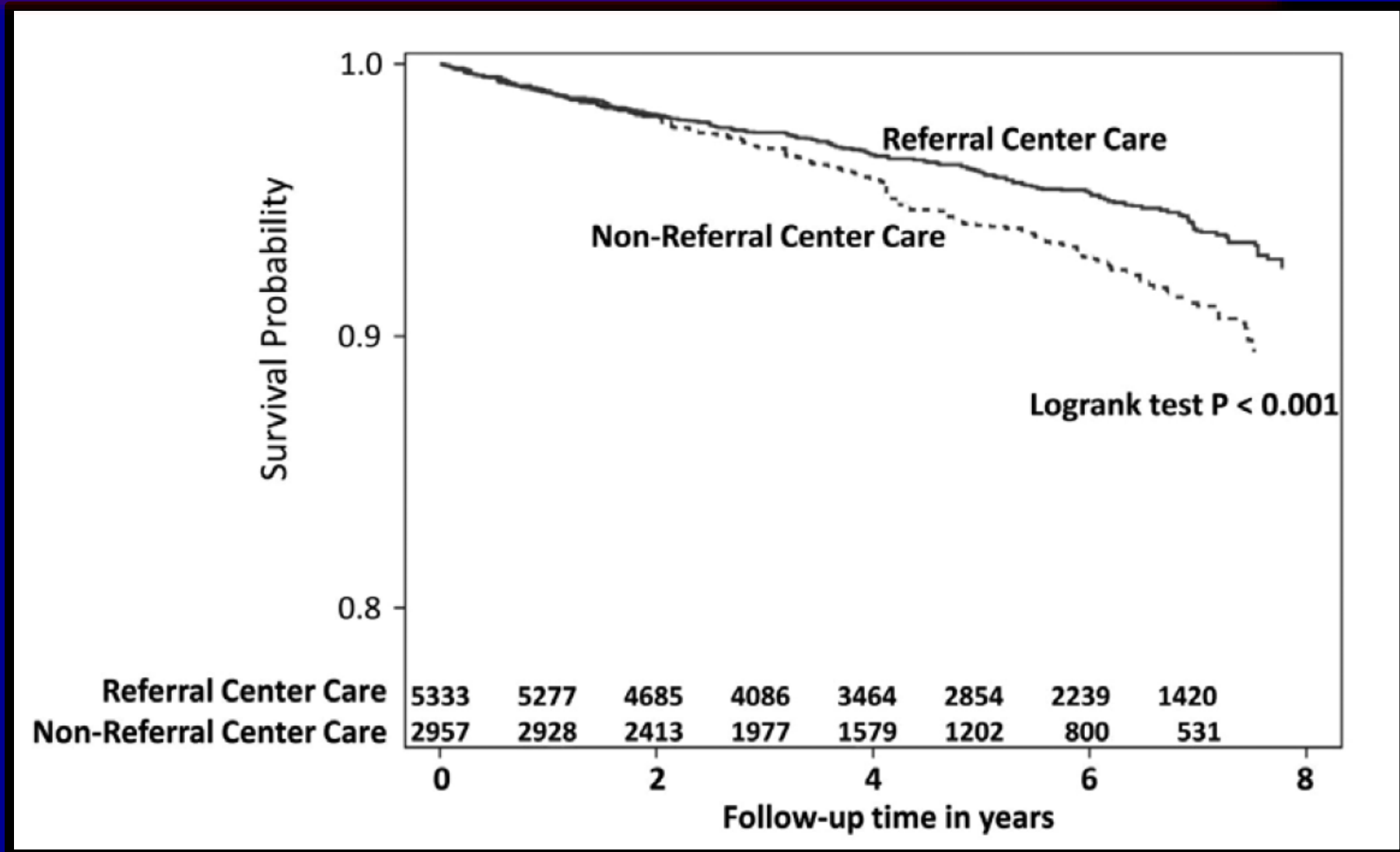
Trends in ACHD



Trends in ACHD



Trends in ACHD

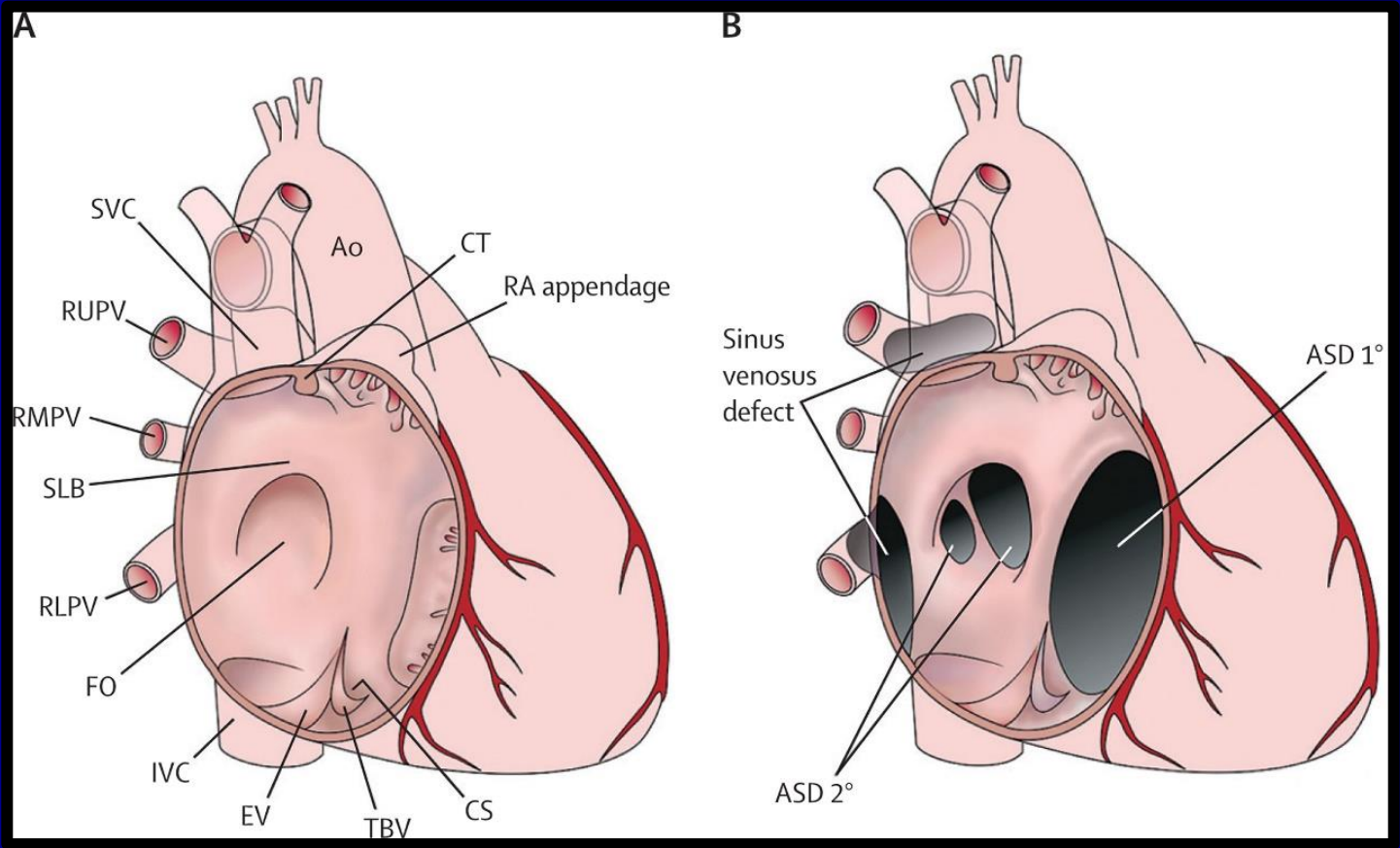


ACHD Patients - Common Issues

- Arrhythmias
- Heart Failure
- Pulm. Hypertension
- Renal Disease
- Liver Disease
- Anemia
- Neurocognitive Issues
- Advance Care Planning

- Quality of Life
- Transition
- Insurance
- Birth Control
- Pregnancy
- Dental Issues
- Exercise
- Hep C

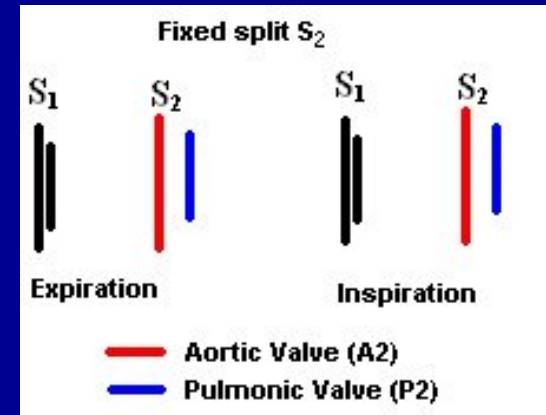
Atrial Septal Defect



Geva et al. Lancet 2014

Physical Exam – Atrial Septal Defect

- Hyperdynamic precordium
- Loud P2- Pulm HTN
- Signs of RHF rare
- Widely split and fixed S2

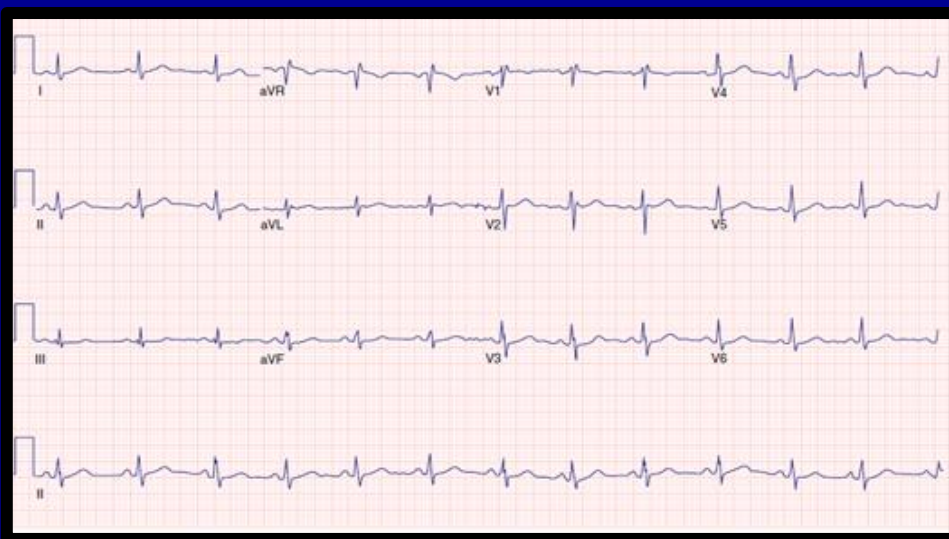


Murmurs in ASD

- Soft SEM- LUSB
- Diastolic rumble over LLSB- increased flow TV
- HSM at LLSB- TR

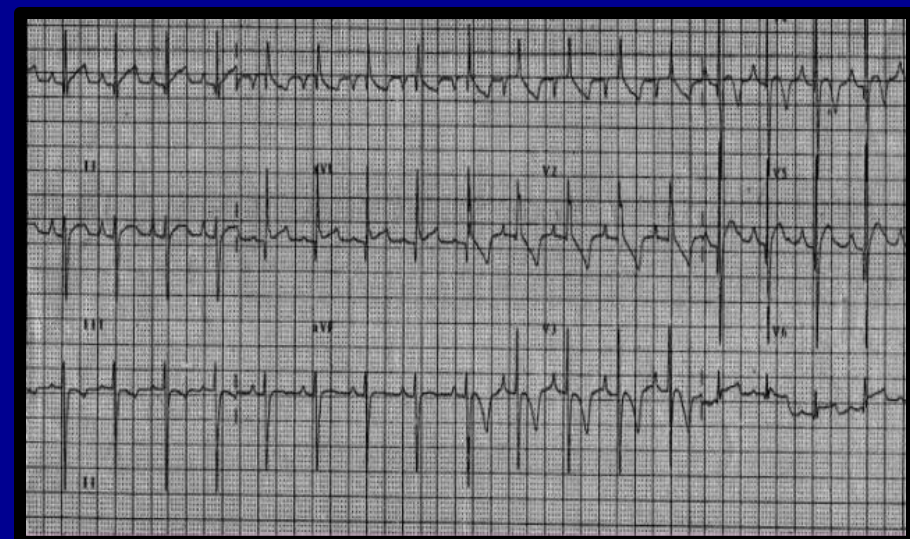EKG

Secundum ASD



Incomplete RBBB
Right Axis Deviation

Primum ASD

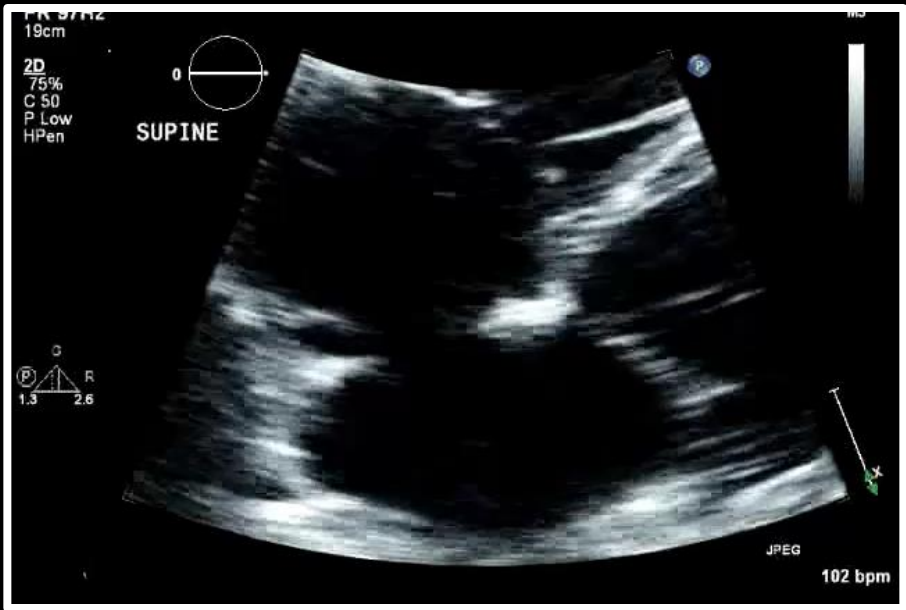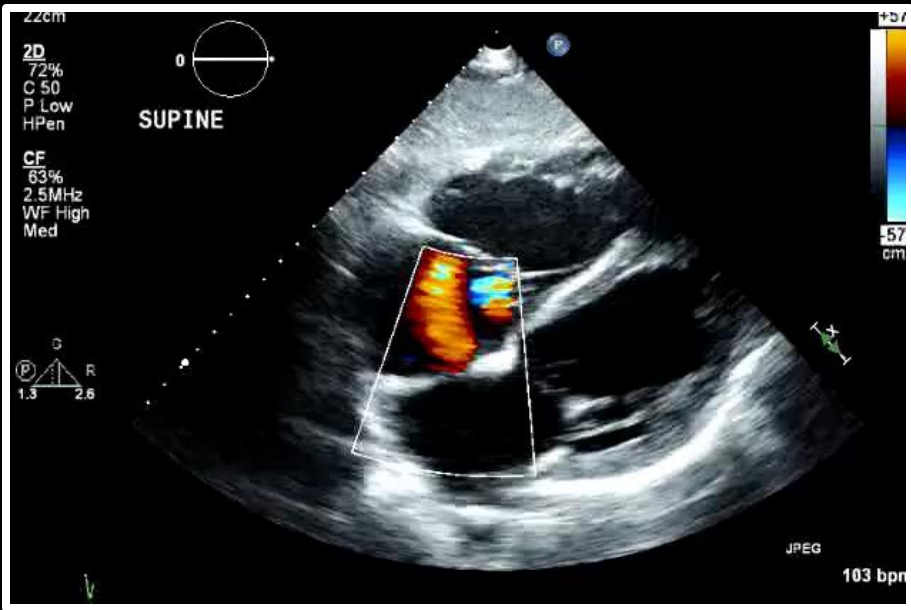


Incomplete RBBB
Left Axis deviation

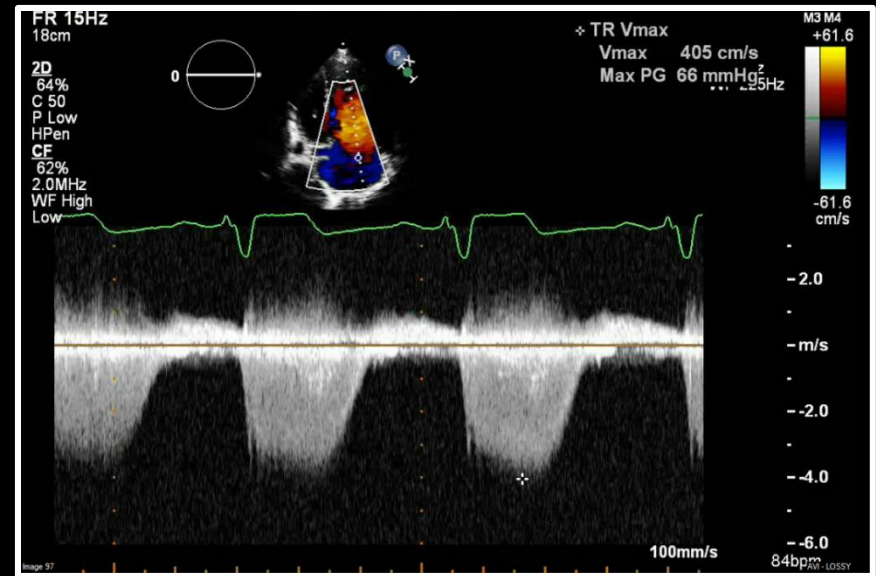
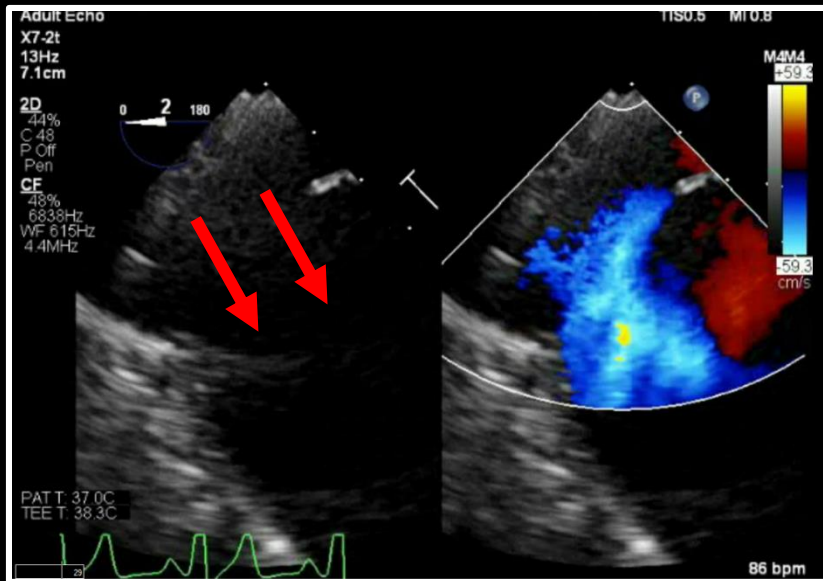
ASD and Aging

The nature of aging (systemic HTN, DM, atherosclerosis, senescence) → ↑ LVED_p and ↑ Qp/Qs: previously 'silent' shunts can become more apparent. Therapy should first be directed at processes that lower LVED

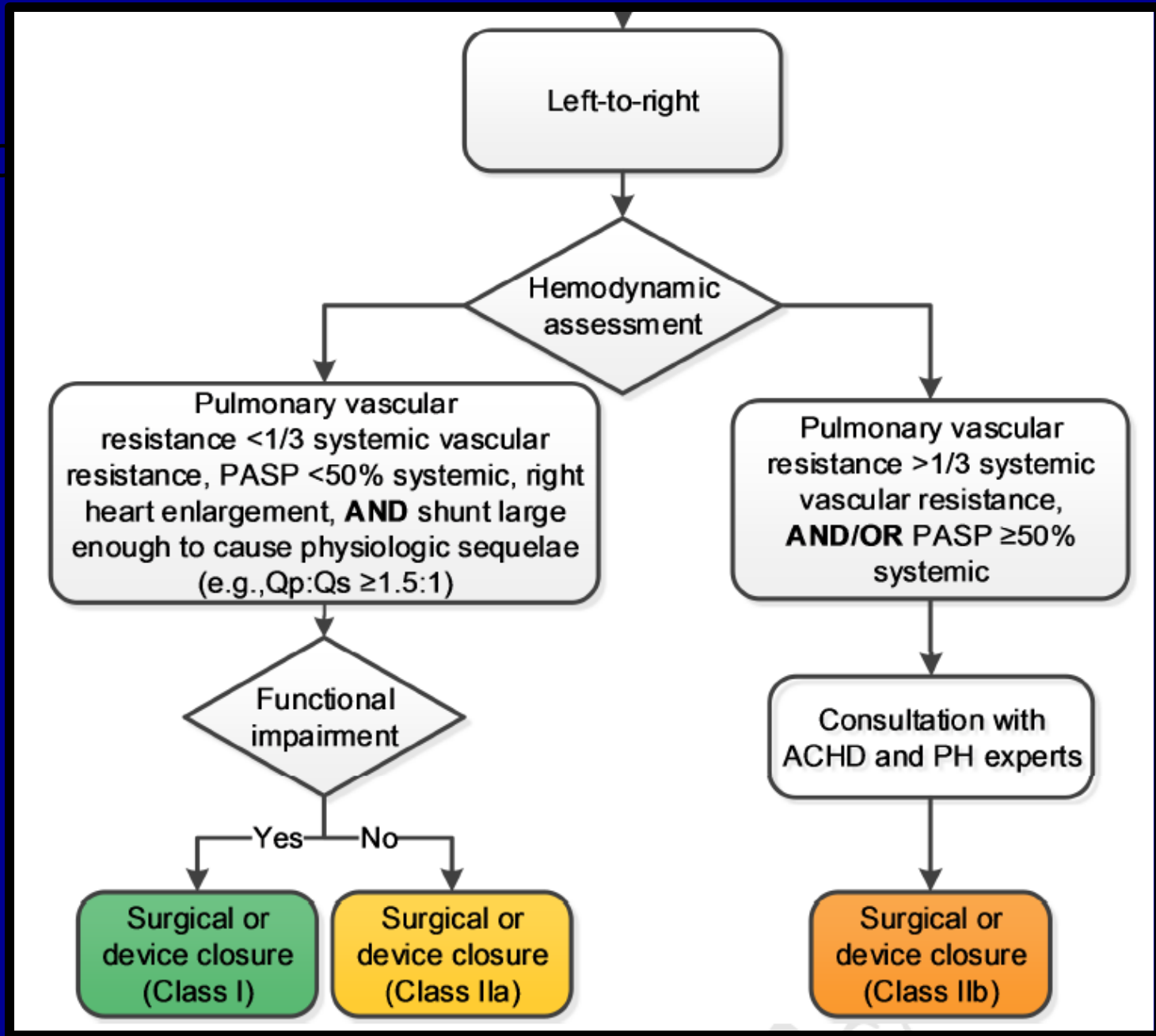
ASD – Myocardial Infarction and PE after IVDU



Large ASD



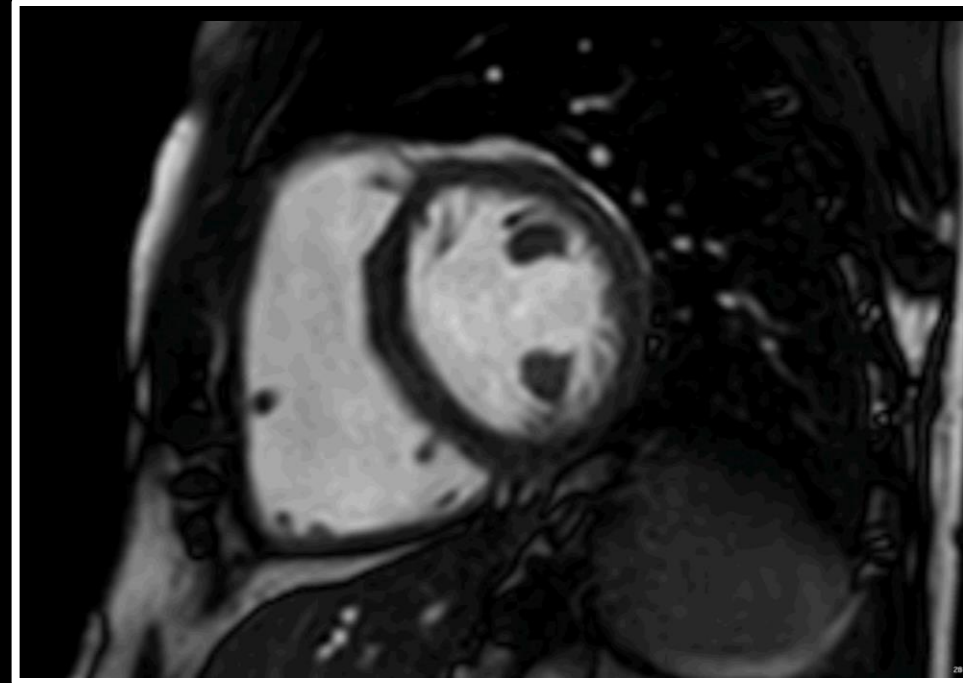
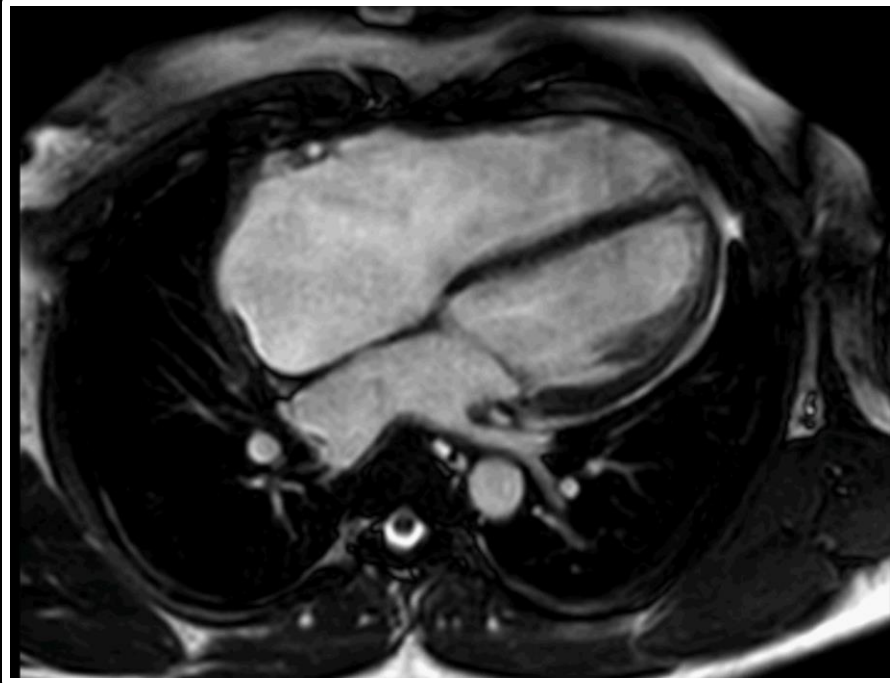Pulmonary Hypertension



Associated Anomalies

- Anomalous pulmonary veins
- VSD
- Primum ASDs - MR, cleft mitral valve

RV Dilation



RVEDV_i: 145 ml/m²
RVEF: 61%

LVEDV_i: 102 ml/m²
LVEF: 56%

Qp/Qs : 1.1
TR fraction: 49%

Etiologies of RV Dilation

Tricuspid regurgitation

Pulmonary regurgitation

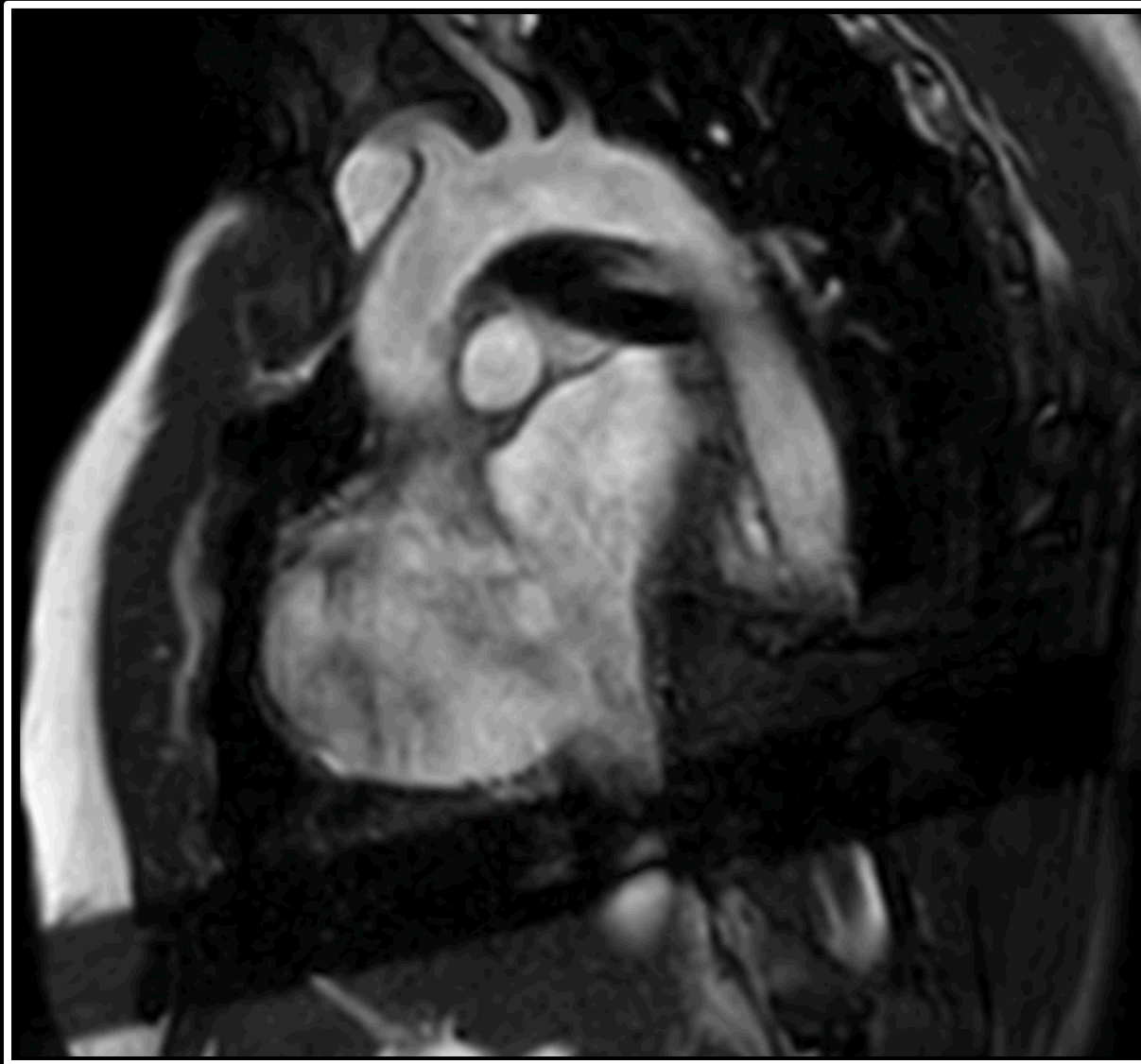
Pulmonary artery hypertension

Shunt Lesions

Myocardial abnormalities

- Uhl's anomaly
- ARVC
- Ventricular dysfunction

Inferior Sinus Venosus – ASD

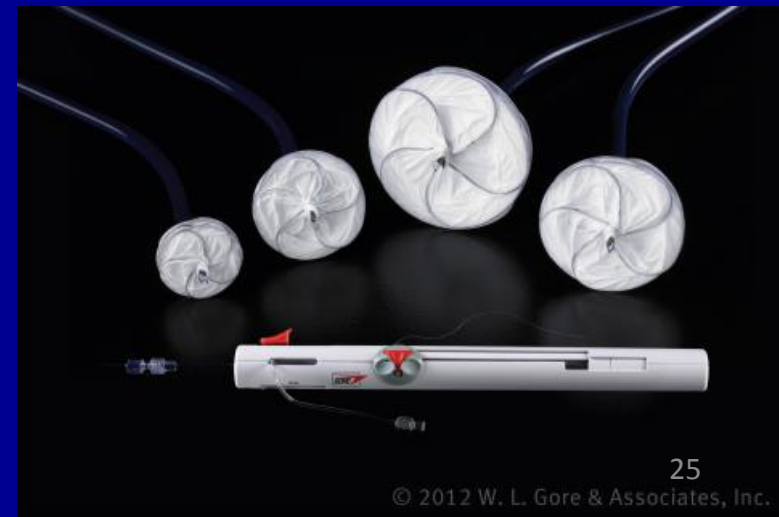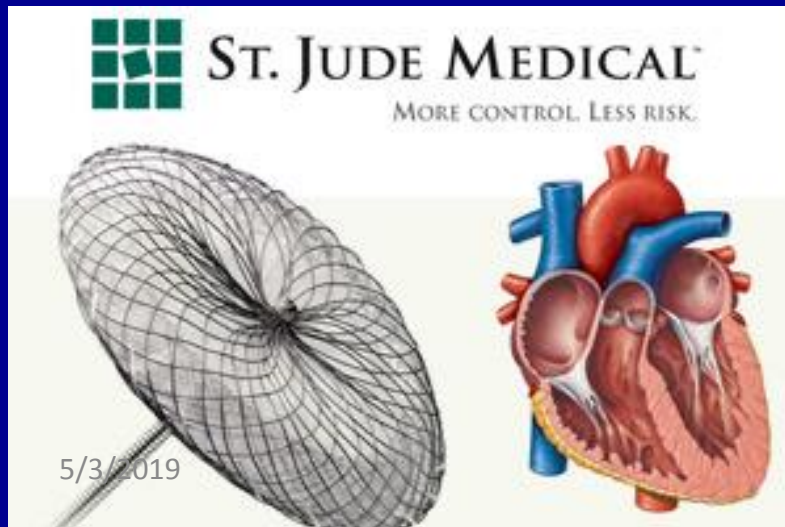


ASD- Indications for Closure

- **Significant left-to-right shunt**
 - right ventricular volume overload
 - with or without symptoms
 - without pulmonary hypertension*
- **Orthodeoxia-platypnea**
- **Paradoxical embolism**
- **At the time of another cardiac surgery**

ASD Closure

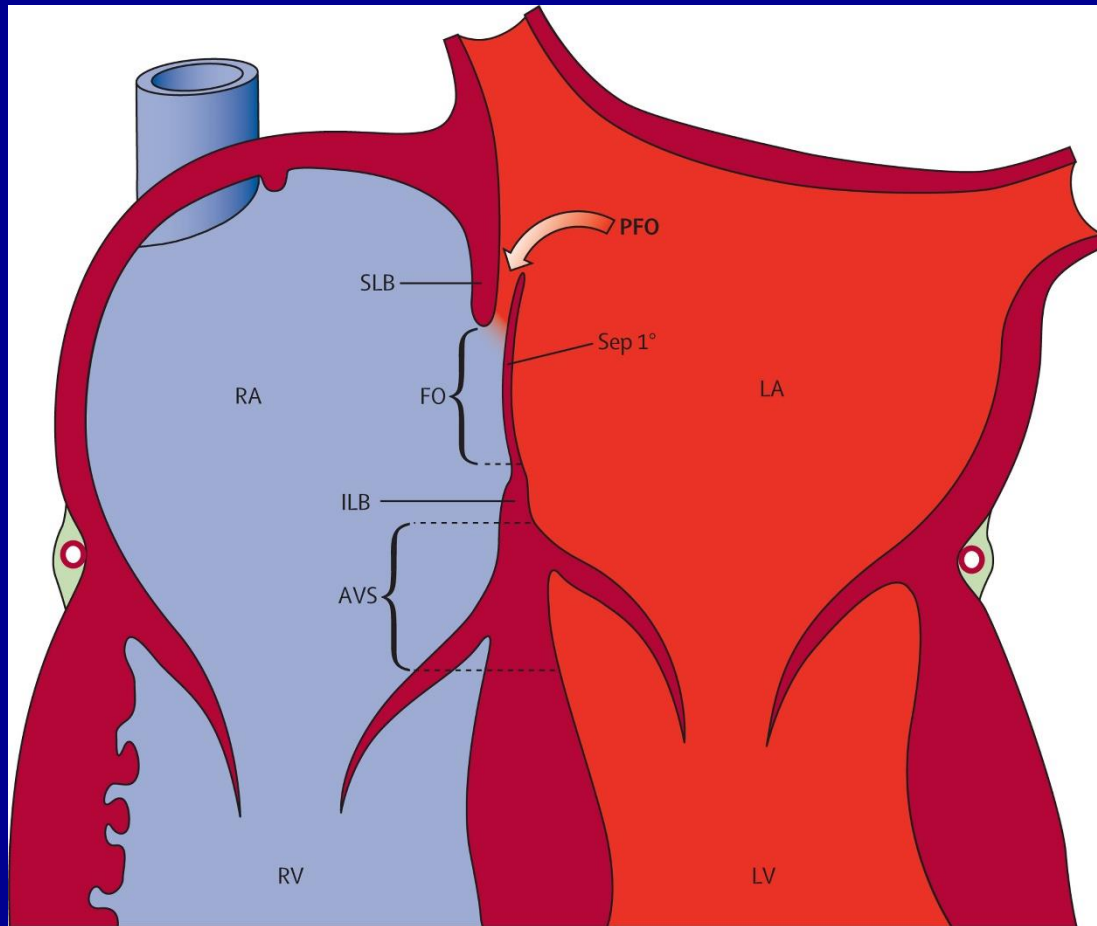
- Surgical
- Transcatheter



Other Issues with ASDs

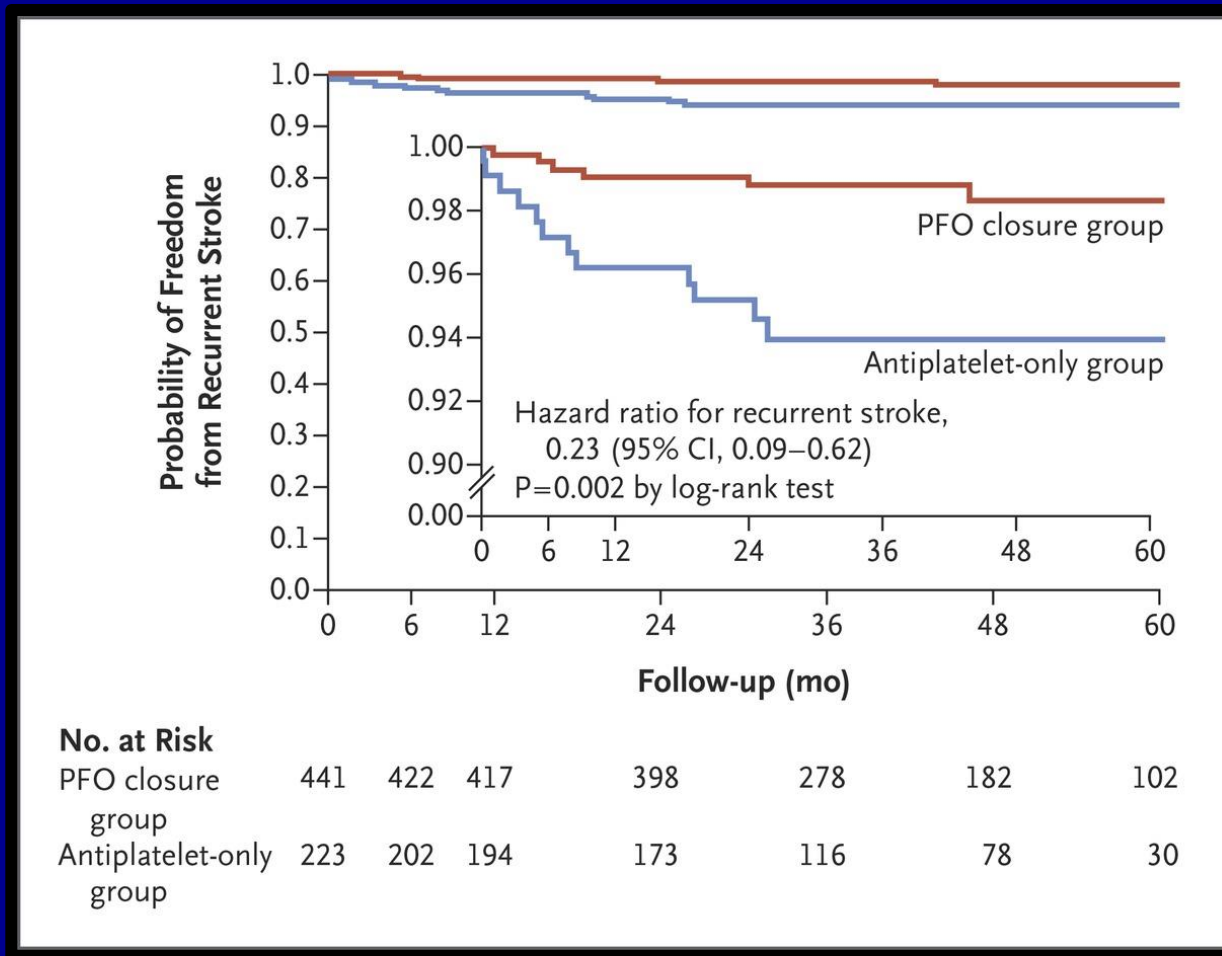
- Periodic follow up
- Arrhythmias (also with repaired)
- Pulmonary hypertension
- Scuba diving
- High altitude exposure

Patent Foramen Ovale



Geva et al. Lancet 2014

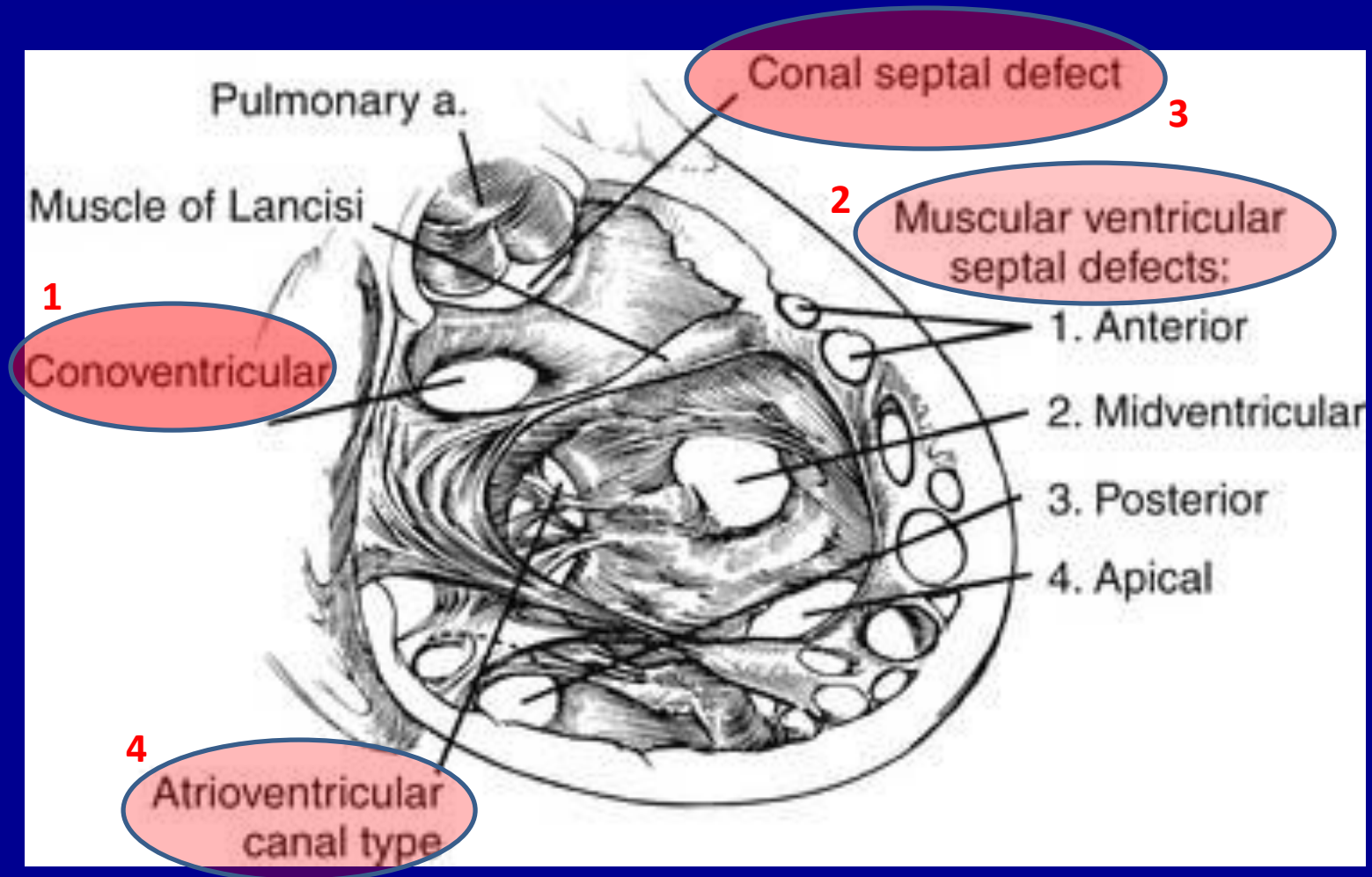
Patent Foramen Ovale



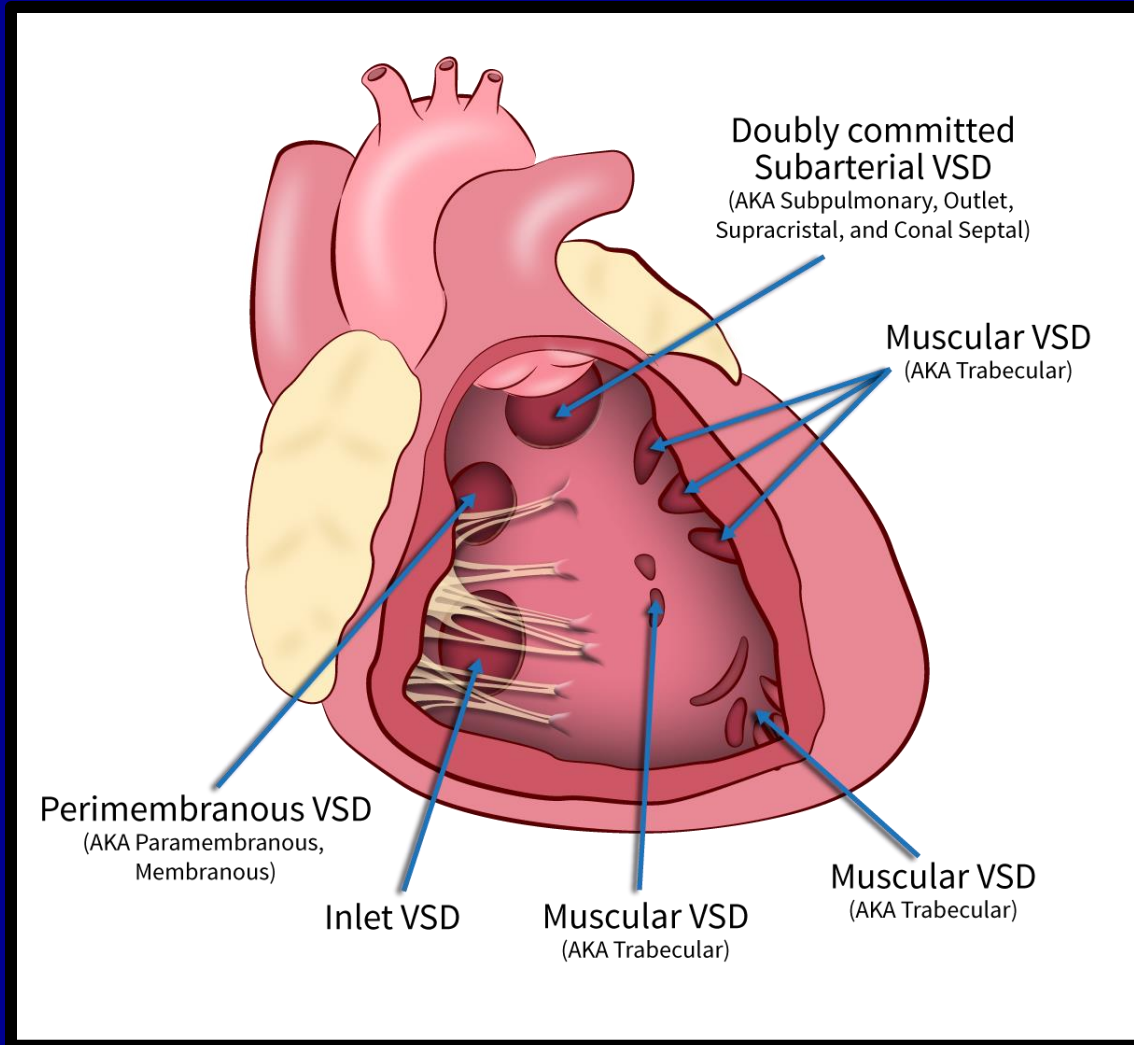
PFO - To close or not to close..

- Patient Factors
 - Hypercoagulable state
 - Atrial Fibrillation
 - ASCVD Risk Factors
 - Presence of devices in the RV
- PFO factors
 - Shunt size
 - Atrial Septal Aneurysm

Ventricular Septal Defect



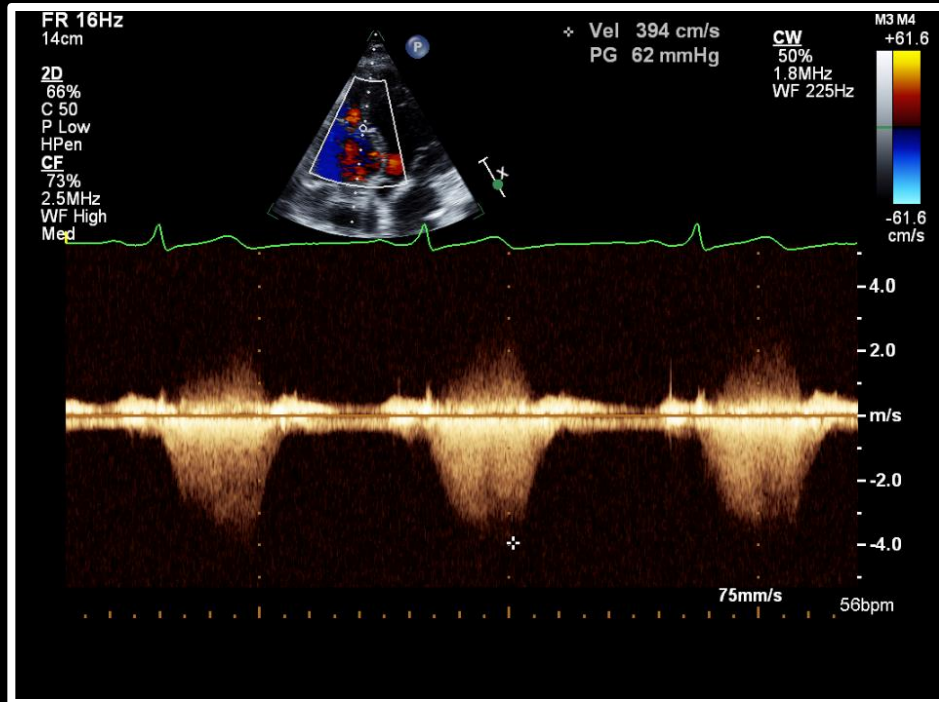
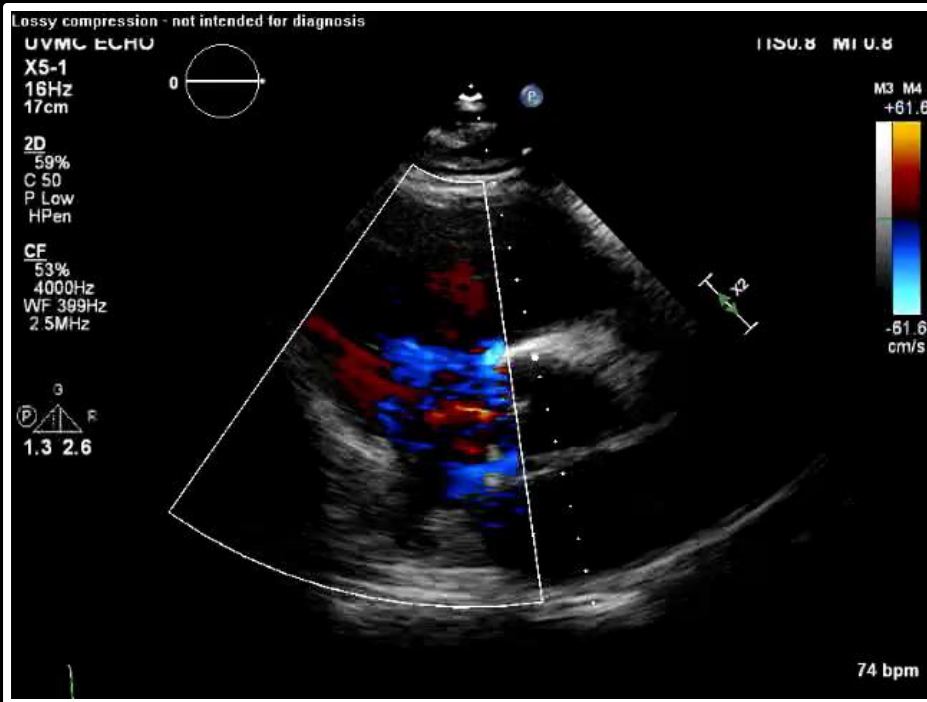
Ventricular Septal Defect



Physical Exam and EKG

- Smaller the VSD - louder the murmur
- Holosystolic plateau-shaped murmur at LLSB
- ECG
 - Normal
 - LAE and LVH

VSD



VSD Closure in Adults

- Intervention is rarely required
- Large VSDs with PH- ACHD Consult
- Small VSDs usually close spontaneously
- Small open VSD, no sign shunt
- Rare complications – AR and PR

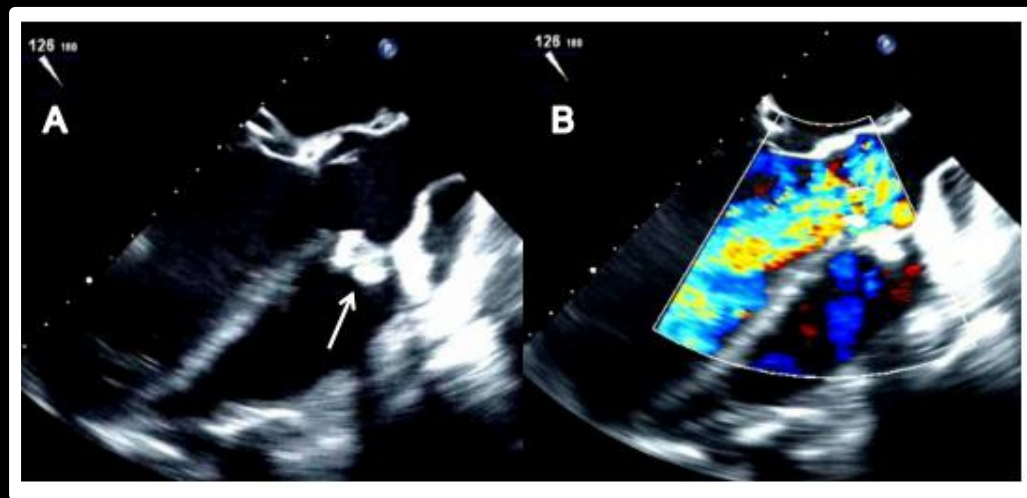
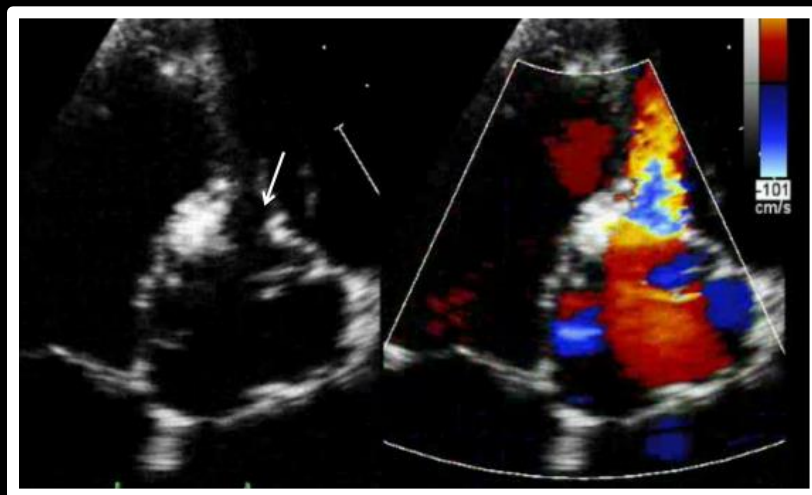
Indications for Closure of VSD

- Symptoms of heart failure
- Large LV
- Normal PVR

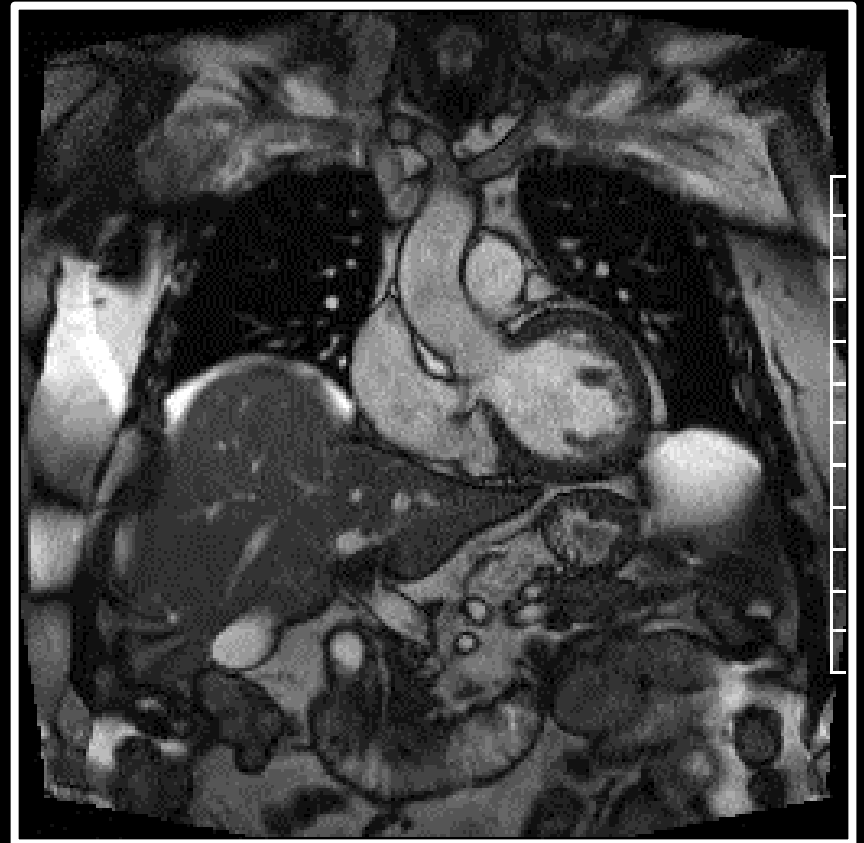
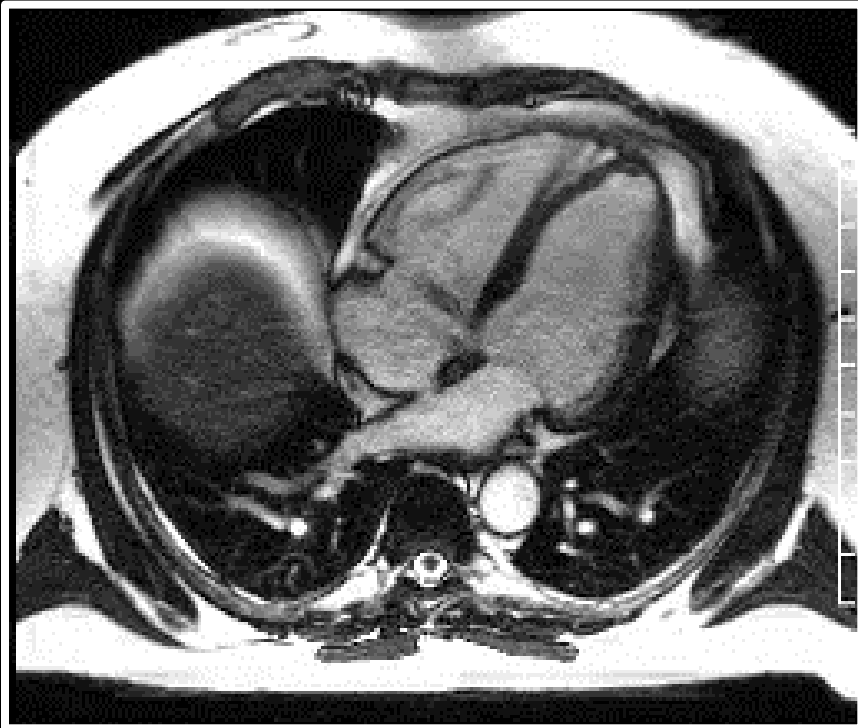
Lifelong Follow Up -VSD

- More often repair of the VSD
 - Endocarditis
 - Aortic insufficiency
 - Pulmonary insufficiency
- Surgical repair remains the gold standard
- Transcatheter closure is possible

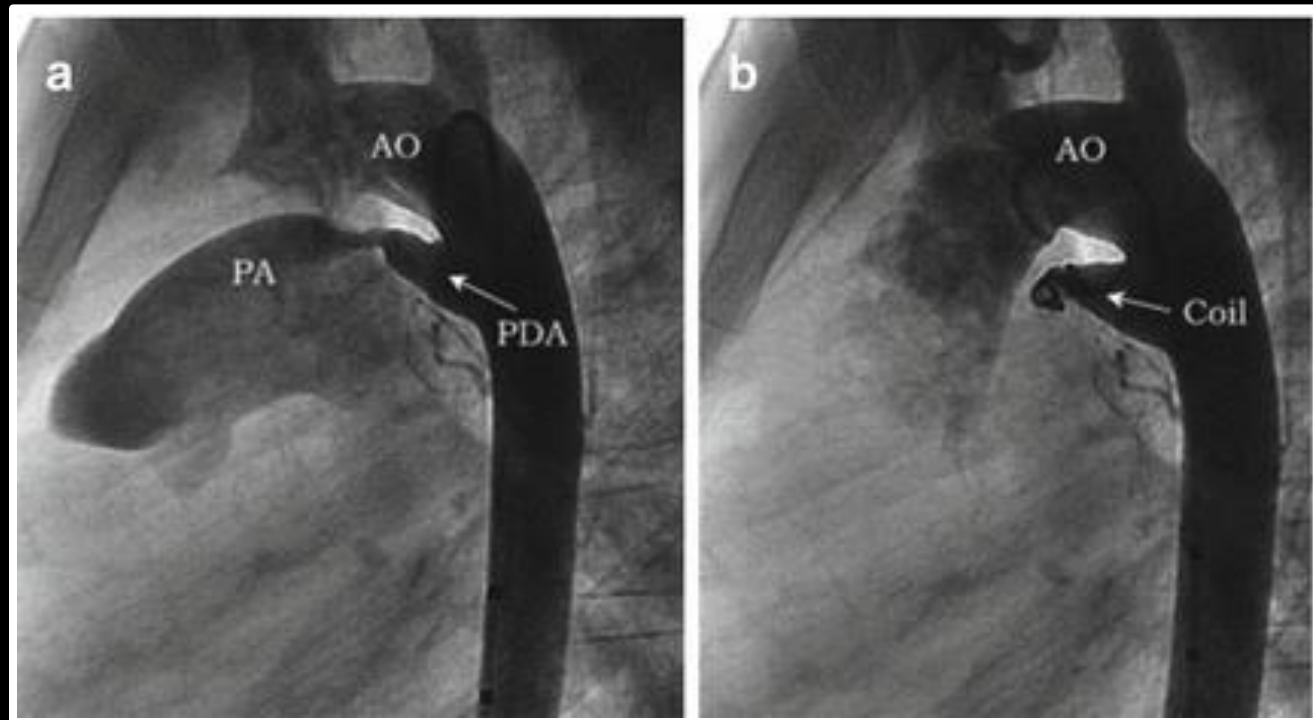
Supracristal VSD with Sev AR and IE



Gerbode Defect



Patent Ductus Arteriosus



Significant Left to Right
Shunt

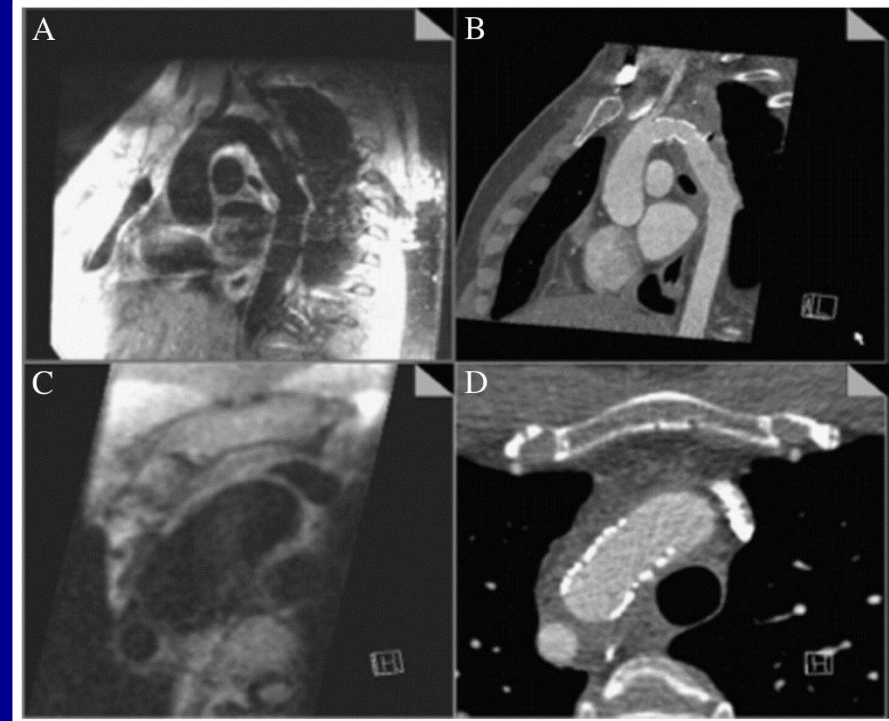
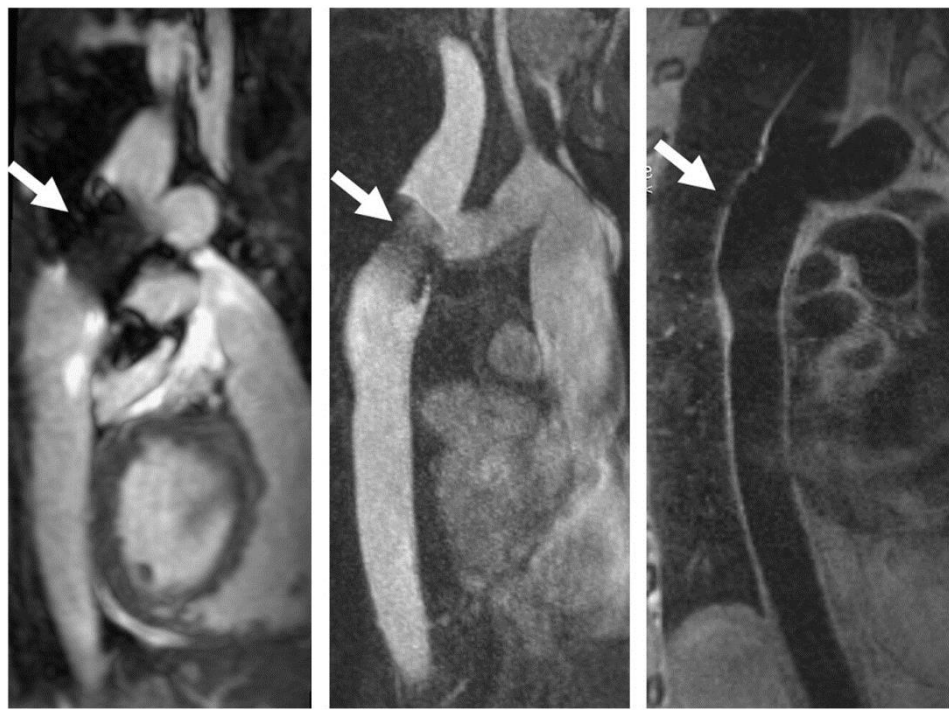
- Symptoms
- LA and LV enlargement

Endarteritis

Coarctation of Aorta

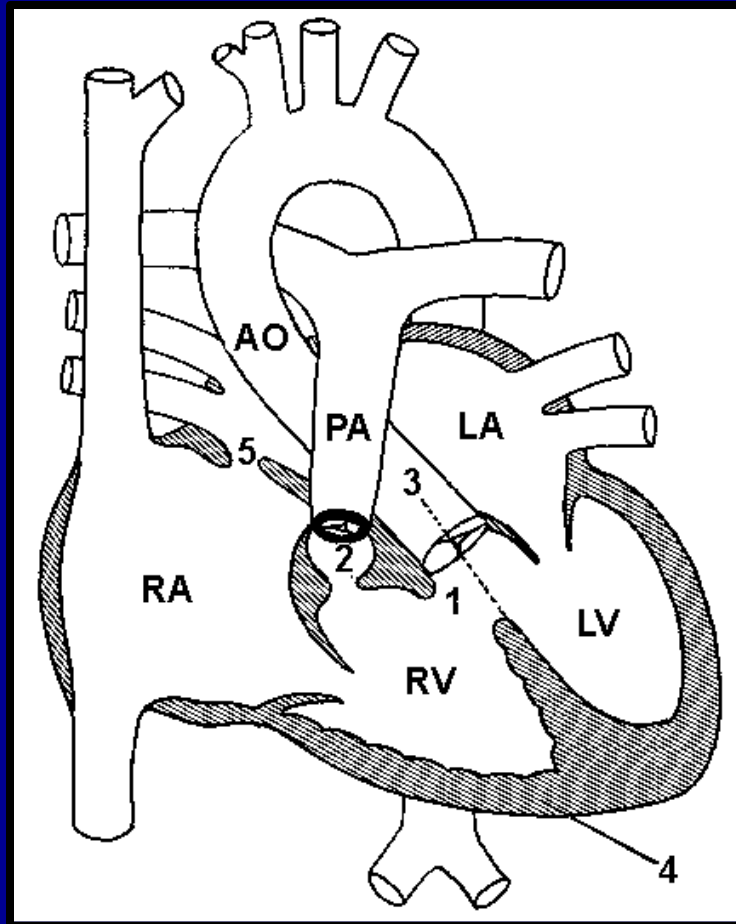
- Familial risk
- Turner syndrome
- Associated anomalies
 - ASD
 - VSD
 - Bicuspid aortic valve
- **Hypertension**
- Brachial-femoral delay
- Premature CAD, Stroke
- Intracranial aneurysms
- Surgery, Balloon Angioplasty, Stent

Coarctation of Aorta- 3D SPACE TSE

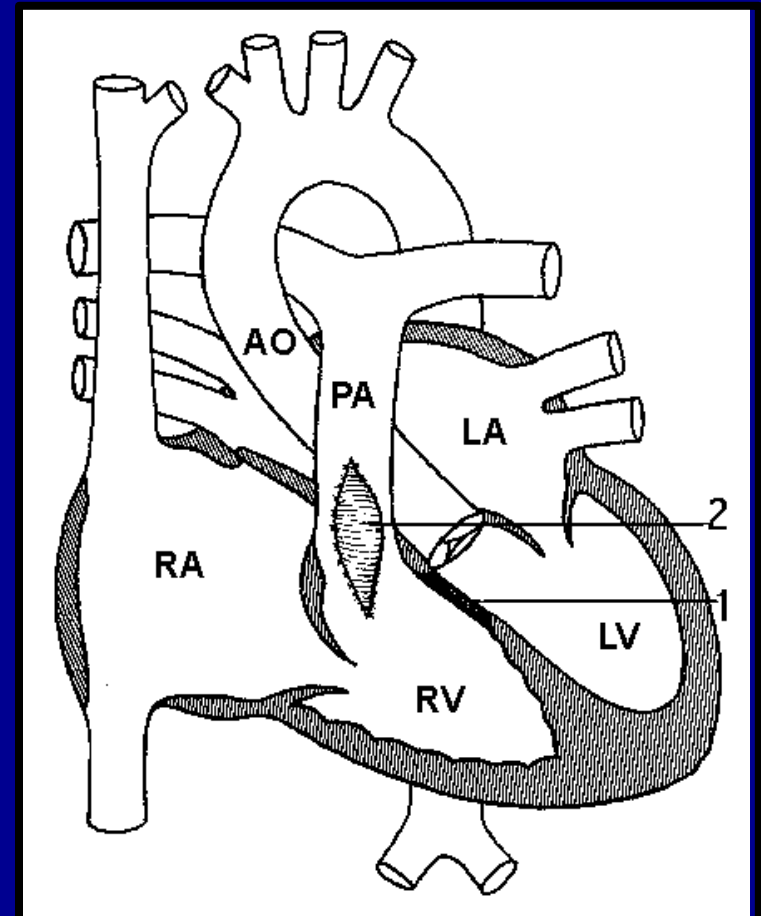


Tetralogy Of Fallot (TOF)

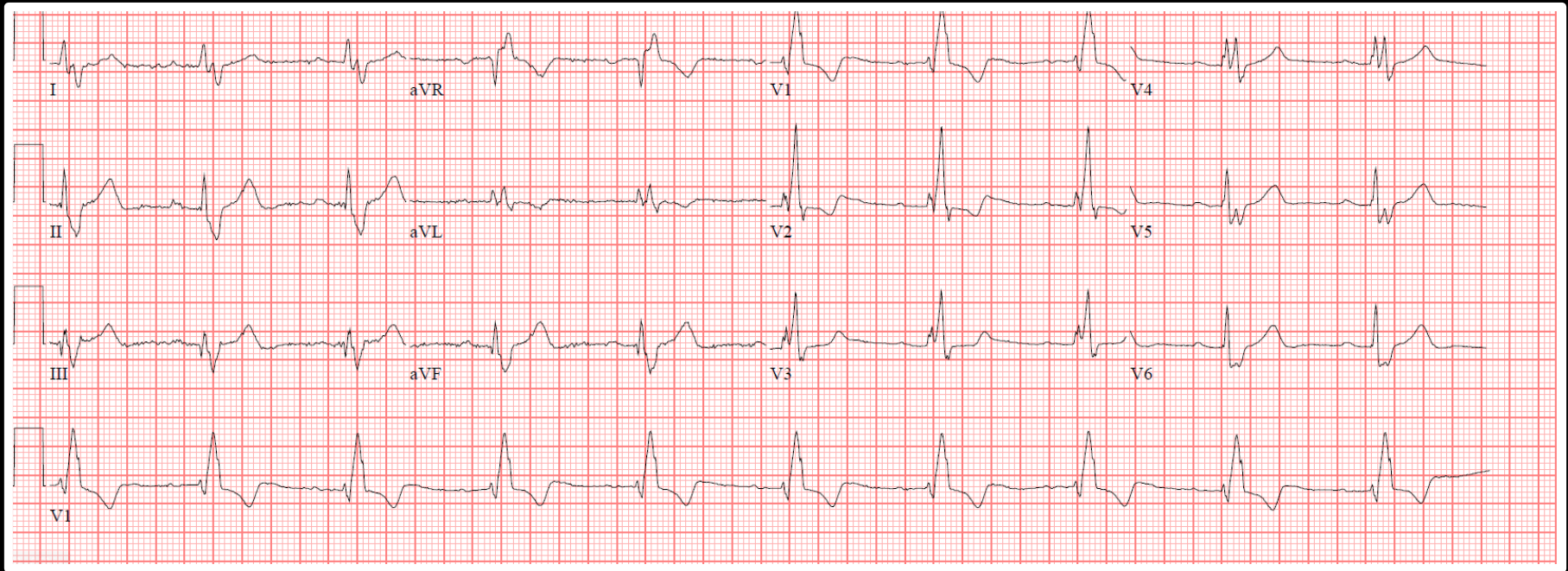
Unrepaired



Repaired



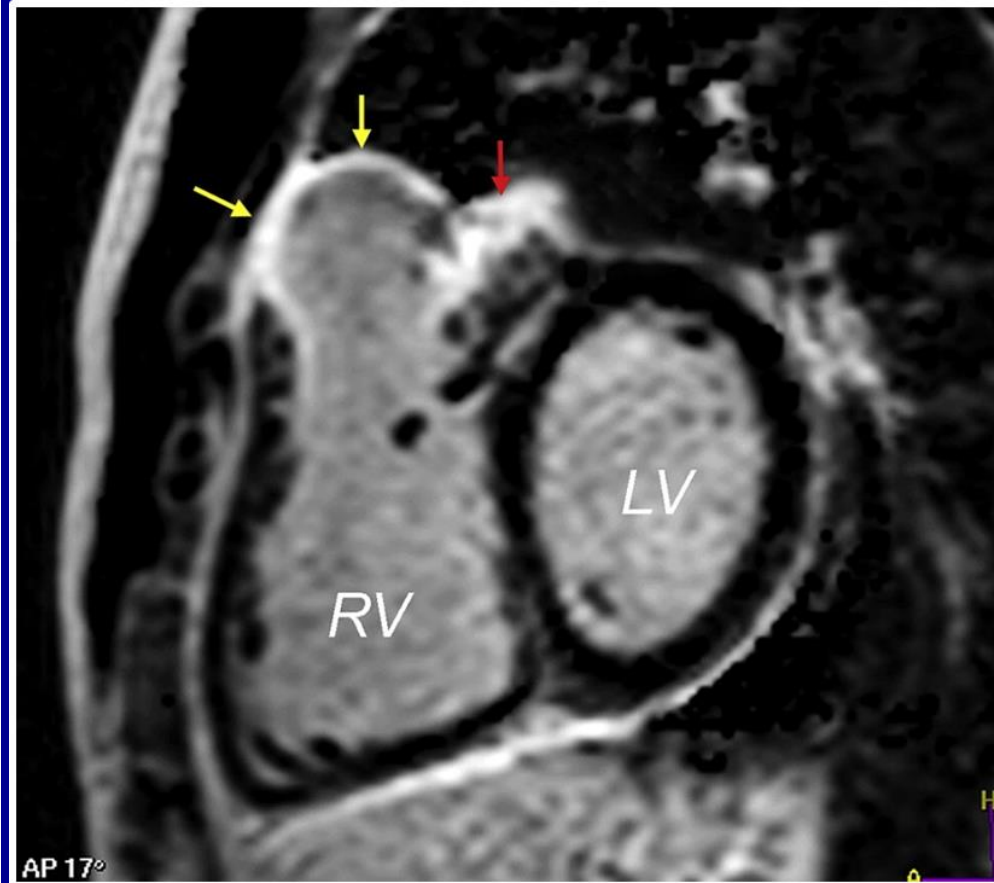
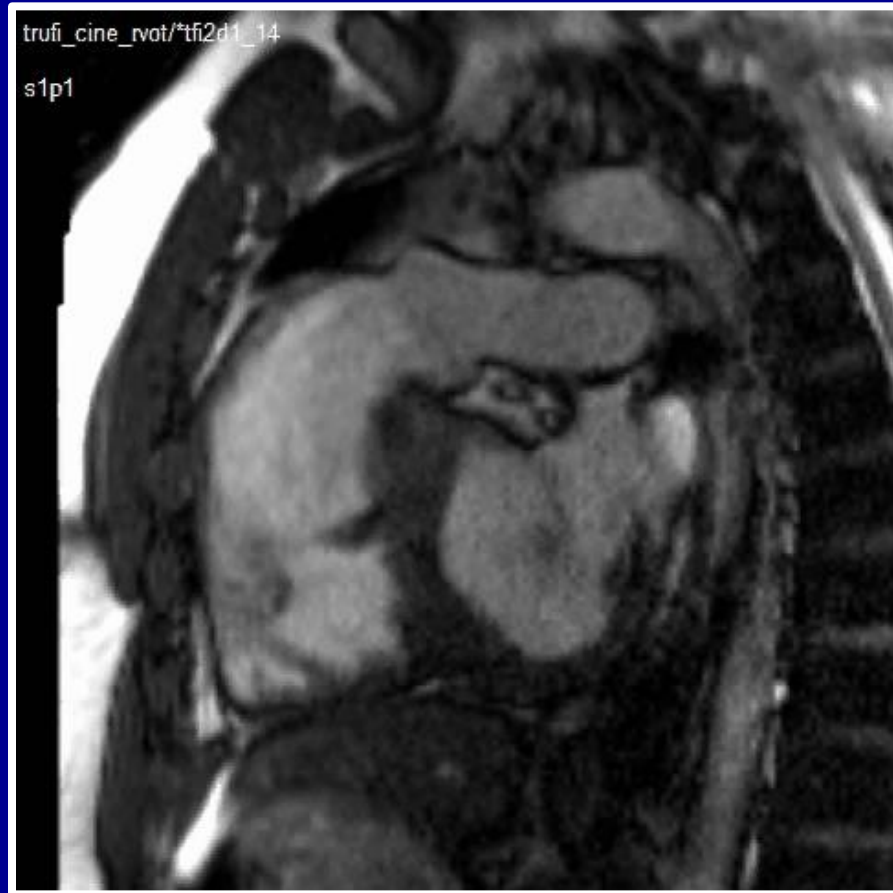EKG in Repaired TOF



Issues in Adults with Repaired TOF

- Pulmonary Regurgitation
- Atrial Arrhythmias
- Ventricular Arrhythmias
- Sudden Cardiac Death
- Residual VSD
- LV Dysfunction
- Right Heart Failure

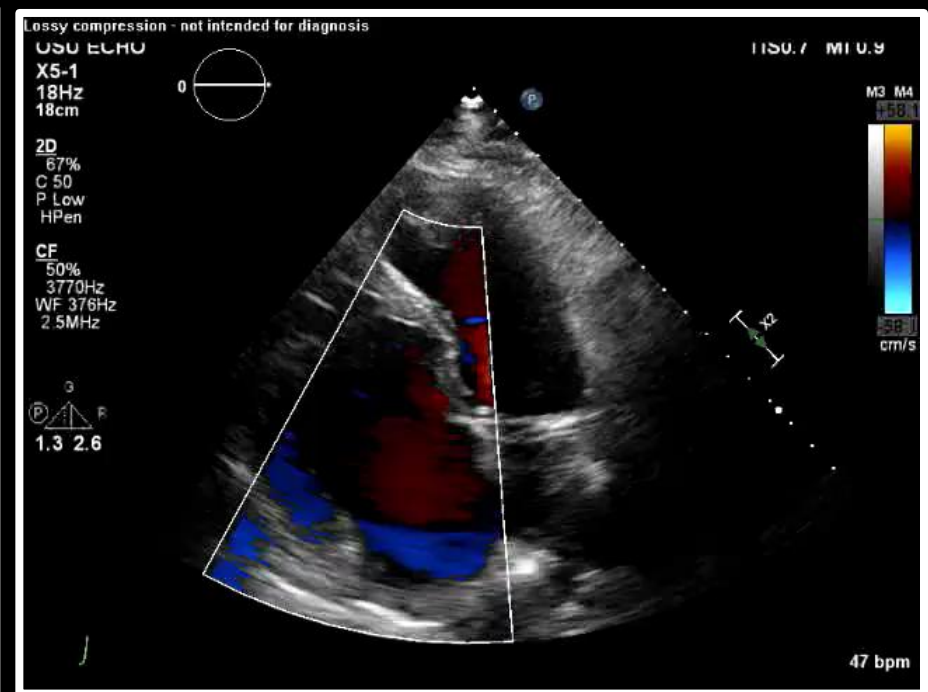
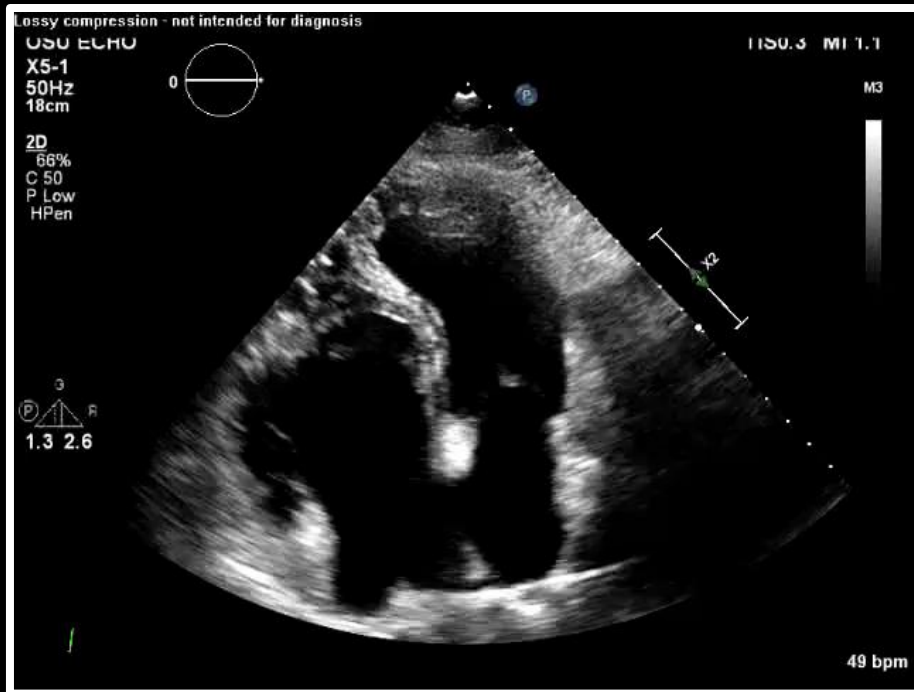
Tetralogy Of Fallot



Adults with Repaired TOF

- EP Procedures
- PVR - Transcatheter Vs Surgical
- Lifelong follow up with ACHD Clinic

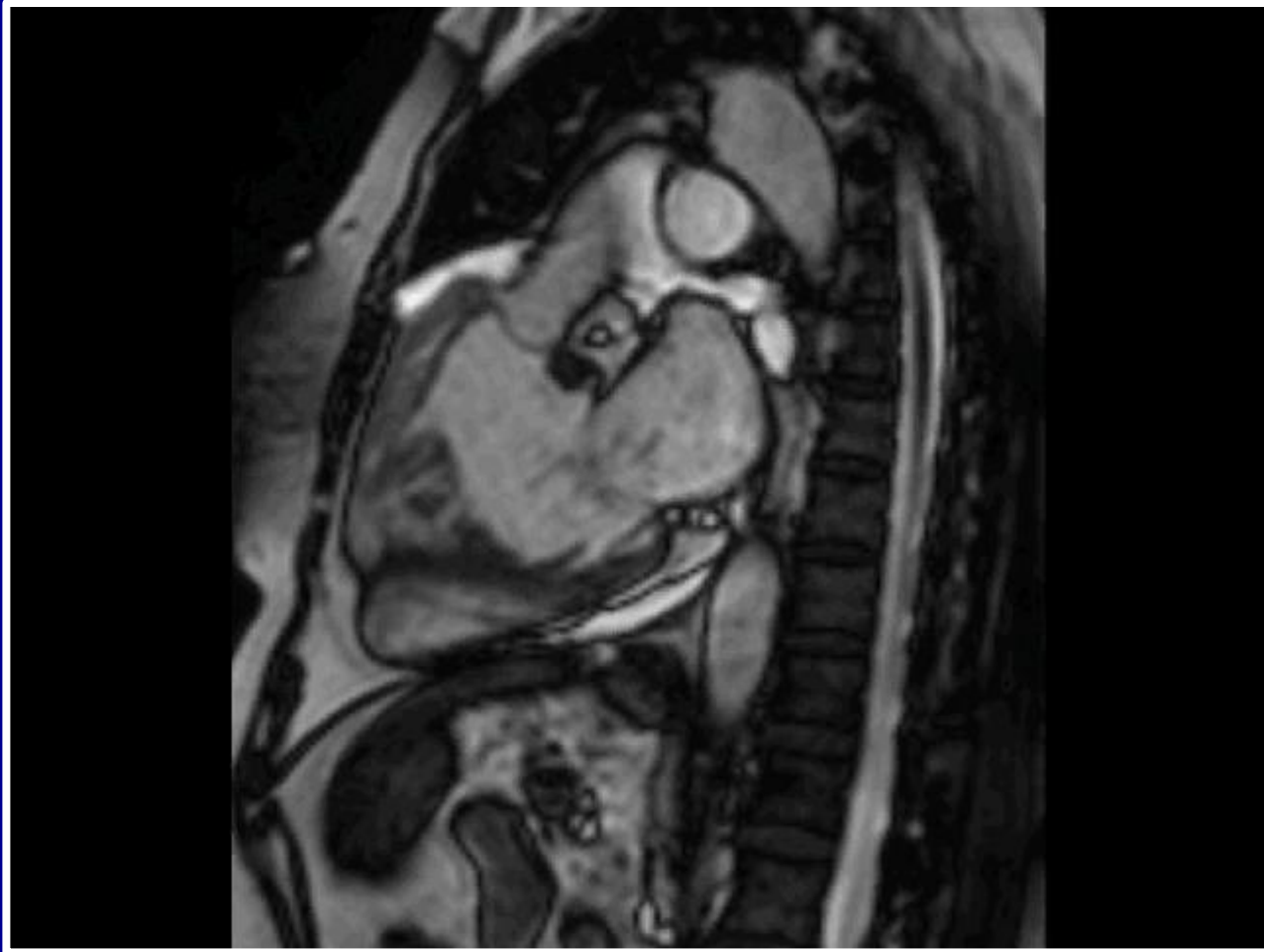
Ebstein Anomaly



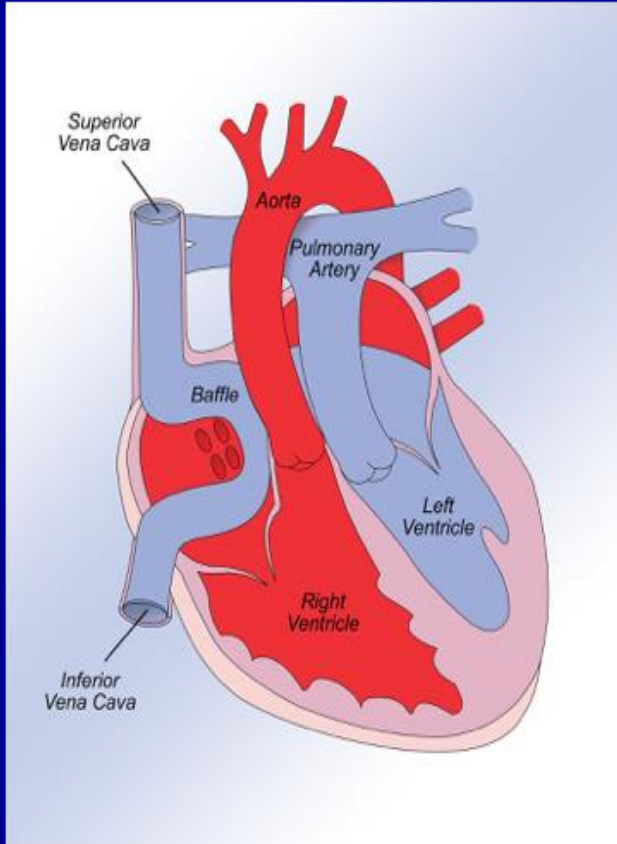
Ebstein Anomaly

- Tricuspid regurgitation
- RV Failure
- ASD - O2 desaturation
- Atrial Arrhythmias
- Surgery- TVR or Cone procedure

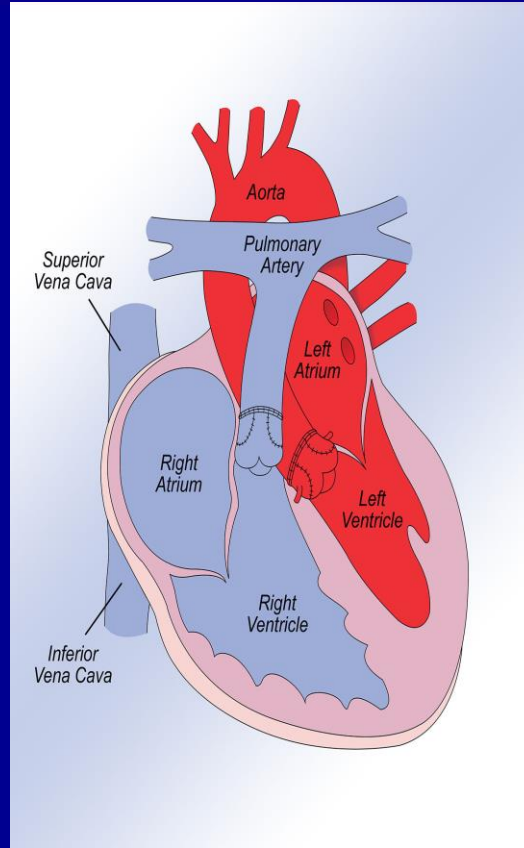
Transposition of Great Arteries



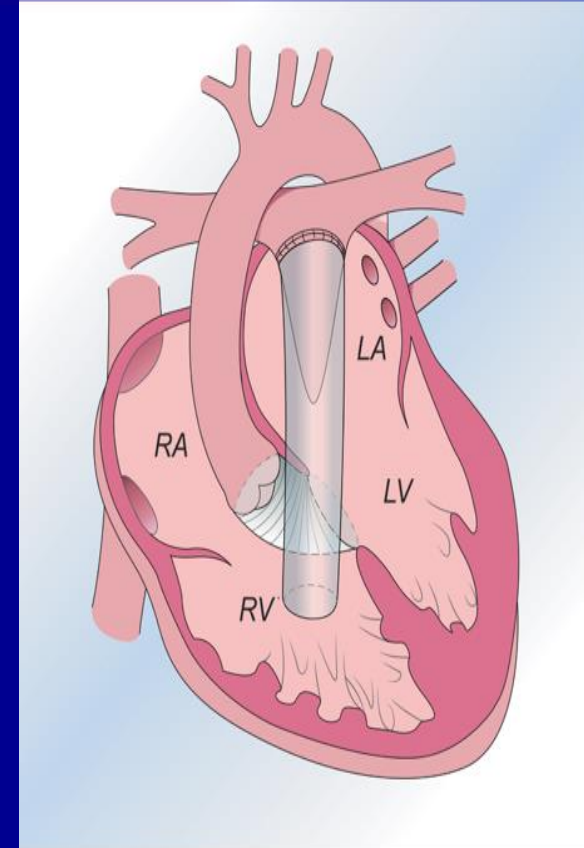
Surgical Repairs TGA



Atrial switch

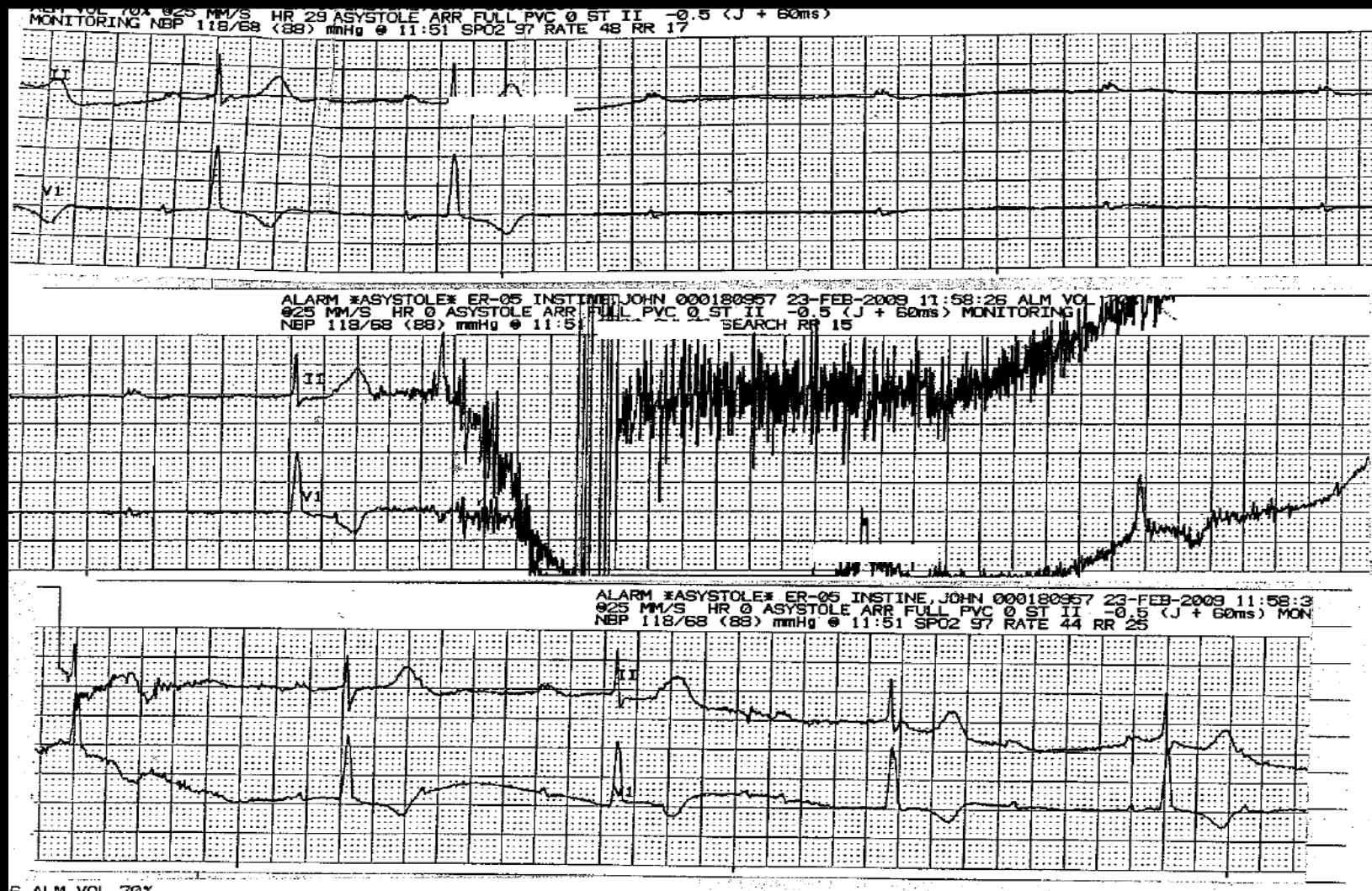


Arterial switch

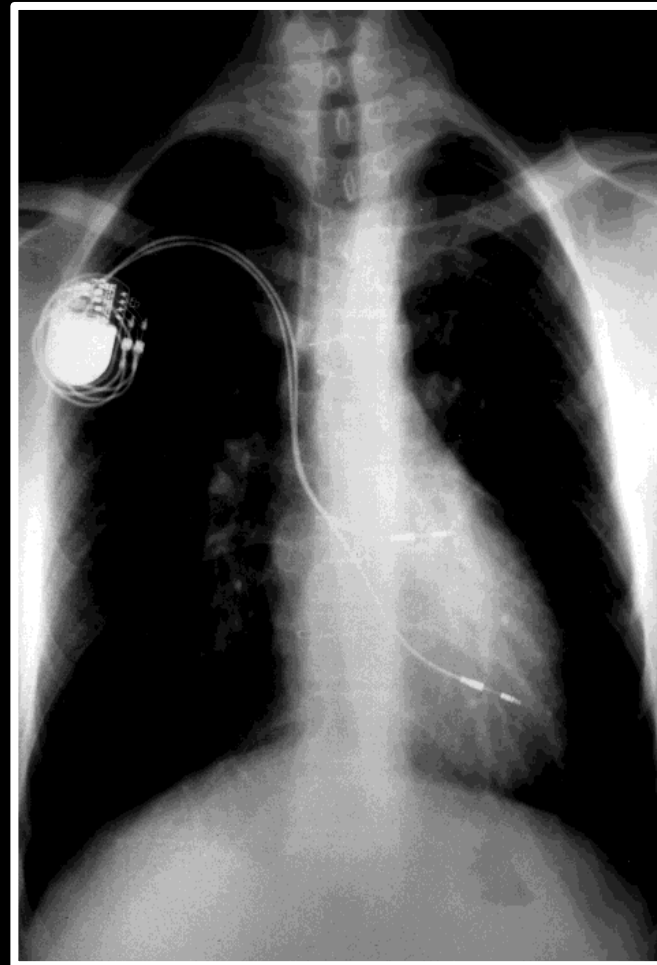
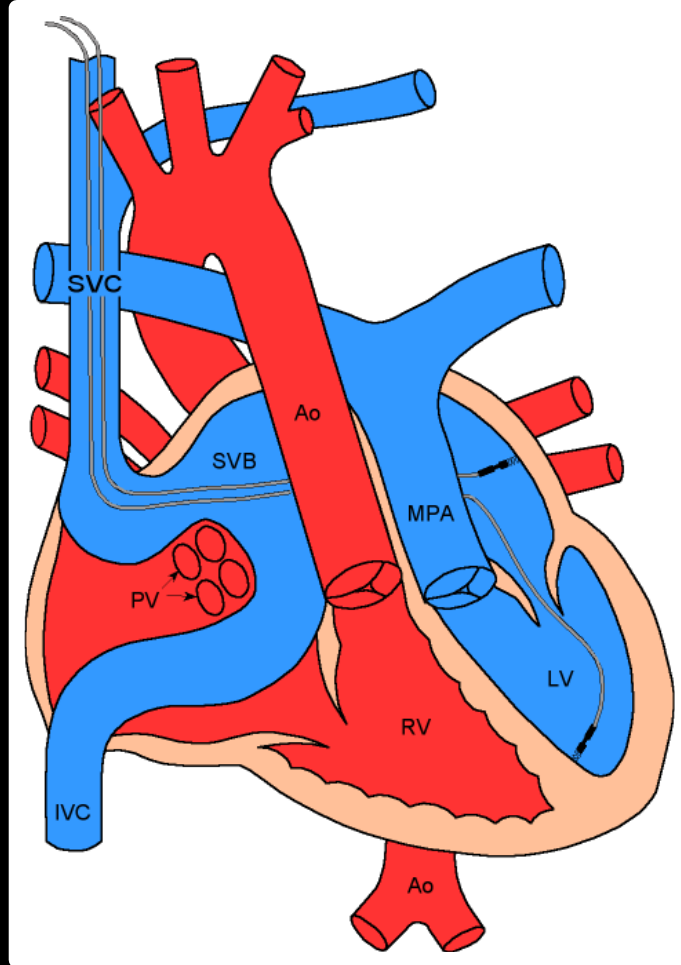


Rastelli procedure

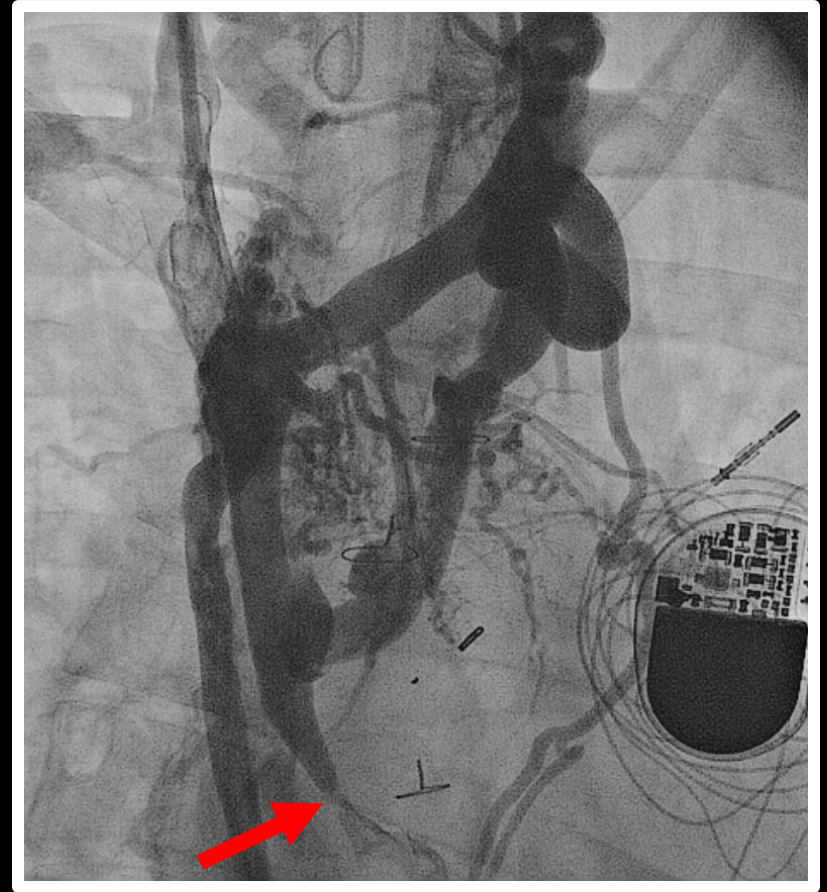
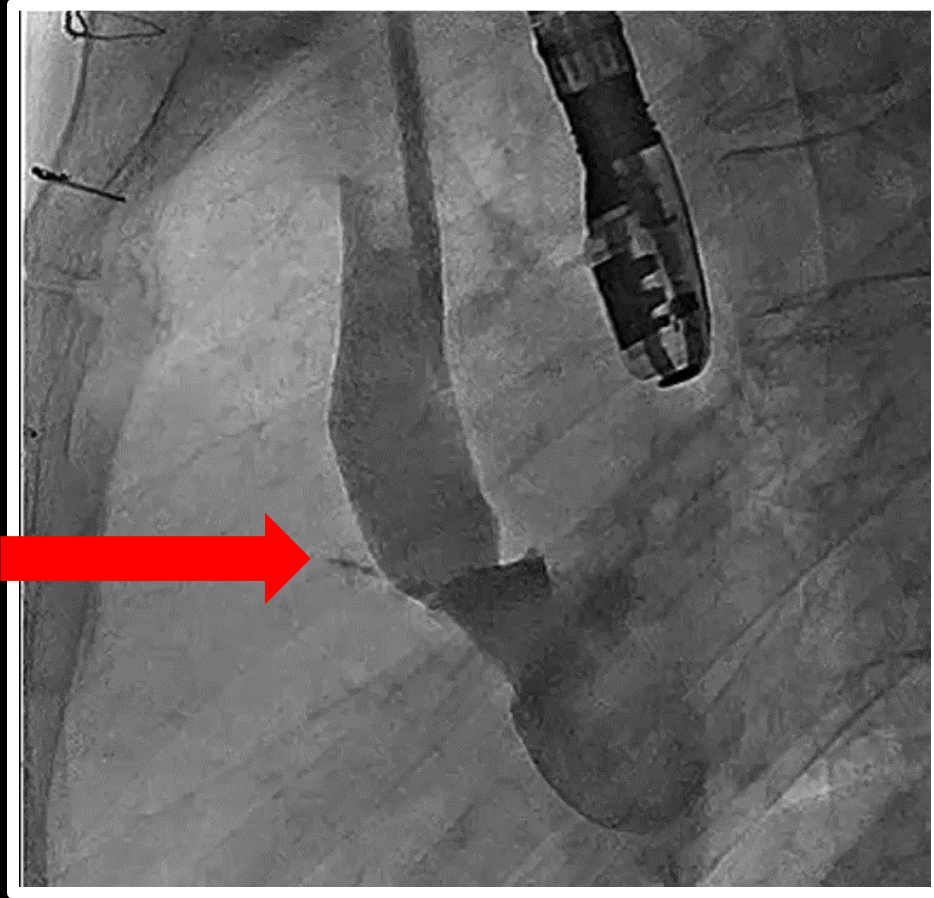
42 year old female with D-TGA s/p atrial switch w/syncope



D-TGA Atrial Switch



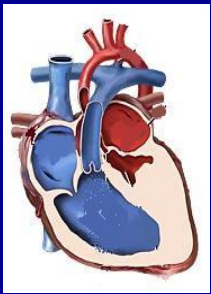
D-TGA Atrial Switch



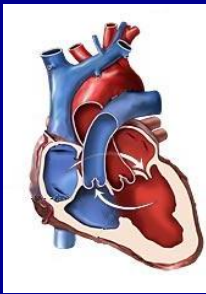
Complex Congenital Heart Disease

- Eisenmenger Syndrome
- Unrepaired Cyanotic Congenital Heart Disease
- Fontan and Single Ventricle
- Palliation- Systemic to PA Shunts

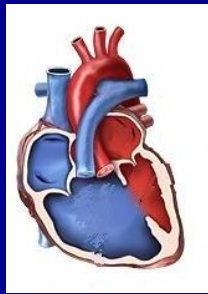Single Ventricle Anatomy



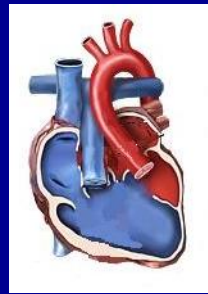
HLHS



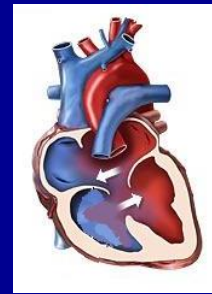
TA



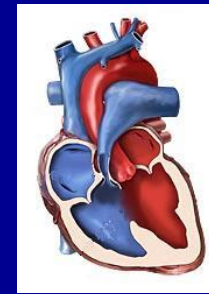
DORV



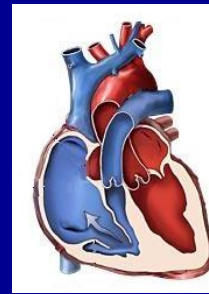
DILV



Unbalanced
AVC



PA

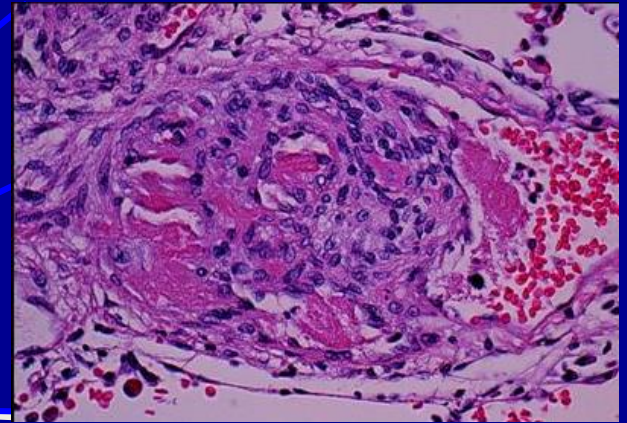
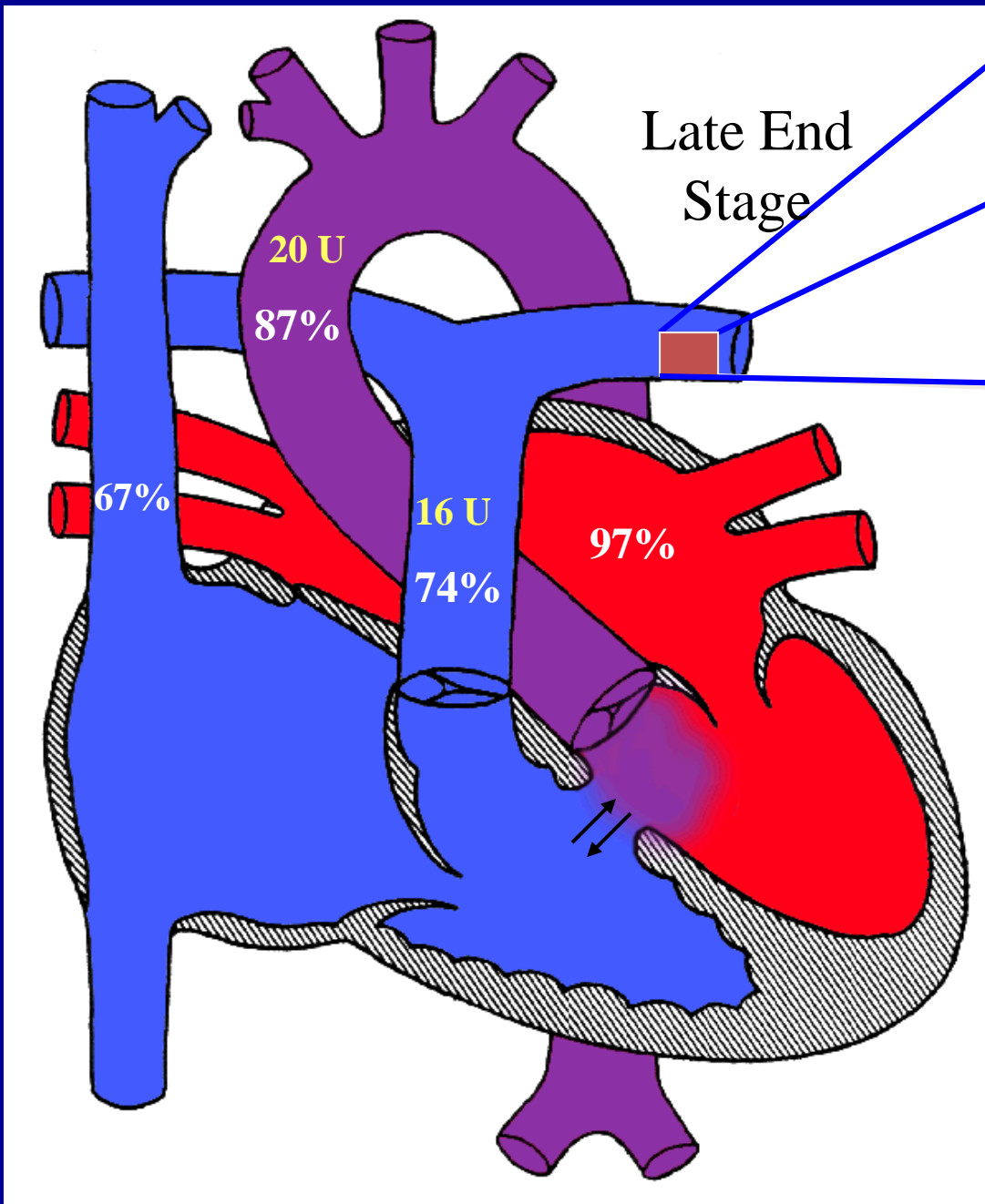


Ebstein



Surgical Shunts

- BT
- Central
- Waterston
- Potts



$$PVR \geq SVR$$

$$Q_p:Q_s = 0.9:1$$

Eisenmenger
Syndrome

Eisenmenger Syndrome

multiorgan system dysfunction

stroke

brain abscess

osteoarthropathy

iron deficiency

reduced glomerular clearance

susceptibility to acute renal insufficiency

pulmonary arterial thrombosis and dissection

hemoptysis, pulmonary parenchymal infections

diastolic and systolic cardiac dysfunction, arrhythmia, HF, and SCD

Complex Congenital Heart Disease

- Must have 6 mthly to yearly ACHD follow-up
- Know and check O2 saturation regularly
- Check iron stores periodically
- Monitor renal and liver function
- Most have restrictive or other lung disease
- Must have dental follow up
- High risk of stroke and brain abscess in cyanotic patients

ACHD Patients- Common Issues

- Quality of life
- Transition
- Birth Control
- Pregnancy and CHD
- Dental Issues
- Exercise
- Hep C

- Pulmonary Hypertension
- Heart Failure
- Arrhythmias
- Neurocognitive issues
- Advance care planning and advanced directives

Quality of life

- Quality of a person's life
 - related to how satisfied they are with their life
- Functional status
 - ability to do normal daily activities
- Disability paradox
- Response shift
- Sense of coherence

Quality of life – Adults with Congenital Heart Disease


 **Hopeful Hearts Foundation**
@Hopeful_Hearts Follow

Repost from [@shaunwhite](#) I was supposed to be a very inactive child after being born with a congenital heart defect, but I'm still here, still going.... life is what you make it! #chd



  shaunwhite

7:39 AM - 31 Jul 2018



Pregnancy

- High Risk
 - Aortopathies including Marfan syndrome
 - Severe left sided obstructive lesions
 - Fontan
 - Eisenmenger
 - Pulmonary Hypertension
 - Severe LV Dysfunction

Birth Control

- Hypercoagulable states
- Low dose progestin pills
- IUDs
- Complex congenital heart disease patients should be evaluated in tertiary centers

Exercise



SBE Prophylaxis

- Prosthetic heart valves
- Prosthetic material used for cardiac valve repair
- Prior history of IE
- Unrepaired cyanotic congenital heart disease
- Repaired congenital heart disease with residual shunts or valvular regurgitation at the site or adjacent to the site of the prosthetic patch or prosthetic device
- Repaired congenital heart defects with catheter-based intervention involving an occlusion device or stent during the first six months after the procedure
- Valve regurgitation due to a structurally abnormal valve in a transplanted heart

Advance Care Planning and Advance Directives

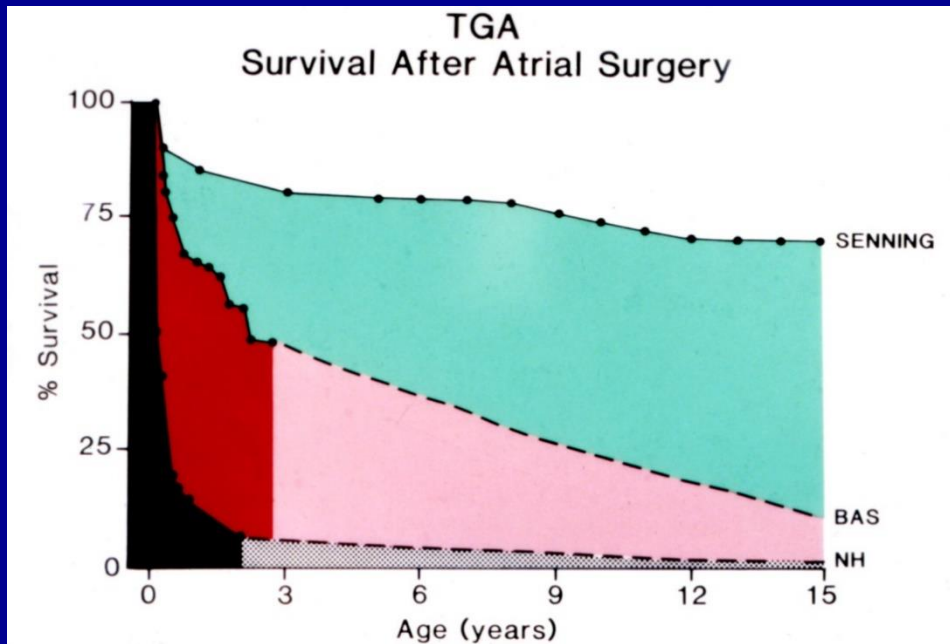
The place for these difficult conversations should **not** be in the Intensive Care Unit (ICU)

- 50% of ACHD patients die in the hospital
- Of these, two-thirds die in the intensive care setting and almost a half were on life support
- Only 10% of patients in ACHD care had an end-of-life discussion

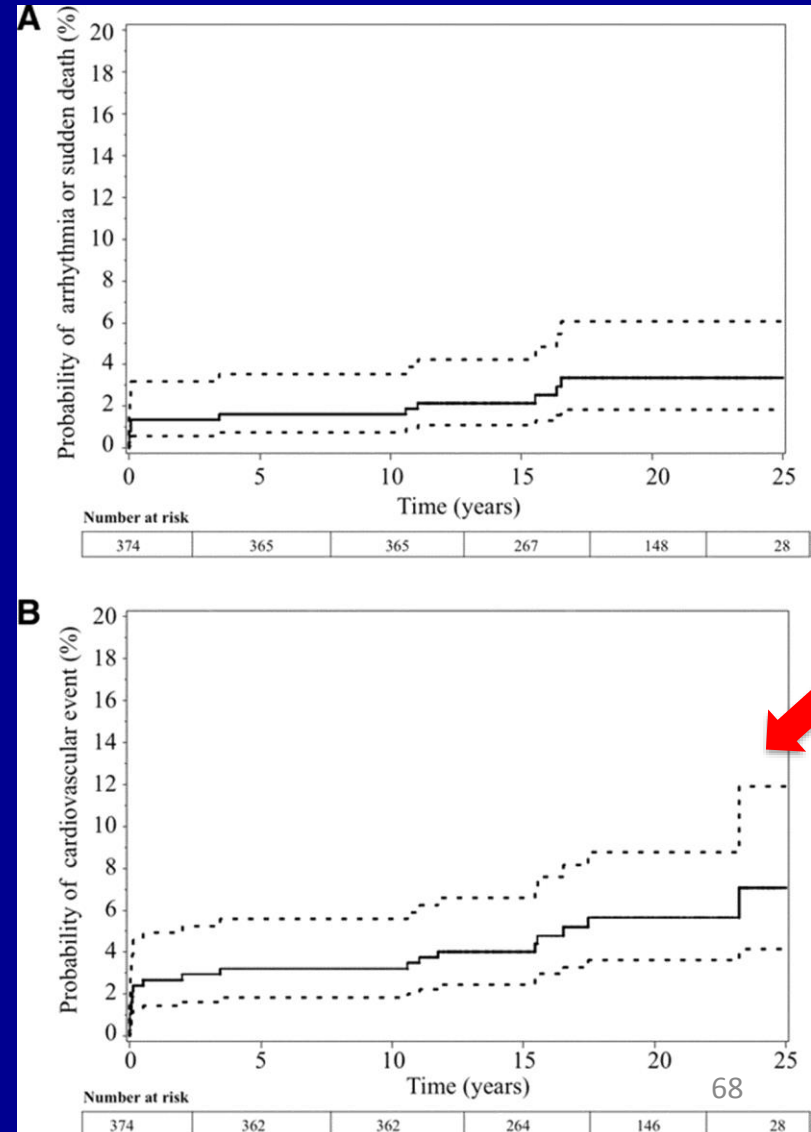
Current Concerns Neurodevelopmental Outcomes

- 60 young adults with arterial switch operation
- Re-evaluated (mean age 16.9 ± 1.7 y)
- Neurologic impairment in 10%
- Periventricular leukomalacia
 - >50%
 - severity correlated with neurologic impairment
- MRI Struc Abn: 32%

Congenital Heart Disease – The Journey



Courtesy: Peter Lang, MD



Adults with Congenital Heart Disease

Games

Hyper Light Drifter - how heart disease inspired one of 2016's great games

The central character in this brilliant new game is haunted by a deadly illness - something with which creator Alex Preston is all-too familiar

Chris Priestman

Thu 2 Jun 2016 06:14 EDT

The Guardian US edition v



▲ Hyper Light Drifter. Photograph: Heart Machine

New Guidelines

2018 AHA/ACC Guideline for the Management of Adults With Congenital Heart Disease

**A Report of the American College of Cardiology/American Heart Association Task Force on
Clinical Practice Guidelines**

*Developed in Collaboration With the American Association for Thoracic Surgery, American Society of
Echocardiography, Heart Rhythm Society, International Society for Adult Congenital Heart Disease,
Society for Cardiovascular Angiography and Interventions, and Society of Thoracic Surgeons*

JACC 2018

COACH

Columbus Ohio Adult Congenital Heart Program



Thank you

- Thank you